

# Rectus abdominis endometriosis

## *A descriptive analysis of 10 cases concerning this rare occurrence*

Hussien A. Mostafa, MD, Jamel H. Saad, MD, Zafer Nadeem, MD, Fawaz Alharbi, MD.

### ABSTRACT

**الأهداف:** دراسة 10 حالات مصابة بورم انتباز بطني رحمي شرجي وتسلط الضوء على النتائج المخبرية، والنسجية، والعلاج الجراحي المستخدم.

**الطريقة:** أجريت دراسة وصفية على 10 حالات مصابة بورم انتباز بطني رحمي شرجي خلال 5 سنوات من تاريخ 2007م حتى 2012م في مستشفى جامعة سوهاج، سوهاج، مصر ومستشفى القوات المسلحة بنجران، نجران، المملكة العربية السعودية. أجري تخطيط الصدى والتصوير المقطعي على بعض الحالات. كان الاستئصال الجراحي هو الحل العلاجي المتبع لجميع المرضى.

**النتائج:** اشتملت الدراسة على 10 مريضات مصابات بمعدل عمر 33.9 عام. أجريت عملية قيصرية لعدد 9 حالات بينما أجري منظار البطن ثم عملية فتح للبطن للكيس المبيض. ظهرت آلام البطن لدى جميع المرضى و كان هنالك ورم مجسوس لدى 3 مريض. تم اكتشاف 10 أورام في عضلة الانتباز البطني الشرجي ولم يتم تشخيص ورم في مريضة مصابة بورمين مصاحبين تم اكتشافها بالأشعة المقطعية. تم استخدام إبرة رفيعة لأخذ عينات بعد العملية في 2 مريض. كما أجري استئصال جراحي لجميع الحالات. وكان التشريح المرضي مؤكد في كل حالة. كما أنه لم يتم تسجيل أي مضاعفات أو انتكاسة خلال فترة المراجعة (6 إلى 24 شهر، معدل 13.2 شهر).

**خاتمة:** من خلال دراستنا أتضح لدينا أن هذا المرض ليس نادراً كما كنا نظن مسبقاً يجب علينا أن ندرجه في تشخيص أورام غشاء المعدة في الإناث في سن الإنجاب.

**Objectives:** To report 10 cases of rectus abdominis endometrioma, emphasizing the clinical presentations, imaging investigations, cytohistological findings, and surgical treatment employed.

**Methods:** This is a descriptive analysis of 10 surgically-proven cases of rectus abdominis muscle endometriosis, seen over a 5-year period from 2007 to 2012 at Sohag University Hospital, Sohag, Egypt and Najran Armed

Forces Hospital, Najran, Saudi Arabia. All patients had undergone ultrasonography. Computerized tomography (CT) and magnetic resonance imaging (MRI) were performed in some cases. Surgical excision was the way of treatment in all patients.

**Results:** This study was carried out in 10 women with a mean age of 33.9 years. Nine cases had previous history of cesarean section (CS) while one patient had laparoscopy converted to laparotomy for ovarian cyst. All patients were presented with abdominal pain but only 3 had a palpable mass. Ten lesions within the rectus abdominis muscle were detected with automated ultrasound and MRI depicted one lesion, which was missed by ultrasound in a patient who had 2 concomitant lesions. Preoperative fine needle aspiration (FNA) was carried out in 2 patients. Wide surgical excision was performed in all cases. Histopathology was confirmatory in each instance. No complications or recurrence were recorded on follow-up (6-24 months; mean 13.2 months).

**Conclusion:** This disease is not as rare as previously thought, and should be included in the differential diagnosis of abdominal wall masses in reproductive-age females.

*Saudi Med J 2013; Vol. 34 (10): 1035-1042*

*From the General Surgery Department (Mostafa), Radiology Department (Saad), Histopathology Department (Nadeem), and the Internal Medicine Department (Alharbi), Armed Forces Hospital, Najran, Kingdom of Saudi Arabia.*

*Received 13th May 2013. Accepted 25th August 2013.*

*Address correspondence and reprint request to: Dr. Jamel H. Saad, Radiology Department, Armed Forces Hospital, Najran, Kingdom of Saudi Arabia. Tel. +966 509213079. Fax. +966 (7) 52224444 Ext. 22201. E-mail: jamalamin2003@yahoo.com*

**Disclosure.** Authors have no conflict of interests, and the work was not supported or funded by any drug company.

Endometriosis is defined as the presence of endometrial tissue outside uterine cavity, most commonly surrounding the ovaries and fallopian tubes.<sup>1,2</sup> It is a known gynecological disease that affects as many as 0.5-5% of fertile women and 25-40% of infertile women,<sup>1</sup> and is considered as one of the most important causes of chronic pelvic pain and infertility.<sup>3</sup> Extra pelvic location is reported in many literatures. Abdominal wall endometriosis is one such location and is defined as endometrial tissue affecting anterior abdominal wall until peritoneum.<sup>4</sup> The actual incidence of abdominal wall endometriosis is unknown, and the prevalence of surgically proven endometriosis in scars was up to 1.6%.<sup>5</sup> Rectus abdominis muscle endometriosis is exclusively involvement of the rectus muscle by endometrial tissue. This is a very rare occurrence that is frequently missed and it is often mistaken both clinically and with diagnostic imaging for other abnormal conditions.<sup>6</sup> The aim of this study is to report our experience in 10 cases of rectus abdominis endometrioma, emphasizing the clinical presentations, imaging investigations, cytohistological findings, and surgical treatment employed.

**Methods.** From July 2007 until June 2012, all patients at Sohag University Hospital, Egypt and Armed Forces Hospital Najran, Saudi Arabia histopathologically diagnosed endometriosis strictly confined to rectus abdominis muscle were included in the study. Cases in which the skin, subcutaneous tissue, peritoneum or pelvic endometriosis were excluded from the study. A descriptive analysis of all cases was carried out as regards to history, clinical examinations, investigations, and management employed.

The medical records of patients diagnosed with this entity were reviewed after institutional review board approval. The main information surveyed was age, obstetric history, symptoms, duration of complaint, mass location, size, diagnosis, treatment, and recurrence. Sonographic examination was performed in all patients using 3.5 MHz and 5.0 MHz convex-array and 7.5 MHz and 12-15 MHz linear-array transducers (Antares, Siemens Medical Solutions and E9 General electric medical system, GE). Power Doppler sonography was used to assess the vascularity of all lesions.

In addition to sonography, computerized tomography (CT) and magnetic resonance imaging (MRI) were performed in some cases. Computerized tomography examination with intravenous (IV) contrast material was performed on a multi-detector CT (MDCT) 64 slices scanner (Lightspeed, GE) and MRI on a 1.5-T scanner (GE); MRI sequences

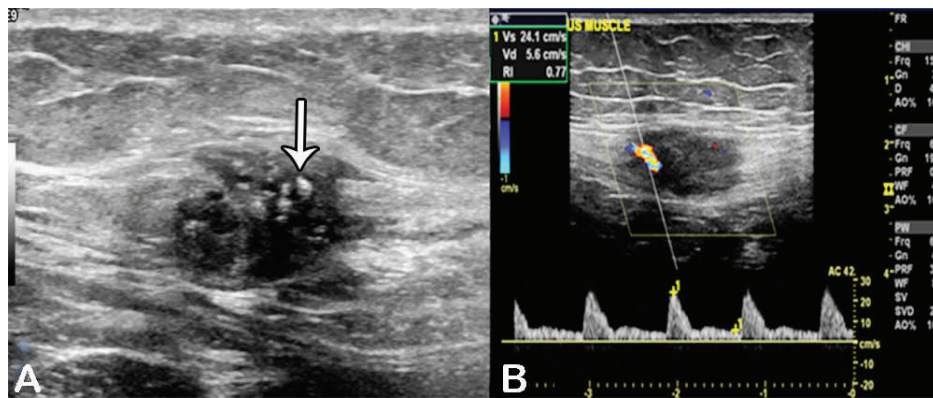
included spin-echo T1-, fast spin-echo fat-saturated T2-, short time inversion-recovery (STIR) sequence and fast spin-echo fat-saturated gadolinium-enhanced T1-weighted sequences. Pathological material was obtained pre-operatively by fine-needle aspiration (FNA) and peroperatively by crush smear. Wide surgical excision with safety margin and reinforcement with polypropylene mesh, if necessary was the treatment of choice in all cases. Histopathological confirmation of endometriosis was the definite way of diagnosis. All patients were followed-up for post-operative complications or recurrence of the disease.

**Results.** All cases are reported in Table 1 including their history, clinical presentations, radiological explorations and surgical treatment. All patients were in the reproductive period with age groups ranging from 16-46 (mean 33.9 years). All except for one were fertile with parity ranging from 3-8 deliveries. One patient had primary infertility, bicornuate uterus, and ovarian cyst. She developed endometrioma in the rectus muscle one year after laparoscopy that was converted to laparotomy. A history of cesarean section (CS) was forthcoming in 9 cases and one patient had concomitant tubal ligation at the time of CS. All our patients presented with moderate to severe lower abdominal pain which was cyclic associated with menses in 3 cases (30%) and non-cyclic in the remaining 7 cases (70%). A palpable tender abdominal wall mass was noted only in 3 patients (30%). The interval between CS and appearance of symptoms ranged from 6 months to 6 years. Sonography depicted the lesion in all patients, except in one who had 2 endometriomas located within the right rectus abdominis muscle and only the lesion close to the midline was depicted and one missing lateral. The size of the lesions ranged from 15-52 mm with a mean of 28 mm. All masses were hypo-echoic and heterogeneous with scattered internal echoes (Figure 1a). Ten masses were completely solid on sonography, whereas one lesion also contained some cystic changes with echoic sediment. Internal vascularity was noted in all cases with resistance indices varying from 0.70 to 0.77. The vascularity was peripheral and minimal for 3 lesions with a size <2 cm and was prominent, central, and peripheral for the other 8 lesions which had sizes superior to 2cm (Figure 1b). Computerized tomography examination was performed in 6 patients to evaluate the extent of the mass in the abdominal wall. All lesions appeared as solid, ill-defined, isodense nodular thickening of the rectus abdominis muscle, with slight enhancement after contrast injection (Figure 2a & 2b). The MRI was performed in 4 patients to further establish the nature and extent of lesions. The

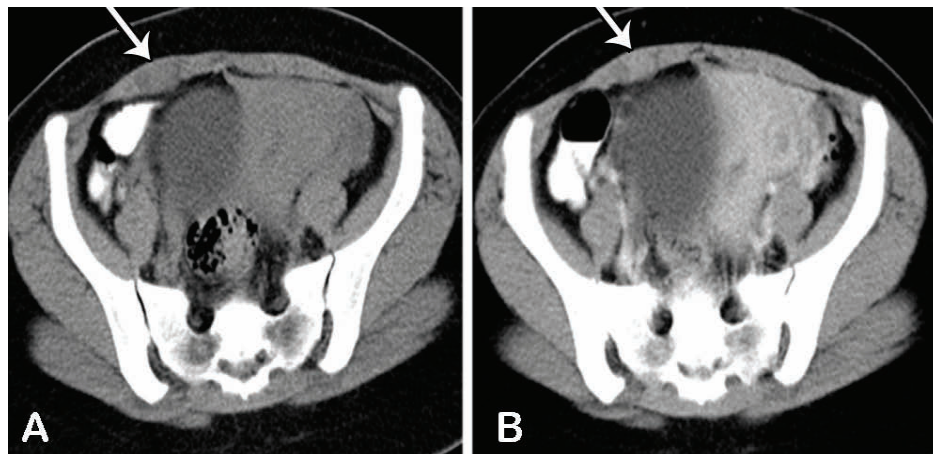
**Table 1** - Analysis of 10 cases of rectus abdominis endometriosis.

No.	Age (years)	Ethnicity	Parity	Surgical history	Symptoms	Image	Size (cm) by U/S	Treatment
1	46	Romania	Para 6	3 CS + Tubal ligation	Pain+ swelling	U/S-CT-MRI	5×4×2	WLE+ Mesh repair
2	32	Pakistan	Para 4	2 CS	Pain	U/S CT-MRI	1.8×1.6×1.9	WLE
3	28	Egypt	Para 3	1 CS	Pain	U/S	1.5×1.2×1.4	WLE
4	37	Egypt	Para 5	3 CS	Pain+ swelling	U/S	3×3×2.8	WLE
5	42	Saudi Arabia	Para 6	3 CS	Pain	U/S-CT-MRI	2×2×1.7	WLE
6	30	Saudi Arabia	Para 4	2 CS	Pain	U/S	1.5×2× 1.8	WLE
7	33	Egypt	Para 4	2 CS	Pain	U/S	3×2.5×2	WLE
8	16	Egypt	Para 0	Laparoscopy converted to laparotomy	Pain	U/S-CT	2.2×2.4×2.7	WLE
9	40	Saudi Arabia	Para 6	4 CS	Pain+ swelling	U/S-CT-MRI	4×3×2 2.1×2×1.6	WLE+ Mesh repair
10	35	Saudi Arabia	Para 5	3 CS	Pain	U/S-CT	2×2.6× 1.9	WLE

CS - cesarean section, WLE - wide local excision. U/S- ultrasound, CT - computerized tomography, MRI - Magnetic resonance imaging. All diagnosis confirmed by histopathological examination. No recurrence during follow up (mean 13.2 months)



**Figure 1** - A) Abdominal wall ultrasound showing ill defined ovale hypoechoic nodular lesion confined within the right rectus abdominis muscle displaying internal echos (arrow). B) Color Doppler abdominal wall showing 2.5 cm hypervascular heterogenous mass, confined within the right rectus abdominis muscle.



**Figure 2** - Computerized tomography scan showing A) isodense nodular ovoid thickening of the right rectus abdominis muscle (arrow) and B) with mild contrast uptake after injection (arrow).

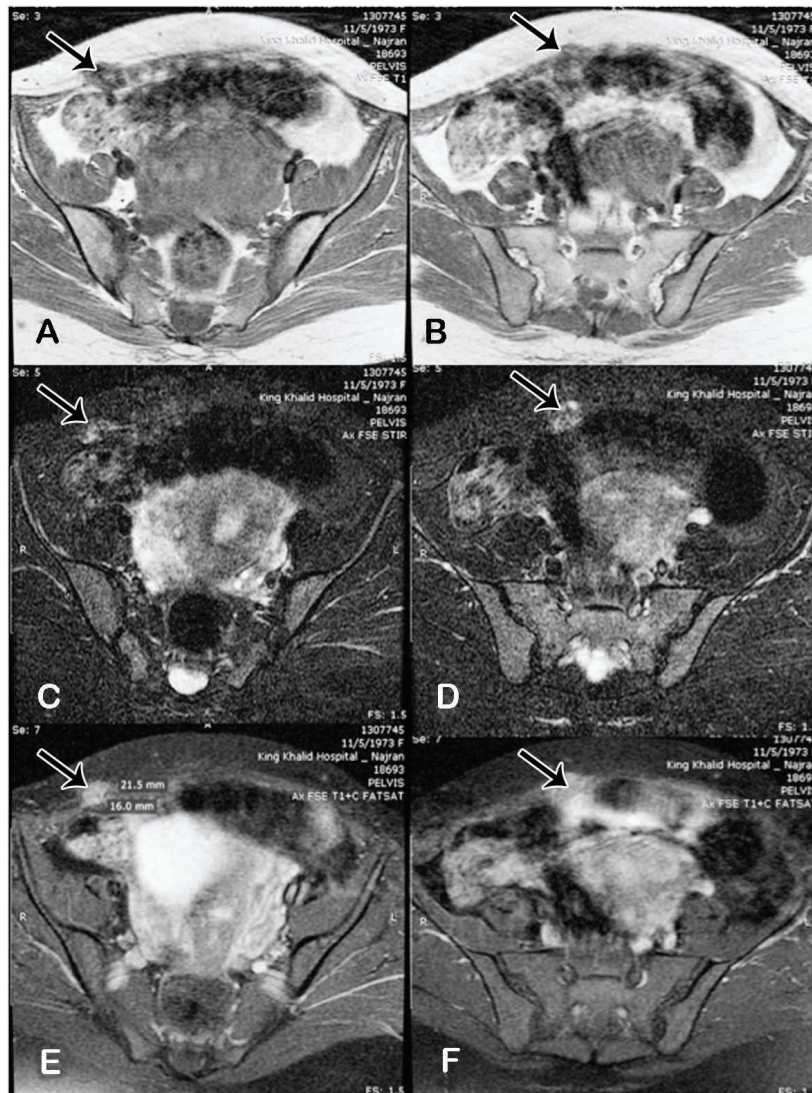


lesions were demonstrated in all cases as iso-intense to muscle on the T1-weighted sequence, as inhomogeneous hyperintensity on fat-saturated T2-weighted images and with marked enhancement following contrast administration (Figures 3a-3e). In addition, MRI depicted the lesion missed on sonography.

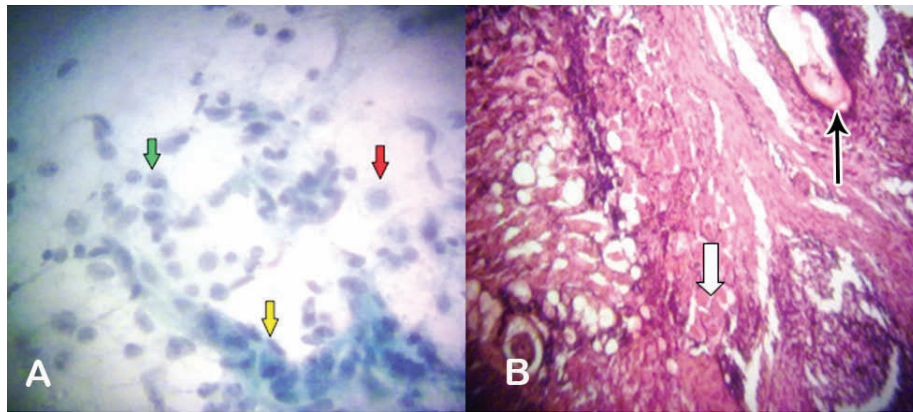
Pre-operative FNAC and intra-operative crush smear preparation was performed in 2 and 3 cases respectively. They were all suggestive of endometriosis, presenting at least 2 and sometimes all 3 criteria for diagnosis: endometrial glands, endometrial stroma or hemosiderin-laden histiocytes (Figure 4a).

Wide local excision with safety margin of 1 cm was carried out in all cases, only 2 requiring reinforcement with polypropylene mesh. One of the latter had 2 lesions in the right rectus muscle. The excised specimens ranged from 2-6 cm (mean 3.5) in size and 2-18 gm in mass (Figures 5a-5b).

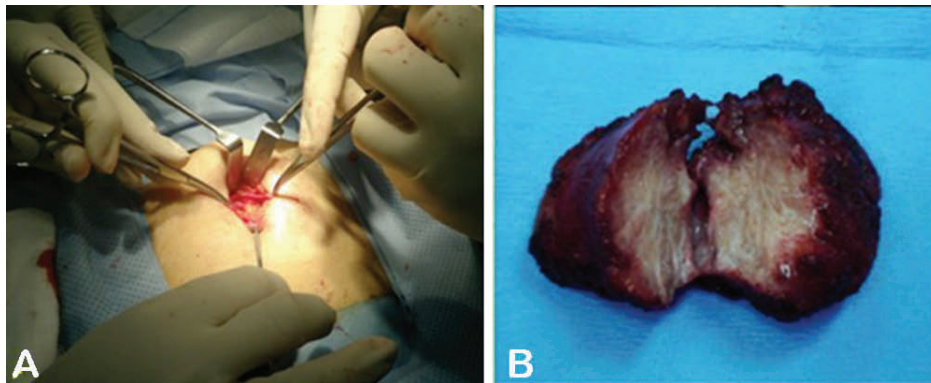
All lesions were confined to the rectus muscle, most of them were located midway between umbilicus and the CS scar, and in 8 instances the right rectus muscle was affected. All lesions were solitary except in one patient who had 2 lesions in the right rectus muscle. Histological examination confirmed the diagnosis



**Figure 3** - Magnetic resonance imaging of the pelvis showing A) 2 concomitant lesions in the right rectus abdominis muscle (filled and empty arrows) A, B) displaying nearly isointense signal in T1 weighted images, C, D) hyperintense signal in STIR weighted images, and E, F) with significant contrast uptake in T1 fat saturation (FAT SAT) weighted images.



**Figure 4** - Photograph of A) Peroperative crush smear from abdominal wall endometriosis; 400x, showing endometrial low columnar epithelium (green arrow), hemosiderin-laden histiocytes (red) and endometrial stromal fragments with spindle-shaped and oval cells (yellow). B) Hematoxylin and eosin stain: Endometriosis excised from left rectus abdominis muscle (broad white arrow). Histological examination revealed areas of typical endometrial glands surrounded by stroma (thin black arrow) and bordered by vessels with occasional foci of hemosiderin-laden macrophages, typical of endometriosis.



**Figure 5** - Photograph of A) patient with endometrioma located within the right rectus abdominis muscle; B) the excised lesion.

in all patients and revealed 2 of 3 characteristic of endometriosis: simple columnar epithelium-lined glands, vascular endometrial stroma, and foci of hemosiderin-laden macrophages (Figure 4b).

In all patients, gynecological examination and investigations revealed no pelvic endometriosis. All cases went into uneventful post-operative course with no complications or recurrences during the follow-up period (6-24 months with a mean of 13.2).

**Discussion.** Rectus abdominis endometrioma confined only to the body of the rectus abdominis muscle is rare and sparsely recorded in literature since it was first published in 1993 by Coly.<sup>7</sup> In 2012, only 19 cases were reported in medical annals, associated

with previous abdominal surgery such as CS or other operation. This was also stated by Calo et al in 2012 who added 2 more cases to this series.<sup>8</sup> Our study comprises 10 patients of different nationalities gathered over a short period in 2 different hospitals, which delineates how undermined this disease possibly is. Localized abdominal wall endometrioma, results from implantation of endometrial cells in the abdominal wall occurs most frequently after CS in an incidence of 0-03% and 1%.<sup>9</sup> However, rectus abdominis endometrioma reported in an absence of previous surgery.<sup>6,10-12</sup> Time lapse between the previous operation and the onset of symptoms vary from 6 months to 20 years.<sup>13,14</sup> In our series, all patients except one had a history of past CS and the time interval between clinical presentation and

previous surgery varied from 6 months to 6 years. We observed that rectus abdominis muscle endometrioma is not specific to any single ethnic group but from patients of different nationalities, this signifies that there is one common factor in CS. As most cases were related to CS, and preventive measures should be taken during CS to minimize the chances of endometrial tissue implantation in the abdominal wall. For prophylaxis of endometriosis after CS, some authors advocate vigorous wound irrigation with saline before closure of the abdominal wall.<sup>11,15</sup> In addition, we recommend complete isolation of the abdominal wall from the field of operation and anatomically-layered closure of the wound.

Several theories have been proposed for the development of extra-pelvic endometriosis including metaplasia, retrograde menstruation, venous or lymphatic metastasis and mechanical transplantation into scars at the time of surgery.<sup>16,17</sup> It had been reported recently a possible role of autoimmune disease in the pathogenesis of endometriosis.<sup>18</sup> In our series, history of CS suggests mechanical transplantation of endometrial cells as a plausible mechanism. Endometriosis of the abdominal wall is often mistaken both clinically and radiologically for other abnormalities such as incisional and ventral hernias, hematoma, abscess and benign or malignant subcutaneous tumors.<sup>5</sup> Diagnosis requires high index of suspicion as the accurate preoperative diagnosis is only 33%.<sup>19</sup> Our early patients were diagnosed only after histopathological examination of the excised mass, but with further exposure, the disease was suspected clinically from the history and confirmed by radiological and histopathological examinations. Many authors stated that imaging studies such as U/S, CT or MRI are non specific to make a definite diagnosis for endometriosis.<sup>2,5-7,20</sup> Ultrasonography was used routinely for assessing patients with abdominal pain. However, endometrial lesions in the abdominal wall may be missed during sonographic examination when the appropriate probe is not used, particularly in obese patients. High-resolution superficial transducer should be used for better assessment of the superficial rectus abdominis muscle nodule. In view of the wide morphological spectrum of endometriosis, varying from purely cystic lesions to solid deposits or fibrosis,<sup>9</sup> the almost invariably solid aspect of rectus abdominis endometriosis in our study is noteworthy. Sonographic examination overlooked the abdominal wall endometrioma in one of our patients, possibly because of failure to focus on the near field. At color Doppler examination, as noted in our series intra-

lesional vascularization is abundantly seen if the lesion has a diameter of greater than 3 cm, whereas hardly any such sign is detected in lesions smaller than 1.5 cm. In lesions measuring between 2 and 3 cm, a few vascular pedicles can be seen, entering the mass at the periphery and displaying arterial and venous flow pattern. Computerized tomography scan and MRI were not routinely used in our cases as it is expensive and no definite diagnosis, and only used in suspecting cases of tumors or to detect small lesions. Although FNA and crush smear cytology is helpful in suggesting the diagnosis and in excluding malignancy but seems to be inconclusive and associated with an increased risk of recurrence.<sup>21</sup> So we stopped it after few cases and we resorted directly to complete excision of the mass especially when there is no extension to deeper structures or peritoneum. The final and definite diagnosis comes from pathology of the excised mass.

The treatment for endometriotic foci in the rectus abdominis muscle is usually surgical with wide local excision to avoid recurrence.<sup>8,12,17</sup> Medical treatment is usually unsuccessful and gives temporary relief of symptoms and was reported ineffective in large endometriomas,<sup>4</sup> for these reasons we choose surgical treatment as the mainstay of management. There are several reasons justifying the fact that rectus abdominis muscle endometriosis is rarely diagnosed: a) It is often overlooked by general surgeons due to the general belief that it is a rare condition. b) The symptoms associated to the mass are unspecific (pain and swelling), except its relation to the menstrual cycle; moreover, it is not always associated to pelvic endometriosis and related symptoms. c) Ultrasound is usually performed as a part of the diagnostic work-up for abdominal pain, but abdominal endometriomas are not associated to specific ultrasound findings and the lesion can even be missed when this procedure is not performed with the correct probe or in the case of obese patients. d) Rectus abdominis muscle endometriosis does not present specific findings on CT nor MRI as its appearance depends on the phase of the menstrual cycle, the proportion of stromal and glandular elements, the amount of bleeding, and the degree of surrounding inflammatory and fibrotic response.<sup>2,7</sup> e) Specific diagnosis can only be achieved by microscopic examination of the lesion. Pre-operative assessment can be made by fine-needle aspiration cytology (FNAC), as recommended by Koger,<sup>13</sup> Patterson,<sup>22</sup> and Calabrese.<sup>23</sup> The morphological criterion set for a diagnosis is the detection of at least 2 of the salient features: hemosiderin-carrying macrophages, endometrial stroma or endometrial glands identifiable



by their simple columnar epithelium.<sup>24</sup> In equivocal cases, frozen section or crush-smear cytological examination offers a rapid peroperative diagnosis. After complete excision of the mass, histological assessment of the excised mass imparts the definite diagnosis after examination of formalin-fixed, paraffin-embedded sections.

Our study demonstrated that: a) Rectus abdominis muscle endometriosis is not as rare as we thought. Even though the clinical presentation is not specific, such condition can be suspected on the basis of the medical history of the patients. b) In fact previous abdominal surgery and specifically CS was reported nearly in all patients considered. c) In our experience, ultrasound detected almost all the masses, thus it turned out to be a useful diagnostic tool, when high-resolution superficial transducer are used. Moreover, almost invariably solid aspect of rectus abdominis endometriosis in our study is noteworthy. Another important finding is the appearance of intra-lesional vascularization in our series. It is evident when the lesion exceeds the size of 3 cm, while it is hardly identified in <1.5 cm sized lesions. Masses measuring 2-3 cm are characterized by few vascular pedicles entering the mass at the periphery and displaying arterial and venous flow pattern. d) Our study confirms the scarce specificity of CT scan that demonstrates only focal tissue stranding and thickening of the rectus abdominal muscle, as noted in 6 of our patients. Under MRI the mass was iso-intense to muscle in T1 images and hyper-intense in STIR sequence with contrast enhancement after injection but no classical MRI signs were detected. Thus, MRI reveals unspecific features and its usefulness is limited to the detection of very small masses and to the distinction between endometrial tissue and surrounding structures.

**Study limitations.** This is a descriptive study carried out on few numbers of cases collected at certain time and the short follow up period after the treatment needs more studies on large scale basis to know the exact incidence of this rare disease.

**Implication of findings.** Every surgeon should be aware on this rare occurrence when dealing with female patients presented with abdominal pain especially if there is a history of CS, and further investigation via imaging modalities is needed to avoid missing the diagnosis.

In conclusion, rectus abdominis endometriosis is often misdiagnosed as it may occur years after the CS. The pain is often non-cyclic in nature and there is not always a palpable mass. We conclude that this

disease is not as rare as was thought before and while imaging studies were non specific, we should include it in the differential diagnosis of abdominal wall masses in reproductive-age females. The final diagnosis of endometriosis rests on microscopic examination of the lesion. Surgical treatment is the main stay of cure for this disease.

## References

- Child TJ, Tan SL. Endometriosis: aetiology, pathogenesis and treatment. *Drugs* 2001; 61: 1735-1750.
- Coeman V, Scirot R, Van Breuseghem I: Rectus abdominis endometriosis: A report of two cases. *Br J Radiol* 2005; 78: 68-71.
- Hill JA. Immunology and endometriosis. fact, artefact, or epiphenomenon. *Obstet Gynecol Clin North Am* 1997; 24: 291-306.
- Horton JD, Dezee KJ, Ahnfeldt EP, Wagner M. Abdominal wall endometriosis: a surgeon's perspective and review of 445 cases. *Am J Surg* 2008; 196: 207-212.
- Tomas E, Martin A, Garfia C, Gomez FS, Morillas JD, Tortajada GC, et al. Abdominal wall endometriosis in absence of previous surgery. *J Ultrasound Med* 1999; 18: 373-374.
- Ideyi SC, Schein M, Niazi M, Gerst PH.: Spontaneous endometriosis of the abdominal wall. *Digestive Surg* 2003; 20: 246-248.
- Coley BD, Casola G. Incisional endometrioma involving the rectus abdominis muscle and subcutaneous tissues: CT appearance. *AJR Am J Roentgenol* 1993; 160: 549-550.
- Calò PG, Ambu R, Medas F, Longheu A, Pisano G, Nicolosi A. Rectus abdominis muscle endometriosis Report of two cases and review of the literature. *Ann Ital Chir* 2012; 20; [Epub ahead of print]
- Hensen JH, Van Breda Vriesman AC, Puylaert JB. Abdominal wall endometriosis: clinical presentation and imaging features with emphasis on sonography. *AJR Am J Roentgenol* 2006; 186: 616-620.
- Esinler I, Guvens S, Akyol D, Guvendag Guven ES, Taskiran C, Ayhan A. Abdominal wall endometriosis without previous surgery. *J Obstet Gynecol* 2004; 24: 931.
- Kocakusak A, Arpinar E, Arikan S, Demirbag N, Tarlaci A, Kabaca C. Abdominal wall endometriosis: a diagnostic dilemma for surgeons. *Med Princ Pract* 2005; 14: 434-437.
- Granese R, Cucinella G, Barresi V, Navarra G, Candiani M, Triolo O. Isolated endometriosis on the rectus abdominis muscle in women without a history of abdominal surgery: a rare and intriguing finding. *J Minim Invasive Gynecol* 2009; 16: 798-801.
- Koger KE, Shatney CH, Hodge K, McClenathan JH. Surgical scar endometrioma. *Surg Gynecol Obstet* 1993; 177: 243-246.
- Thylan S. abdominal wall endometrioma in a laparoscopic trocar tract: a case report. *Am Surg* 1996; 62: 617.
- Wasfie T, Gomez E, Seon S, Zado B. Abdominal wall endometrioma after cesarean section: a preventable complication. *Int Surg* 2002; 87: 175-177.
- Gunes M, Kayikcioglu F, Ozturkoglu E, Haberal A. Incisional endometriosis after caesarean section, episiotomy and other gynecologic procedures. *J Obstet Gynaecol Res* 2005; 31: 471-475.

17. Giannella L, La Marca A, Ternelli G, Menozzi G. Rectus abdominis muscle endometriosis: case report and review of the literature. *J Obstet Gynaecol Res* 2010; 36: 902-906.
18. Marci R, Lo Monte G, Soave I, Bianchi A, Patella A, Wenger JM. Rectus abdominis muscle endometriotic mass in a woman affected by multiple sclerosis. *J Obstet Gynaecol Res* 2013; 39: 462-465.
19. Erkan N, Hacıyanlı M, Sayhan H. Abdominal wall endometriomas. *Int J Gynaecol Obstet* 2005; 89: 59-60.
20. Woodward PJ, Sohaey R, Mezzetti TP. Endometriosis: radiologic-pathologic correlation. *Radiographics* 2001; 21: 193-2160.
21. Bumpers HL, Butler KL, Best IM. Endometrioma of the abdominal wall. *Am J Obstet Gynaecol* 2002; 187: 1709-1710.
22. Patterson GK, Winburn GB: Abdominal wall endometriomas: Report of eight cases. *Am Surg* 1999; 65: 36-39.
23. Calabrese L, Delmonte O, Mari R. Endometriosis of the abdominal wall. Clinical case and review of literature. *Acta Biomed. Atheneo Parmense* 1997; 68: 35-43.
24. Kurman R, editors. Blaunstein's Pathology of the female genital tract. 4th ed. New York (NY): Springer Veerlag; 1994.

#### Related Articles

Vatansever SH, Inan SV, Giray GS, Sayhan S, Ozbilgin KM, Sancı M. The distribution of apoptosis and related proteins in ovarian endometriosis. *Saudi Med J* 2006; 27: 1240-1243.

Bhat SN, Mohanty SP, Kustagi P. Endometriosis presenting like a psoas abscess. *Saudi Med J* 2007; 28: 952-954.

Dutta P, Bhat MH, Bhansali A, Kumar V. A young woman with endometriosis of kidney. *Saudi Med J* 2006; 27: 244-246.