

# Delayed bronchial rupture repair

## *A revisit to mucus basics*

Yasser M. Aljehani, MD, SCC Surg, Mohamed H. Ahmad, MD, FFCTS, Omniah A. Alashgar, MBBS, Mahmoud H. Ashour, FRCS, FEBTCS.

### ABSTRACT

تعتبر الصدمات الغير حادة للصدر أكثر أنواع الإصابات التي تصيب منطقة الصدر شيوعاً، وتعد إصابات القصبة الهوائية والشعب الهوائية من الإصابات النادرة وتشخيص ذلك وعلاجه يحتاج إلى درجة عالية من الحس. نستعرض هنا حالة تمزق الشعبة الهوائية الرئيسية اليسرى حدث فيها تأخر في المعالجة الجراحية لمدة عام بعد الإصابة، مع شفاء تام للرئة بعد التدخل الجراحي. فالهدف من هذا التقرير هو إظهار إمكانية التدخل الجراحي بصرف النظر عن طول المدة بعد الحادث، مع توضيح دور الأنسجة الخلوية والمخاط وكفاءتها في قهر العدوى في الحالات المزمنة لانكماش الرئة.

Blunt trauma to the chest accounts for most thoracic injury cases. Tracheobronchial injuries are rare. They require high index of suspicion to diagnose and manage promptly. We present a case of left main bronchial rupture, in which delayed surgical repair was carried out after more than a year from the initial injury with complete resolution of the injury. This report adds to the literature the feasibility of aiming for surgical repair regardless of the delayed duration. The emphasis was drawn to the cellular and mucus preservative capacity to combat infection in these chronically collapsed lungs.

*Saudi Med J 2013; Vol. 34 (2): 195-198*

*From the Department of Surgery, Section of Thoracic Surgery, King Faisal Specialist Hospital & Research Centre, Riyadh, Kingdom of Saudi Arabia.*

*Received 28th August 2012. Accepted 2nd December 2012.*

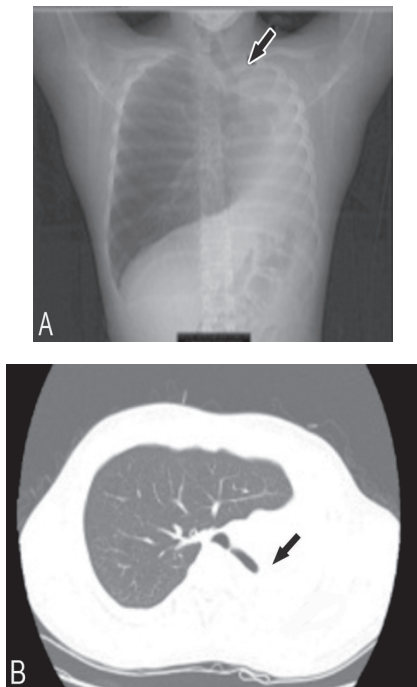
*Address correspondence and reprint request to: Asst. Prof. Yasser M. Aljehani, Department of Surgery, Section of Thoracic Surgery, King Faisal Specialist Hospital & Research Centre, Riyadh, Kingdom of Saudi Arabia. Tel. +966 542253333. E-mail: altahlawi@hotmail.com*

Tracheobronchial ruptures (TBR) are uncommon. By definition, it includes any injury between the cricoid cartilage and the segmental bronchi. They result from motor vehicle accidents (MVA), fall from heights, or others. High index of suspicion is required to diagnose them and promptly managed accordingly. Reporting has added much to the understanding of the mechanisms, which lead to better management. Surgical repair remains the gold standard for management in the acute, within 24-48 hours, as well as the delayed phase, which extends to years in some reports.<sup>1</sup> As stated previously, TBR is uncommon, especially the delayed category. Some believes that the collapsed lung will never re-expand due to fibrosis, and proceed with pneumonectomy. We hope that our report will support the notion of attempting to repair the delayed ruptures by all means. The physiological defender in the lung, mainly the mucus, is an important factor to preserve these collapsed lungs during the delayed period.

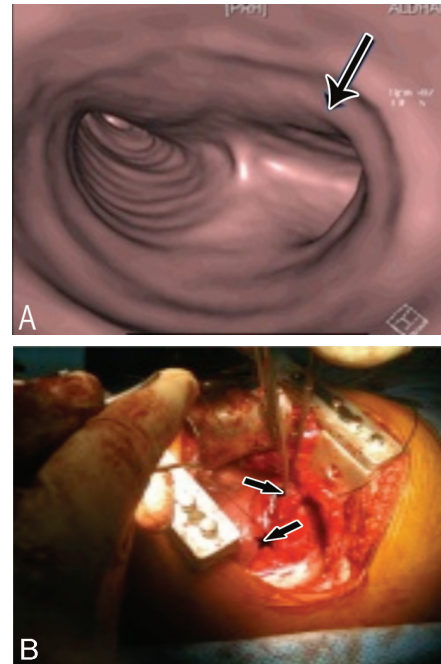
**Case Report.** The patient was a 16-year-old male who was a victim of MVA more than a year prior to presentation. The exact mechanism could not be recalled. He sustained severe head injury, for which he was intubated, and left-sided hemopneumothorax was managed by chest tube insertion. No specific detail was available regarding the hospital course since he was referred more than a year later. Upon arrival, his complaint was moderate exertional dyspnea, otherwise he was well-nourished with stable vital signs. Examination revealed diminished movement on the left hemithorax with almost absent breath sounds on the same side. His

**Disclosure.** The authors have no conflict of interests, and the work was not supported or funded by any drug company.

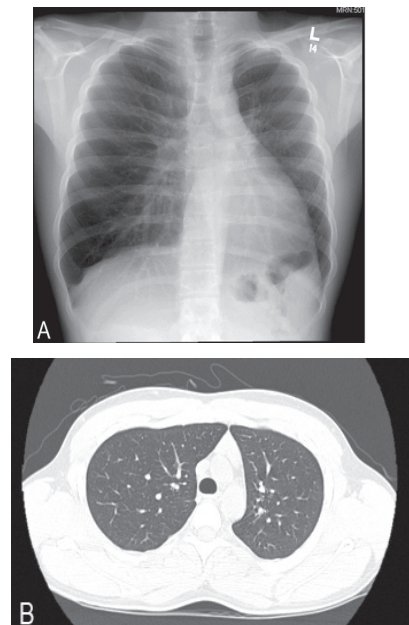
laboratory investigations were within normal levels, and his initial chest x-ray (CXR) showed complete collapse of the left lung with mediastinal shift to same side, and compensatory emphysema of the right lung. A chest CT revealed the findings on CXR (Figure 1A), and a complete cut-off of the left main bronchus was observed (Figure 1B). A virtual bronchography confirmed the findings as well. A fiberoptic bronchoscopy was carried out, and it confirmed the complete obstruction at the level of the left main bronchus (Figure 2A). Cardiac MRI was carried out to assess the pulmonary arteries anatomy and flow concluding a normal study (Figure 2B). Echocardiography and brain CT scan were normal. He was prepared and taken to the operating room. An epidural catheter and right double lumen tube was inserted, and confirmed by fiberoptic bronchoscopy. Through a muscle-sparing posterolateral thoracotomy, the left hemithorax was explored through the fifth intercostal space. Interestingly, there were neither extensive adhesions nor effusion. Exploration of the hilum was proceeded. It was difficult to identify the left bronchus with the extensive fibrosis around. The bronchus was completely disrupted with complete



**Figure 1** - A CT of the chest: A) scout film demonstrating the totally atelectatic left lung with compensatory right lung emphysema and shift of mediastinum. The arrow indicates shifted trachea and mediastinum; B) axial CT demonstrating the cut-off of the left main bronchus (arrow).



**Figure 2** - Virtual bronchography demonstrating the endoluminal left main bronchus obstruction. The arrow indicates the orifice of the obliterated left main bronchus (A). Intraoperative picture demonstrating the stay-sutures (lower arrow) corresponding to the proximal left bronchus and the totally separated left main bronchial stump, which is filled with granulation and fibrosis (B). The upper arrow corresponds to the distal bronchus as it enters the lung.



**Figure 3** - Post-operative chest x-ray demonstrating a fully expanded left lung (A). Chest CT obtained after a year revealed a normal study confirming the patency of the left main bronchus (B).

separation of approximately 4 cm distance in between; it was filled with granulation and fibrous tissues (Figure 2B). Skeletonization of the proximal and distal parts of the left bronchus was achieved. Refashioning of the stumps was carried out by excising a ring from each end. The distal lung was suctioned out of the thick tenacious retained mucus and secretions. Anastomosis was proceeded by applying 2 stay-sutures, starting with the posterior membranous layer. Anastomosis was carried out in continuous fashion for the posterior membranous layer, and simple interrupted for the anterior cartilaginous layer utilizing monofilament absorbable sutures (Monocryl 2/0). Inflation test confirmed instant, and full expansion of the lung. Air seal and hemostasis was insured. Chest tubes were inserted and closure was carried out in the usual fashion. The patient had an uneventful post-operative course and was discharged in good condition. His postoperative CXR showed fully expanded lungs (Figure 3A). His follow up after one year revealed complete resolution of his condition, and chest CT revealed a normal study (Figure 3B) confirming the patency of the left main bronchus.

**Discussion.** Early description of a ruptured right main bronchus in an autopsy back in 1927 in a 30-year-old woman was by Kirnitzki. The TBR is rare, accounting for 1% of all traumas.<sup>3</sup> For those patients who reach the hospitals, full recovery is achieved in most of the cases. The incidence of such injury is increasing possibly due to increased trauma incidence and better diagnostic modalities. The TBR is secondary to blunt trauma in 2.5-3.2% of cases in adults, where in pediatric population, it is estimated to be approximately 0.7-2.8%.<sup>4</sup> It is more common in males, as trauma is more in males, generally. Adolescent are commonly affected. The predominant affected side is the right, however some reports observed no predominance.<sup>5</sup> Approximately 70% of ruptures are identified in the first 24 hours, while the remaining 30% are identified within one month or even more.<sup>1</sup> Three mechanisms have been postulated: 1) decrease antero-posterior AP diameter; 2) tracheobronchial tree crushed between the sternum and the vertebra with a closed epiglottis; and 3) rapid deceleration. All lead to traction on the carina where shearing force at fixed point occur.<sup>4</sup> Eighty percent of injuries occur within 2 cm of the carina.<sup>6</sup> The symptoms and signs depend on whether the peribronchial tissues are intact or not. Dyspnea (77%) and cervical surgical emphysema (85%) are the most common.<sup>4</sup> They enter the delayed phase, where late symptoms and signs developed. They include recurrent pulmonary infections, productive cough, and/or fever. These

are mainly due to atelectasis, or even bronchiectasis.<sup>5</sup> It has been reported that children are more prone to such injury, because the soft resilient thorax transfer more kinetic energy to thoracic structure including the tracheobronchial tree.<sup>5,6</sup> The CXR is a key in diagnosis. As mentioned, if peribronchial tissues and pleura are not intact (type 1) with communication; massive pneumothorax (in 60% of cases), cervical, mediastinal emphysema, or hemothorax will be present.<sup>4</sup> In type 2 where the tissues remain intact and no communication exist; less pronounced CXR findings could be seen.

The following are radiological findings, which might be found in cases of TBR; falling lung sign due to avulsed root, discontinuity of air column, or surgical emphysema (especially if close to the carina). In delayed presentation; sequelae of stricture and stenosis (atelectasis or bronchiectasis) predominates. Fiberoptic bronchoscopy is indicated and findings indicating injury includes clotted blood, edema, or erythema, however these underestimate the real extent of the injury. In acute setting, surgical repair is the standard. Indications for surgery depend on clinical, radiological and endoscopic assessment, but clear indications are tension pneumothorax, tracheo bronchopleural fistula after drainage, increasing pneumomediastinum, or surgical emphysema (despite conservative measures), transmural tear >2 cm, and prolapsed esophageal wall into trachea or mediastinitis.<sup>3,6</sup> In delay settings, granulation and fibrosis starts to fill the distal ruptured segment in 3 weeks. Some authors advice to wait and control inflammation and sepsis of the stump before surgery.<sup>5</sup> We believe that mucus production in the distal airway and the collapsed lung has helped in preventing infection, and consequently the destruction of that lung after all this prolonged period. Literature describing the biophysical properties and function of mucus in the respiratory tract cannot be overemphasized. Mucus is a complex viscous adherent secretion synthesized by specialized goblet cells in the respiratory columnar epithelium. It functions as a lubricant, maintainer of a hydrated layer over the epithelium, serving as a barrier to bacteria, different pathogens, and noxious substances. It is composed mainly of water (95%) but contains salts, lipids, phospholipids and cholesterol, in addition to proteins, which include lysozyme, immunoglobulins, defensins, growth factors, and trefoil factors. These are the defenders against infection. The mucin glycosylation creates diversity, which is important in facilitating adherence of organisms to mucus prior to mucociliary clearance, and this is considered an important defenders of the airways.<sup>7</sup>

We think that our patient had the benefit of the mucus functions, which helped to conserve this perfused, collapsed lung for more than one year. The surgical approach depends on the location and length of the injury, keeping in mind that extended pulmonary resection can be carried out. Segmentectomy, lobectomy, or pneumonectomy have been reported, lung parenchyma can undergo fibrosis and fails to expand. Basically, it is an end to end anastomosis, mucosa to mucosa with absorbable sutures (to prevent granuloma), tension free, with preservation of peribronchial tissues and coverage of anastomotic line by muscle, pericardial fat, pleural or mediastinal fat pad.<sup>4</sup> Successful repair approaches 90%. Morbidities include voice dysfunction, hoarseness, dysphonia, which usually resolve, bleeding, empyema, stenosis, or mediastinitis. The mortality is higher in the conservatively managed patients but could be related to the other extensive injuries.<sup>1</sup>

In conclusion, TBR are uncommon injuries, which requires high index of suspicion. The surgical repair is indicated even in the delayed phases with good outcome. The defensive properties of mucus cannot be overemphasized.

**Acknowledgment.** The authors gratefully acknowledge and thank Miss Mariam Alosaimi for editing the operative pictures.

## References

1. Wu CY, Chen TP, Liu YH, Ko PJ, Liu HP. Successful treatment of complicated tracheobronchial rupture using primary surgical repair. *Chang Gung Med J* 2005; 28: 662-667.
2. Glinjongol C, Pakdirat B. Management of tracheobronchial injuries: a 10-year experience at Ratchaburi hospital. *J Med Assoc Thai* 2005; 88: 32-40.
3. Kayani AG, Pervaiz AA, Umair B, Siddique K, Khalique K. Right main bronchial disruption due to blunt trauma. *J Coll Physicians Surg Pak* 2009; 19: 249-251.
4. Ozdulger A, Cetin G, Erkmen Gulhan S, Topcu S, Tastepi I, Kaya S. A review of 24 patients with bronchial ruptures: is delay in diagnosis more common in children? *Eur J Cardiothorac Surg* 2003; 23: 379-383.
5. Gwely NN. Blunt traumatic bronchial rupture in patients younger than 18 years. *Asian Cardiovasc Thorac Ann* 2009; 17: 598-603.
6. Menon RG, Maddali MM, Valliathu J, Bulushi AAW. Delayed diagnosis of bronchial transaction following blunt chest trauma. *Ind J Thorac Cardiovasc Surg* 2008; 24: 15-17.
7. Bansil R, Turner BS. Mucin structure, aggregation, physiological functions and biomedical applications. *Current Opinion in Colloid & Interface Science* 2006; 11: 164-170.

## Supplements

- \* Supplements will be considered for work including proceedings of conferences or subject matter covering an important topic
- \* Material can be in the form of original work or abstracts.
- \* Material in supplements will be for the purpose of teaching rather than research.
- \* The Guest Editor will ensure that the financial cost of production of the supplement is covered.
- \* Supplements will be distributed with the regular issue of the journal but further copies can be ordered upon request.
- \* Material will be made available on Saudi Medical Journal website