

Fatal hemophagocytic syndrome as a manifestation of immune reconstitution syndrome in a patient with acquired immunodeficiency syndrome

Samreen M. Safdar, MD, MRCP, Jalil U. Rehman, MD, MRCP, Eba M. Samman, MD, FRCP, Nezar M. Bahabri, MD, FRCPC.

ABSTRACT

يعد داء البلعمية حالة مرضية مهددة للحياة ومضرة توصف بالتهاب زائد غير مسيطر عليه ينتج عن نقص المناعة المكتسب أو الوراثي. في هذا التقرير نستعرض حالة مريض يبلغ من العمر 42 عاماً تم تشخيصه حديثاً بنقص المناعة نظراً لنقص عدد الخلايا اللمفاوية ($17/\text{mm}^3$)، والفيروس الحملية (أكثر من 100,000 نسخة/ملل باختبار البلمرة وخضع لعلاج مضاد للفيروسات (ريتونافير، فورمات تينوفير، ريتونافير، دورنافير) عدوى الالتهاب النقائي (الكلاراثومايسين، اتوفوكين). تم تشخيصه بمتلازمة البلعمة المعروفة (HLH). كما ظهرت لديه قلة الكريات الشاملة الحاد خلال علاجه بالعقاقير المضادة للفيروسات.

Hemophagocytic lymphohistiocytosis (HLH) is an aggressive and potentially life-threatening condition characterized by uncontrolled hyper inflammation caused by various inherited or acquired immune deficiencies. We report a case of a 42-year-old man, newly diagnosed with HIV on the basis of a low CD4 T lymphocyte count ($17/\text{mm}^3$) and HIV viral load $>100,000$ copies/mL by polymerase chain reaction tests who was undergoing an anti-retroviral regimen (emtricitabine, tenofovir disoproxil fumarate, ritonavir, and darunavir) and opportunistic infection prophylaxis (clarithromycin and atovaquone). He was concomitantly diagnosed with hemophagocytic syndrome, also known as HLH. He developed increasingly severe pancytopenia while on treatment with anti-retroviral drugs.

Saudi Med J 2013; Vol. 34 (8): 861-864

From the Departments of Medicine (Safdar, Samman, Bahabri) and Oncology (Rehman), King Faisal Specialist Hospital, Jeddah, Kingdom of Saudi Arabia.

Received 15th April 2013. Accepted 17th June 2013.

Address correspondence and reprint request to: Dr. Jalil U. Rehman, Department of Oncology MBC-J-64, King Faisal Specialist Hospital, PO Box 40047, Jeddah 21499, Kingdom of Saudi Arabia. E-mail: jaliljeddah@yahoo.com/jrehman@kfsbrc.edu.sa

Hemophagocytic lymphohistiocytosis (HLH) is an aggressive and potentially life-threatening condition characterized by uncontrolled hyper inflammation caused by various inherited or acquired immune deficiencies. Cardinal symptoms are prolonged fever, hepatosplenomegaly, and cytopenias. Central nervous system symptoms are common, and biochemical markers include elevated triglyceride and ferritin. In contrast to the familial form of HLH, acquired or reactive HLH develops secondary to a variety of viral, bacterial, and parasitic infections; drug use; malignancy; and various autoimmune diseases.¹ It has been described in patients with advanced stages of human immunodeficiency virus (HIV) infection, but may occur shortly after the initiation of highly active antiretroviral therapy (HAART) in the treatment of HIV-acquired/immunodeficiency syndrome (AIDS).² Here, we present a case of reactive hemophagocytosis associated with the initiation of HAART, representing severe immune reconstitution syndrome (IRIS).

Case Report. A 42-year-old man, newly diagnosed with HIV on the basis of a low CD4 T lymphocyte count (17 cells/ mm^3 [normal range: 500 – 1000 cells/ mm^3]) and HIV viral load $>100,000$ copies/mL by polymerase chain reaction (PCR) tests who was undergoing an antiretroviral regimen (emtricitabine, tenofovir disoproxil fumarate, ritonavir, and darunavir) and opportunistic infection prophylaxis (clarithromycin and atovaquone). Six weeks after HAART initiation, he was admitted to the hospital due to a 3-week history of high fever (maximum temperature, 39.4°C), chills, and malaise. He was taking no other medications, had no recent travel or animal exposure, and had no history of shortness of breath, chest pain, odynophagia, oral thrush, abdominal pain, diarrhea, dysuria or any skin rash. His physical characteristics upon admission were as follows: oral temperature 39.8°C ; pulse 110 beats/min; blood pressure 110/70 mm Hg; respiratory rate

20/min; and SpO₂ 98% on room air. His physical examination revealed a significant hepatosplenomegaly. His initial laboratory test results were as follows: white blood cell count of $3.81 \times 10^9/L$, with 67.9% segmented neutrophils, 18% lymphocytes, 8.8% monocytes, and 1% basophils. Hemoglobin was 7.8 g/dL and the platelet count was $47 \times 10^9/L$. There was no evidence of bleeding or hemolysis. Initial renal, hepatic, and autoimmune profiles as well as vitamin B12 and folate levels were normal. Over the next 2 days, the patient exhibited hemodynamic deterioration and became confused. Blood, urine, and sputum cultures were negative for bacteria, mycobacteria, and fungi. Computed tomography scans of the brain was also unremarkable. Moreover, all serological tests were negative, including the presence of *Mycoplasma pneumoniae*, parvovirus, Coxsackie B virus, hepatitis A-C, Brucella, malaria, varicella, cytomegalovirus, Epstein-Barr virus, and toxoplasmosis, thus failure to identify the underlying cause of pancytopenia. The CD4 count was $410 \times 10^6/L$ and HIV PCR detected only 67 copies/mL. A peripheral smear showed worsening pancytopenia with few lymphoplasmacytoid cells. Abdominal and pelvic CT scans showed hepatosplenomegaly with enlarged mesenteric, retroperitoneal, external iliac, and para-aortic lymph nodes. He had persistent fever, confusion, and progressive pancytopenia. Immune reconstitution syndrome was suspected; hence, dexamethasone along with broad-spectrum antibiotics including meropenem, vancomycin, acyclovir, and caspofungin were administered. After ruling out all possibilities, bone marrow was examined for malignancy and other causes of pancytopenia. Surprisingly, the bone marrow exhibited significant hemophagocytosis with very active hematopoietic cells and engulfment of normal hematopoietic cells (Figures 1 and 2).

The patient remained febrile with temperatures up to 40°C. Within a few days, he became more hypotensive and developed acute respiratory distress due to rapid bilateral pleural effusion and his mental condition started deteriorating along with a rapid increase in creatinine level from 87-243 $\mu\text{mol/L}$, (50-100 $\mu\text{mol/L}$) necessitating continuous renal replacement therapy (CRRT). Meanwhile, his white blood cell

count decreased to $1.7 \times 10^9/L$, (normal range: 4.8-10.8 $\times 10^9/L$) hemoglobin dropped to 6.5 g/dL (normal range for male: 13.6-17.5 g/dL) and he developed severe thrombocytopenia with a platelet count of $4 \times 10^9/L$ (normal range 150-450 $\times 10^9/L$). Moreover, international normalized ratio (INR) increased to 4.6 (normal: 0.8-1.2) with rapidly increasing values for liver transaminases, and direct bilirubin. Other parameters suggestive of hemophagocytosis were increasing lactate dehydrogenase and ferritin levels of 2099 U/L (normal: 88-230 U/L) and 31,435 mcg/L (16-300 mcg/L), respectively, as well as a high triglyceride level of 3 mmol/L. However, rapid clinical and biochemical deterioration continued despite antibiotics and antiretrovirals, indicating disseminated intravascular coagulation.

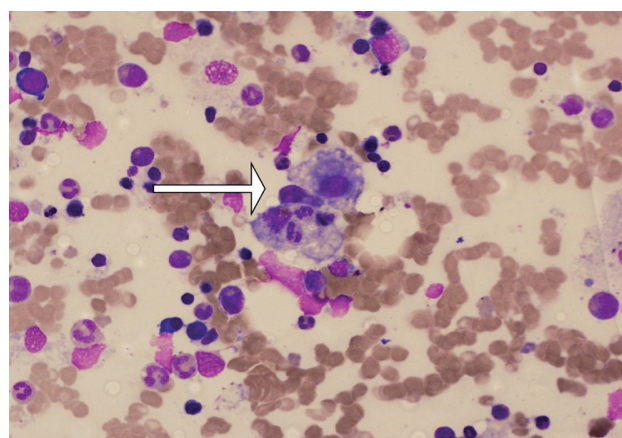


Figure 1 - Bone marrow aspirate showing 2 hemophagocytic cells engulfing neutrophils (arrow) (Wright-Giemsa stain, x 600).

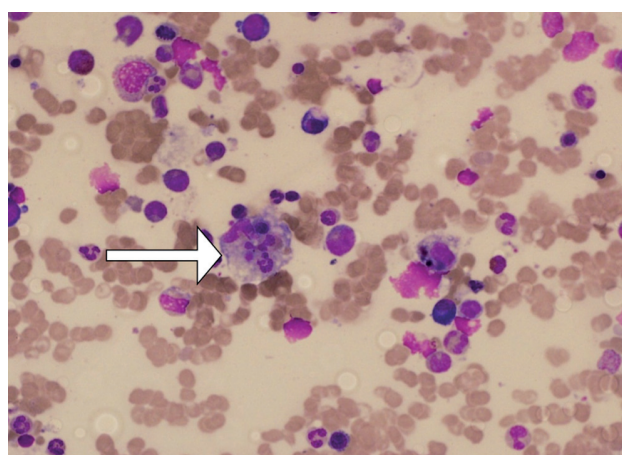


Figure 2 - Bone marrow aspirate showing hemophagocytic cells engulfing neutrophils, red cells, and lymphocytes (arrow) (Wright-Giemsa stain, x600).

Disclosure. Authors have no conflict of interests, and the work was not supported or funded by any drug company.

Despite multiple blood transfusions, fresh frozen plasma, CRRT, inotropic support, a trial empirical treatment with broad-spectrum antibiotics and steroids, he developed massive multi-organ failure with severe septic shock (acute physiology and chronic health evaluation score >35). On the 10th day after admission, he died from fatal hemophagocytic syndrome due to severe immune reconstitution.

Discussion. Hemophagocytic lymphohistiocytosis is a rare fulminant disease with multi-organ involvement.³ It is primarily due to the invasion of all organs and tissues by abnormal proliferated histiocytes and lymphocytes, which secrete large amount of cytokines, leading to severe hyper-inflammation.⁴ All genetic and acquired forms of HLH share almost the same pathophysiology. According to the HLH-2004 protocol, at least 5 out of 8 diagnostic criteria are required to establish the diagnosis of HLH unless there is an established molecular diagnosis or underlying family history. These include 5 initial diagnostic criteria as proposed in the HLH-94 protocol: fever, splenomegaly, hypertriglyceridemia ≥ 265 mg/dL, hypofibrinogenemia ≤ 150 mg/dL, and bicytopenia, with at least 2 of the following: hemoglobin ≤ 9 g/dL, platelets $< 100 \times 10^3/\mu\text{L}$, and neutrophils $< 1.0 \times 10^3/\mu\text{L}$ in the peripheral blood; evidence of hemophagocytosis in the bone marrow, spleen, or lymph nodes without evidence of malignancy; and 3 new criteria introduced in the HLH-2004 protocol: low or absent NK cell activity, hyperferritinemia ≥ 500 $\mu\text{g/L}$, and increased soluble interleukin 2 receptor levels. HLH may be the first HIV manifestation.⁶ It is often triggered by an opportunistic infection or can present as part of a condition known as immune reconstitution syndrome (IRIS), which is a paradoxical reaction associated with the reconstitution of the immune system. It typically occurs a few weeks to months after the initiation of HAART, usually in association with latent infections such as mycobacterial infections, cytomegalovirus, *Cryptococcus neoformans* and *Pneumocystis jirovecii*. The risk factors for IRIS include severe immunodeficiency (according to CD4 cell count), underlying disorders, antigen burden and rapid immune response to HAART.⁷ The primary pathophysiological abnormality in HLH patients is cytokine dysfunction, which results in the abnormal accumulation of histiocytes and activated T lymphocytes in almost all organs, leading to the phagocytosis of all lines of blood cells. Meanwhile, the underlying pathogenic features of IRIS are somehow related to increased γ -interferon, interleukins (especially the 2 and

6 subtypes and their soluble receptors), possibly due to quantitative and qualitative improvements in CD4 cells, as well as a shift in the balance between Th-1 and Th-2 responses. Moreover, there are high levels of macrophage colony-stimulating factor, which is produced by T cells; this in turn stimulates monocytes/macrophages, which are the major source of TNF- α and IL-6.⁸

Thus, it appears that the overproduction and abnormal proliferation of activated T cells is the main cause of the pathogenesis of HS. Although recent reports suggest that HLH is a manifestation of acute HIV infection with a relatively better outcome, even without immunomodulation therapy,⁹ most HLH cases diagnosed in the advanced stages of HIV infection are fatal within a year of presentation.¹⁰

In summary, the present patient had fever, pancytopenia, hypertriglyceridemia, hyperferritinemia, splenomegaly, high transaminases, high bilirubin, and hemophagocytosis, which were subsequently confirmed from a bone marrow specimen without evidence of malignancy. Moreover, imaging studies and a variety of cultures and serological tests for a number of pathogens failed to reveal any association with other opportunistic infections, suggesting that HLH be considered in cases of IRIS that manifests 3 weeks after the initiation of HAART therapy. As the pathophysiology of HLH and IRIS share many features, they may have been responsible for the fatal presentation of this patient.

In conclusion, HLH can manifest as IRIS within weeks or months after the initiation of HAART and is associated with significant morbidity and mortality.

Acknowledgment. The author would like to thanks Dr. Mayadah and Dr. Asma Younis, for providing technical support.

References

1. Filipovich AH. hemophagocytic lymphohistiocytosis (HLH) and related disorders. *Hematology Am Soc Hematol Educ Program* 2009; 1: 127-131.
2. Huang DB, Wu JJ, Hamill RJ. Reactive hemophagocytosis associated with the initiation of highly active antiretroviral therapy (HAART) in a patient with AIDS. *Scand J Infect Dis* 2004; 36: 516-519.
3. Nahum E, Ben-Ari J, Stain J, Schonfeld T. Hemophagocytic lymphohistiocytic syndrome: Unrecognized cause of multiple organ failure. *Pediatr Crit Care Med* 2000; 1: 51-54.
4. Ur Rehman J, Wali G, Sayes NM, Maulawi A, Aslam M, Khalid I. Novel influenza A (H1N1) virus-induced hemophagocytosis: first case reported in Saudi Arabia. *Ann Saudi Med* 2012; 32: 86-89.

5. Henter JI, Horne A, Aricó M, Egeler RM, Filipovich AH, Imashuku S, et al. HLH-2004: Diagnostic and therapeutic guidelines for hemophagocytic lymphohistiocytosis. *Pediatr Blood Cancer* 2007; 48: 124-131.
6. Castilletti C, Preziosi R, Bernardini G, Caterini A, Gomes V, Calcaterra S, et al. Hemophagocytic syndrome in a patient with acute human immunodeficiency virus infection. *Clin Infect Dis* 2004; 38: 1792-1793.
7. Jevtović DJ, Salemović D, Ranin J, Pesić I, Zerjav S, Djurković-Djaković O. The prevalence and risk of immune restoration disease in HIV-infected patients treated with highly active antiretroviral therapy. *HIV Med* 2005; 6: 140-143.
8. DeSimone JA, Pomerantz RJ, Babinchak TJ. Inflammatory reactions in HIV-1-infected persons after initiation of highly active antiretroviral therapy. *Ann Intern Med* 2000 19; 133: 447-454.
9. Sproat LO, Pantanowitz L, Lu CM, Dezube BJ. Human immunodeficiency virus-associated hemophagocytosis with iron-deficiency anemia and massive splenomegaly. *Clin Infect Dis* 2003; 37: e170-e173.
10. Cuttelod M, Pascual A, Baur Chaubert AS, Cometta A, Osih R, Duchosal MA, Cavassini M. Hemophagocytic syndrome after highly active antiretroviral therapy initiation: a life-threatening event related to immune restoration inflammatory syndrome? *AIDS* 2008; 22: 549-551.

Related Articles

Johnbull OS. A hole of human immunodeficiency virus HIV/AIDS and hunger in rural Nigerian communities. *Saudi Med J* 2008; 29: 622-623.

Halloush RA, Arabi H, Al-Abadi MA. Primary testicular non-Hodgkin's lymphoma with atrial mass as an initial presentation of acquired immunodeficiency syndrome. *Saudi Med J* 2007; 28: 1278-1280.

Al-Mazrou YY, Abouzeid MS, Al-Jeffri MH. Impact of health education on knowledge and attitudes of Saudi paramedical students toward HIV/AIDS. *Saudi Med J* 2005; 26: 1788-1795.