

Brief Communication

Cause analysis and therapeutic methods of chylous leakage after pancreaticoduodenectomy

Weiping Ji, MD, Juan Wang, MM,
Bing Song, MD, Kailian Zheng, MD, Hongyun Ma, MM,
Asaad Nadaf, MD, Zhuo Shao, MM, Gang Jin, MD.

ABSTRACT

Objectives: To study and analyze the causes of chylous leakage after pancreaticoduodenectomy.

Methods: We retrospectively analyzed 381 patients who underwent pancreaticoduodenectomy (including pylorus-preserving pancreaticoduodenectomy) in Shanghai Chang Hai Hospital Affiliated to the Second Military Medical University, Shanghai, China between January 2010 and December 2012. We also studied the relationship between postoperative chylous leakage and age, gender, surgical approach, and the tumor nature.

Results: The chylous leak was placed in 23 patients and the incidence of chylous leakage in patients was 0.6%. There was no significant difference in gender, age and tumor pathological pattern between the chylous leakage group and non-chylous leakage group. The incidence of chylous leakage in patients with N1 grade cancer was significantly higher than that in patients with N0 grade cancer ($p=0.001$). The incidence of chylous leakage in patients suffering R0 resection was significantly higher than that in patients suffering non-R0 resection ($p=0.008$). All patients were successfully treated conservatively.

Conclusion: The incidence of chylous leakage was 0.6% and the chylous leakage was closely linked with the tumor's grade malignancy and the range of radical resection.

Pancreaticoduodenectomy (PD) or pylorus-preserving pancreaticoduodenectomy (PPPD) is the standard surgical method of pancreatic head region tumors.¹ However, one of the common complications after PD is chylous leakage, and it may lead to longer hospital stays, increasing hospital costs, and even to more serious complications. Therefore, it is necessary to analyze and discuss the occurrence and treatment of chylous leakage. Clinical reports on chylous leakage after PD are relatively rare. The aim of this study is

to analyze the causes of chylous leakage after PD and summarize the experience of chylous leakage prevention and treatment.

Methods. Three hundred and eighty-one patients (213 males and 168 females) that underwent PD (n=78) or PPPD (n=303) were collected from Shanghai Chang Hai Hospital Affiliated to the Second Military Medical University, Shanghai, China between January 2010 and December 2012. The mean age was 62 years (range, 18-76 years). Two hundred and sixty-six patients had pancreatic malignant tumors, and 115 patients had pancreatic benign tumors. The daily drainage and the length of the postoperative hospital stay were recorded. The patients with malignant tumor underwent combined lymph node dissection, and the lymph node dissection method comprised conventional ligaturing, or suturing of lymphatic vessel broken ends.

Definition of diagnostic criteria of chylous leak.

Chylous leak was considered if there was a sudden increase in the volume of intraperitoneal drainage fluid after taking food for 1-2 days; the color was chylous-like milky white or pale yellow; or the chylous test result was positive. The diagnosis of chylous leakage is mainly based on clinical manifestations and chylous test; radionuclide lymphoscintigraphy and lymphangiography have a certain value in diagnosing chylous leakage,² but the practical application is rare.

Statistical analysis. The 2 groups were compared using the Chi-square test or Fisher's exact test, when applicable. Data are expressed as the number (percentage) depending on the data type. A p -value less than 0.05 was considered statistically significant. Statistical analysis was performed using the Statistical Package for Social Sciences software (SPSS Inc., Chicago, IL, USA) version 17.0.

Results. In all patients, chylous leak was placed in 23 patients and the incidence of chylous leakage in patients was 0.6%. There was no significant difference in gender, age, and tumor pathological pattern between

Disclosure. This study was supported by the National Natural Science Foundation (30772139), Youth Initial Fund of the Second Military Medical University (2013QN07, 2010QN10) and "1255" Hospital Discipline Construction Project (CH125542400), Shanghai, China.

the chylous leakage group and non-chylous leakage group. The incidence of chylous leakage in patients with regional lymph node-positive (N1) grade cancer was significantly higher compared with patients with regional lymph node-negative (N0) grade cancer ($p=0.001$). The incidence of chylous leakage in patients suffering R0 (no cancer cells are found in malignant tumor cut edge under a microscope) resection was significantly higher than that in patients suffering from non-R0 resection ($p=0.008$) (Table 1). Chylous leakage was occurred between 5-8 days (average 6 days) postoperatively and the average daily drainage volume was 355 ml (range 260-450 ml). The average hospital stay of the patients with single chylous leakage after surgery was 12 days (7-16 days) and all the patients were treated successfully.

Discussion. The incidence of chylous leakage found in our study was 0.6%, and there was no significant relationship between the chylous leakage and patients' gender, age, and tumor pathological pattern; we found that chylous leakage was closely linked with the tumor's grade malignancy and the range of radical resection. Chylous leakage, also known as lymphatic leakage, refers to the phenomenon that after lymphatic vessels are cut off or damaged by physical factors or inflammation,

chylous-like fluid leaks from the lymphatic vessels. van der Gaag et al³ analyzed 609 patients after PD and the postoperative chylous leakage incidence was approximately 11%. Meanwhile, Assumpcao et al⁴ reported a 1.3% chylous leakage incidence rate after PD surgery. The reason that the chylous leakage was closely linked with the tumor's grade malignancy and the range of radical resection may be that the patients with higher grade malignancy usually have a larger range of intraperitoneal lymph node dissection, so the lymphatic vessels were more seriously cut and damaged without timely detection and treatment, thus, it resulted in the leakage of lymphatic fluid.

Anatomically the thoracic duct's starting end is located at the right front of the vertebral body, and covered by the right crural diaphragm. As the location is very deep, it is not easily exposed and damaged in general intraperitoneal surgery. Meanwhile, the chylous pool is close to the roots of the celiac axis and the roots of the superior mesenteric artery (39 mm and 47 mm), the main lymph node is located near the superior mesenteric vessel and inferior mesenteric vessel, the aorta is near the lymph node, which is the lymph injecting into the chylous pool. To achieve the standards of lymph node dissection during the radical PD, we need to skeletonize the blood vessels, the main lymphatic axis, and large lymphatic vessels are very easily damaged, especially when dissecting the lymph nodes near the aorta, roots of celiac axis, and the roots of the superior mesenteric artery. Currently, there is no clear intraoperative identification method for lymphatic fluid and the broken ends of lymphatic vessels cannot be timely discovered, so a large volume of chylous-like fluid will leak from the broken ends or parts of lymphatic vessels, thus, forming chylous leakage.

The measures preventing the occurrence of chylous leakage when dissecting lymph nodes in the surgery may be to ligate the broken ends at the leakage location or suture the broken parts and avoid the electrical separation. We should also avoid incomplete lymph node resection and carefully check and observe whether there is a clear and transparent lymph fluid leaking carefully. Figures 1 & 2 show the intraoperative images of 2 patients without postoperative chylous leakage after pancreaticoduodenectomy. The broken ends or broken parts of lymphatic vessels (Figures 1 & 2) are timely ligated or sutured by silk thread; hence, effectively, preventing postoperative chylous leakage. Currently, there is no uniform standard for the treatment of chylous leakage. Some scholars believe that if fluid leakage is less than 500ml/d, treatment is not

Table 1 - Clinical data of patients with and without chylous leakage.

Clinical data	Patients with chylous leakage (n=23)		Patients without chylous leakage (n=358)		P-value
	n	(%)	n	(%)	
<i>Baseline characteristics</i>					
Average age (years)	61		60		
Male (%)	13	(56.5)	188	(52.5)	0.830
<i>Surgical method</i>					
PD (%)	4	(17.4)	74	(20.7)	0.333
PPPD (%)	19	(82.6)	284	(79.3)	1.000
<i>Pathological information (%)</i>					
Adenocarcinoma	4	(17.4)	167	(46.7)	0.090
Other malignancies	19	(82.6)	78	(21.8)	0.608
Benign tumors	4	(17.4)	93	(25.9)	0.080
Other diseases	19	(82.6)	20	(5.6)	0.622
<i>Malignancy grading (%) (n=245)</i>					
N0	4	(17.4)	136	(55.5)	0.277
N1 or more	19	(82.6)	109	(44.5)	0.001
<i>Radical resection (%) (n=243)</i>					
R0	4	(17.4)	212	(87.2)	0.008
Non-R0	19	(82.6)	31	(12.8)	0.708

N0 - regional lymph node-negative, N1 - regional lymph node-positive, R0 - no cancer cells are found in malignant tumor cut edge under a microscope, PD -pancreaticoduodenectomy, PPPD - pylorus-preserving pancreaticoduodenectomy

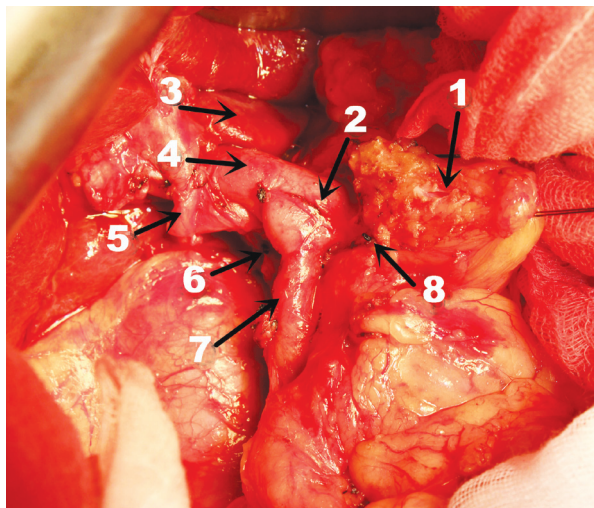


Figure 1 - Intraoperative photo of patient without postoperative chylous leakage after pancreaticoduodenectomy: 1) pancreas' broken ends; 2) splenic vein; 3) liver caudate lobe; 4) portal vein; 5) common hepatic artery (ectopic); 6 & 8 show the ligation site of lymphatic vessel broken ends; and 7) superior mesenteric vein. When dissecting the lymphatic vessels area in the surgery, sharp separation is adopted; if obvious lymph fluid outflow occurs, the broken ends are ligatured;

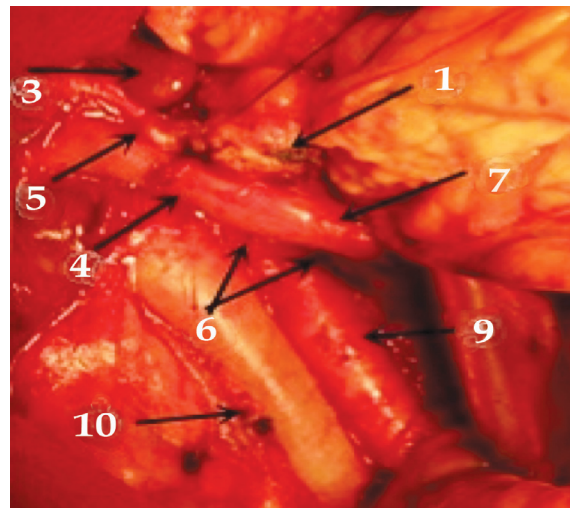


Figure 2 - Intraoperative photo of patient without postoperative chylous leakage after pancreaticoduodenectomy: 1) pancreas' broken ends; 3) liver caudate lobe; 4) portal vein; 5) common hepatic artery; 6) shows that mesentery broken ends are sutured when sharply separating pancreas uncinata mesentery; 7) superior mesenteric vein; 9) abdominal aorta; and 10) inferior vena vein.

necessary.⁵ After chylous leakage occurs, the patient diet should be immediately restricted and drainage should be maintained unobstructed to prevent infection caused by peritoneal effusion. Reducing lymph fluid formation in the early stage, and promoting the healing of lymphatic vessel broken ends and broken parts are also important. The intake of fatty foods should be reduced to inhibit lipid secretion and reduce lipid absorption. Adding proper parenteral nutrition, supplementing proper protein, vitamins and electrolytes, promoting protein synthesis, enhancing plasma colloid osmotic pressure, and promoting peritoneal effusion absorption are also required. If the fluid leakage is greater than 500 ml/d and continues to rise, the patients should adopt fasting and total parenteral nutrition to inhibit gastrointestinal fluid secretion. The changes in drainage volume should be observed carefully and the drainage tube can be removed when the peritoneal drainage fluid gradually decreases to be less than 5 mL for 3 serial days. Surgical treatment is rarely required for postoperative chylous leakage. It is generally considered that reoperation should comprehensively depend on daily leakage volume, duration, decreasing tendency, and patient's general condition. If leakage volume is greater than 1500mL/d or drainage volume remains at high levels (1000mL/d) after fasting, and total parenteral nutrition is supplied for more than one week, or lymphography

show a large lymphatic vessel broken parts, surgery should be adopted for chylous leakage treatment.⁶

In summary, chylous leakage after PD occurs mainly in radical resection and is linked with tumor features, dissection range, surgical tools, and basic operation. During dissecting abdominal lymph nodes, we should pay special attention to closing the broken ends and broken parts of the lymphatic vessel as well as avoiding the use of electric surgical means when dissecting the lymph node. Patients with postoperative chylous leakage can be treated by non-surgical treatments such as adequate drainage, fasting, somatostatin combined with intravenous hyperalimentation, and so forth.

However, this study is only the collection and retrospective analysis of the data from a single medical center. The evidence to support this recommendation is weakened by the lack of data from a randomized clinical trial of a prospective multicenter and large sample. We will carry out further prospective trials, looking for better ways for the prevention, and treatment of chylous leakage.

In conclusion, the incidence of chylous leakage showed in our study was 0.6% and there was no significant relationship between chylous leakage and patients' gender, age, and tumor pathological pattern, and chylous leakage after PD usually occurs after radical resection of malignant tumors.

Acknowledgment. The authors gratefully acknowledge Dr. Shiyue Chen for reviewing the images in this article.

Received 6th May 2014. Accepted 12th August 2014.

From the Department of General Surgery (Ji, Song, Zheng, Ma, Shao, Jin), Shanghai Chang Hai Hospital, the Department of General Surgery (Wang), Shanghai Chang Zheng Hospital, Second Military Medical University, Shanghai, China, and the Department of General Surgery (Nadaf), Tishreen Hospital, Military Medical Services Administration, Damascus, Syria. Address correspondence and reprints request to: Dr. Gang Jin, Department of General Surgery, Shanghai Chang Hai Hospital, Second Military Medical University, 800 Xiang Yin Road, Shanghai 200003, China. Tel. +86 (21) 31161058. Fax. +86 (21) 31161058. E-mail: jingang1971@126.com

References

1. Kim SC, Kim YH, Park KM, Lee YJ. Pancreatic cancer surgery: the state of the art. *Curr Drug Targets* 2012; 13: 764-771.
2. Leibovitch I, Mor Y, Golomb J, Ramon J. The diagnosis and management of postoperative chylous ascites. *J Urol* 2002; 167: 449-457.
3. van der Gaag NA, Verhaar AC, Haverkort EB, Busch OR, van Gulik TM, Gouma DJ. Chylous ascites after pancreaticoduodenectomy: introduction of a grading system. *J Am Coll Surg* 2008; 207: 751-757.
4. Assumpcao L, Cameron JL, Wolfgang CL, Edil B, Choti MA, Herman JM, et al. Incidence and management of chyle leaks following pancreatic resection: a high volume single-center institutional experience. *J Gastrointest Surg* 2008; 12: 1915-1923.
5. Kaas R, Rustman LD, Zoetmulder FA, et al. Chylous ascites after oncological abdominal surgery, incidence and treatment. *Eur J Surg Oncol* 2001; 27: 187-189.
6. Pabst TS 3rd, McIntyre KE Jr, Schilling JD, Hunter GC, Bernhard VM. Management of chyloperitoneum after abdominal aortic surgery. *Am J Surg* 1993; 166: 194-198.

Related Articles

Huang YK, Lu MS, Tsai FC, Ko PJ, Hsieh HC, Lin PJ. A forgotten complication following pancreatic resection. *Visceral artery pseudo-aneurysms. Saudi Med J* 2007; 28: 973-975.

Guraya SY, Murshid KR. Malignant duodenocolic fistula. *Various therapeutic surgical modalities. Saudi Med J* 2004; 25: 1111-1114.