

# Pediatric air gun shot injury

Ubaid U. Khan, MS<sub>C</sub>, EBPS, Naglaa M. Kamal, MS<sub>C</sub>, MD, Shazia J. Mirza, FCPS, EBPS, Laila M. Sherief, MS<sub>C</sub>, MD.

## ABSTRACT

بنادق الهواء تستخدم الهواء المضغوط أو غازات أخرى لدفع قذيفة. قد تحدث إصابات مختلفة في الأطفال نظرا لهيكل الجسم، وأن الأنسجة الرخوة أقل مقاومة ورقيقة ويمكن اختراقها بسهولة. نقدم هنا 3 حالات من الأطفال المصابين ببندقية الهواء أصيبوا بالرصاص من طفل من الأقارب. الحالة الأولى أصيبت برصاصة اخترقت الأنسجة العميقة لجدار البطن الأيمن دون اضرار بالأعضاء الداخلية، والحالة الثانية كان مسار الرصاصة معقد الى الحوض والحالة الثالثة أصيبت في الكتف الأيسر. و جميع الحالات أصيبت بطريق الخطأ. وكان الرماة أيضا أطفال. كانت حالة جميع المرضى بصفة عامة مستقرة عند وصولهم. تم عمل جراحة لحالتين وحالة تلت علاج تحفظي. مع المتابعة لم يلاحظ مضاعفات. للوهلة الأولى، قد تبدو بنادق الهواء والبنادق الهوائية غير مؤذية نسبيا لكنها في الواقع يمكن أن تكون مميتة لذلك لا ينبغي أن يسمح للأطفال للعب بها.

Air guns (AGs) use air or another compressed gas to propel a projectile. Different injuries may occur in children due to their body structure, which is less-resistant with thin soft tissue coverage that can be easily penetrated by an AG shot. We present 3 cases of pediatric AG shot injury. The first-case had right lumbar deep tissue penetration of AG pallet without internal damage, the second-case had a complex course of pellet into the perineum, and the third-case was shot in the left shoulder. All cases were accidentally shot. The shooters were all children, and relatives of the victims. All patients were generally stable on arrival. Two cases were operated, and one received conservative management. On follow up, no complications were noted. At first sight, AGs and air rifles may appear relatively harmless, but they are potentially lethal and children should not be allowed to play with them.

*Saudi Med J 2014; Vol. 35 (12): 1507-1509*

From the Pediatric Surgery Department (Khan, Mirza), Department of Pediatrics (Kamal), Al-Hada Armed Forces Hospital, Taif, Kingdom of Saudi Arabia, Department of Pediatrics (Kamal), Faculty of Medicine, Cairo University, Cairo, and the Department of Pediatrics (Sherief), Faculty of Medicine, Zagazig University, Zagazig, Egypt.

Received 21st May 2014. Accepted 13th October 2014.

Address correspondence and reprint request to: Dr. Naglaa M. Kamal, Associate Professor of Pediatrics and Pediatric Hepatology, Faculty of Medicine, Cairo University, Cairo, Egypt. E-mail: nagla.kamal@kasralainy.edu.eg

Air guns (AGs) are known for their use in sporting entertainment, and so inappropriate use of these weapons often leads to serious injuries.<sup>1</sup> In general, people think that trauma inflicted by air weapons is trivial. In fact, this is not true and the potential for serious and fatal injuries is significant.<sup>2</sup> Here, we report 3 cases of serious AG injury in children and review the relevant legislation covering the use of air weapons. Our objective is to highlight the problem in pediatric age group and raise awareness on its harm.

**Case Report. Patient One.** A 10-year-old male child was referred to our Pediatric Emergency Department (ER) with an accidental AG shot injury at the right lumbar region by his 11-year-old brother. The point of entry was at the right anterior lateral lumbar region. The entry site was a tiny spot, clean, with a reddish margin with no bleeding or swelling. He was clinically stable. His initial assessment revealed a pellet deep into the right side lumbar region. Plain x-ray and ultrasound were carried out the pellet was visualized penetrating in the tissues and muscles in the right lumbar region below the costal margin and anterior to the vertebral line (Figure 1). The pellet was removed under fluoroscopy from the deep muscle layers. He was followed up by both the pediatric, and pediatric surgery teams and was discharged home the next day in good condition with follow-up instructions.

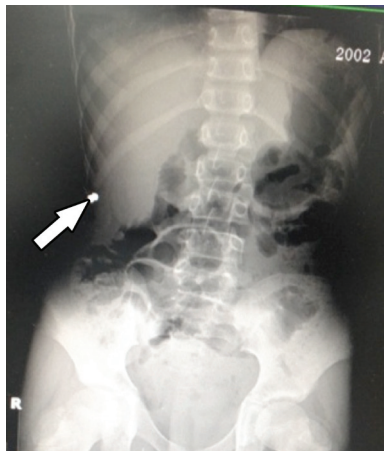**Patient 2.** A 3-year-old male child presented with AG shot injury in the right inguinal region. He was shot by his 12-year-old male relative. On assessment, he was generally stable with entry point of a pellet at the distal and lateral border of the right inguinal region with no other signs except the testis was palpable just above the point of entry (undescended testis on right side). The entry site was a tiny spot, clean, with reddish margins with no bleeding or swelling. Ultrasound, x-ray, and

CT scan were carried out (Figures 2A & 2B) and revealed undamaged testis in the right inguinal side and pellet impaction deep into the perineum near the inferior ramus of the pubic bone. Surgery was planned for 2 reasons; first to remove the pellet and second to explore the right inguinal region considering 2 possibilities; either to perform orchidopexy if the testis was not traumatized, or to manage accordingly if the testis was traumatized by the pellet. The surgery was then carried out under fluoroscopy, and the pellet was removed. Right side orchidopexy was carried out in the same setting as the testis was normal. He was followed up by the pediatric and pediatric surgery teams and he was discharged without any complications.

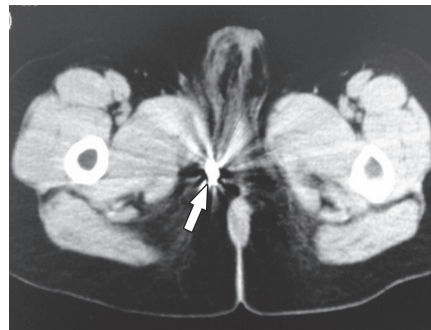
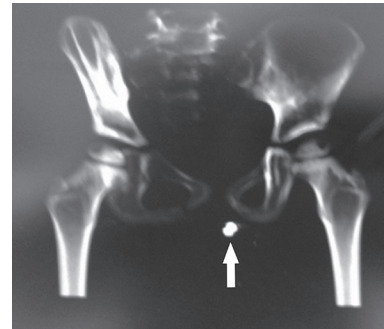
**Patient 3.** An 11-year-old male child was seen in the ER with an AG shot injury to the left shoulder accidentally shot by his 12-year-old brother from behind. He was in good condition. The entry point was at the postero-lateral upper part of the chest wall, which appeared as a clean tiny spot with a reddish margin with no bleeding or swelling. Plain x-ray showed a pellet deep in the muscles of the left side, near the surgical neck of the humerus (Figure 3). He was symptom free, so it was decided by both the pediatric and pediatric surgery teams to follow a conservative plan, keeping him under observation with follow up. He was discharged home in good condition without intervention.

**Discussion.** Air gun use started back since the time of the Napoleonic wars using the expanding force of compressed air (or gas) to propel a projectile.<sup>3</sup> The projectiles are usually lead pellets or ball bearings. Modern technology has increased the muzzle velocity and hence the penetrating power of these weapons. In

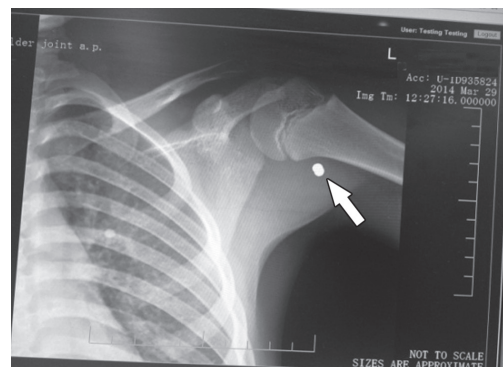
a review of experimental studies, DiMaio<sup>4</sup> concluded that the critical velocity for penetration of human skin by an AG pellet was between 38 and 70 m/sec (125±230 ft/sec). With the industrial revolution, their velocity has increased and many of them can now deliver muzzles with velocities similar to a conventional hand gun.<sup>5</sup> Although shooting another person or the person himself is usually accidental, injuries can be serious and even fatal,<sup>1,5</sup> with teenage boys being the usual victims;<sup>6</sup> and usually in the absence of adult supervision. Injuries to the child's eyes,<sup>7</sup> head, neck, and thorax have often



**Figure 1** - Patient 1. Plain x-ray showing a pellet in the right lumbar region.



**Figure 2** - Patient 2. Three dimensional x-ray image of the pelvic region showing an impacted pellet. B) Computerized tomography scan of the perineum showing a deeply impacted pellet.



**Figure 3** - Patient 3. Air gun pellet near the surgical neck of the left humerus.

been published, while injury to the genitourinary area was rarely reported.<sup>8</sup> Air guns are considered by many people as toys leading to increased incidents of AG injuries.<sup>9</sup>

In many countries, these instruments neither come under the purview of the Arms Act, nor is there is any restriction on the user's age. Most conventional air weapons do not require a license and children less than 14 years are allowed to use an air weapon.<sup>3</sup> Deaths have been reported in many studies due to fatal AG shots.<sup>10</sup> This enables children to gain access freely to them from homes or markets. Approximately 2-2.5 million non-powder firearms are sold annually, and nearly 12.9 per 100,000 population are treated for such injuries in the United States per year.<sup>6</sup>

Although only a few cases of AG injuries in the children and their severe impact on different sites were reported, we believe this is due to under reporting. We presented 3 cases from a single center from a single district in Saudi Arabia to highlight the issue and raise a red flag for the seriousness of AG use, especially by children. We believe that solving the issue of AG injuries requires integrated cooperation between the governments and their nations. Governments should issue strict laws, and regulations for AG use. A punishment hard enough to prevent people dealing with these weapons as toys should be issued to deter people from using these weapons and harming others even accidentally. The mass media should play their intended role in educating people and raising their awareness of AGs and their potential catastrophic sequelae. An actual and really important part is the self-sense of responsibility of people towards caring for the lives of others. Education, integration, and love are the golden keys to prevent humans from harming each other in every single aspect; one of these is AG injuries!

**Acknowledgment.** We would like to thank Dr. Talal A. Al-Malki, Dr. Kais Mazoun, and Dr. Mohamed F. Mirza, Consultants, Pediatric Surgery, Al-Hada Armed Forces Hospital, Taif, Saudi Arabia for their advisory help in the production of this study. Sincere appreciation for Dr. Abdulla O. Alharbi, Pediatric Consultant, Director of Pediatric Department, Al-Hada Armed Forces Hospital, Taif, Saudi Arabia, for his kind revision of this study.

## References

1. DeCou JM, Abrams RS, Miller RS, Touloukian RJ, Gauderer MW. Life-threatening air rifle injuries to the heart in three boys. *J Pediatr Surg* 2000; 35: 785-787.
2. Wightman G, Cochrane R, Gray RA, Linton M. A contribution to the discussion on the safety of air weapons. *Sci Justice* 2013; 53: 343-349.
3. Ghouri M. Air gun injuries: a growing problem in the UK. *Br J Hosp Med (Lond)* 2008; 69: 417.
4. DiMaio VJ. Penetration and perforation of skin by bullets and missiles. A review of the literature. *Am J Forensic Med Pathol* 1981; 2: 107-110.
5. Milroy CM, Clark JC, Carter N, Ruddy G, Rooney N. Air weapon fatalities. *J Clin Pathol* 1998; 51: 525-529.
6. Harris W, Luteran A, Curreri PW. BB and pellet guns--toys or deadly weapons? *J Trauma* 1983; 23: 566-569.
7. Navarro-Mingorance A, Reyes-Dominguez SB, León-León MC. Pediatric orbital emphysema caused by a compressed-air pistol shot: A case report. *Arch Soc Esp Oftalmol* 2014; 89: 373-375.
8. Girón-Vallejo O, Zambudio G, Ruiz-Pruneda R, Hernández JP, Ruiz-Jiménez JL. [Management of penile trauma from compressed air gun in a child]. *Cir Pediatr* 2011; 24: 65-67.
9. Stankov A, Jakovski Z, Pavlovski G, Muric N, Dwork AJ, Cakar Z. Air gun injury with deadly aftermath--case report. *Leg Med (Tokyo)* 2013; 15: 35-37.
10. O'Neill PJ, Lumpkin MF, Clapp B, Kopelman TR, Matthews MR, Cox JC, et al. Significant pediatric morbidity and mortality from intracranial ballistic injuries caused by nonpowder gunshot wounds. A case series. *Pediatr Neurosurg* 2009; 45: 205-209.

## Ethical Consent

All manuscripts reporting the results of experimental investigations involving human subjects should include a statement confirming that informed consent was obtained from each subject or subject's guardian, after receiving approval of the experimental protocol by a local human ethics committee, or institutional review board. When reporting experiments on animals, authors should indicate whether the institutional and national guide for the care and use of laboratory animals was followed.