

Ventricular tachycardia an atypical presentation of Ebstein's disease

Gabriel E. Baztarrica, MD, Gastón G. Sereno, MD, Sebastián A. Villecco, MD, Rafael Porcile, MD.

ABSTRACT

يعد شذوذ إيبشتاين هو تشوه خلقي نادر يتميز بانزياح قمي وخلع في الوريقة الحاجزية للصمام ثلاثي الشرفات والذي ينشأ من البطين الأيمن لتسوية دوره. ويشمل هذا تشوه تشوهات التوصيل الكهربائي وعدم انتظام ضربات البطين والقلب يعد نادراً جداً. نستعرض هنا حالة مريض يبلغ من العمر 22 عاماً والذي عرض مع دوخة وخفقان. أظهر المخطط الكهربائي للقلب عدم انتظام دقات القلب للبطين الأحادي بشكل متواصل. يعد ظهور المرض مع عدم انتظام دقات القلب البطيني المرتبط بعدم استقرار الدورة الدموية نادراً للغاية. كما أن التشخيص المؤكد EA، SMVT، وضعف البطين الأيمن الانقباضي، وضعف مزيل الزرع الجراحي للرجفان القلبي.

Ebstein's anomaly (EA) is a rare congenital malformation, characterized by an apical displacement and dysplasia of the septal leaflet of the tricuspid valve with a right ventricular atrialization compromising its function. This malformation includes electrical conduction abnormalities, and very rarely ventricular arrhythmias. We report the case of a 22-year-old male, presenting with dizziness and palpitations. The electrocardiogram showed a sustained monomorphic ventricular tachycardia (SMVT). The presentation of the disease with ventricular tachycardia associated with hemodynamic instability is extremely rare. We placed a surgical implantable cardiac defibrillator when the diagnosis of EA, SMVT, and right ventricular systolic impairment was confirmed.

Saudi Med J 2014; Vol. 35 (12): 1510-1512

From the Department of Cardiology and Physiology, Faculty of Medicine, Universidad Abierta Interamericana, Buenos Aires, Argentina.

Received 18th July 2014. Accepted 22nd September 2014.

Address correspondence and reprint request to: Dr. Gabriel E. Baztarrica, Department of Cardiology and Physiology, Faculty of Medicine, Universidad Abierta Interamericana, Buenos Aires, Argentina. E-mail: gpbaztarrica@yahoo.com

Ebstein's anomaly (EA) is a rare congenital malformation, characterized by an apical displacement and dysplasia of the septal leaflet of the tricuspid valve with a right ventricular atrialization compromising its function.¹ This malformation includes electrical conduction abnormalities and supraventricular arrhythmias. The cases of EA and ventricular tachycardia reported in the literature are few. The objective in presenting this particular case is to review the EA and the management of ventricular tachyarrhythmias.

Case Report. We report the case of a 22-year-old male, presenting with dizziness and palpitations during physical activity. The electrocardiogram (ECG) showed a QRS regular tachycardia with a heart rate of 200 per minute, with positive Brugada's algorithm (absence of an R/S complex in all precordial leads) and Verecke's algorithm in lead aVR (presence of an initial R wave) for sustained monomorphic ventricular tachycardia (SMVT) (Figure 1). The SMVT patient required electrical cardioversion (CVE) due to hemodynamic instability. His history included a syncope-like episode without a prodrome a year earlier. The ECG reported low tricuspid valve implantation (28 mm from the mitral valve), RV with moderate systolic function, and a 40 cm² right atrium (RA) with severe tricuspid valve regurgitation (Figure 2A). Magnetic resonance imaging was performed as EA was suspected and showed a severe dilatation of the RA and the vena cava system, RV with severely depressed systolic function, abnormal implantation of septal leaflet of the tricuspid valve with atrialization of the right ventricular (RV) inflow, and an interatrial septum without visible defects (Figure 2B). As the diagnosis of EA confirmed, and due to SMVT and right ventricular systolic impairment, a surgical

Disclosure. Authors have no conflict of interests, and the work was not supported or funded by any drug company.

implantable cardiac defibrillator (ICD) was placed, as a measure of secondary prevention.

He continued to be clinically stable with no report of ICD electrical therapy up to date. He is currently being followed-up by the congenital heart disease services and cardiovascular surgery for surgical evaluation (surgical repair or replacement of the tricuspid valve).

Discussion. According to case series, the incidence of EA occurs in 1-5 of 200,000 live births and constitutes less than 1% of congenital disorders.^{1,2} More than 50% of patients have a shunt at the atrial level with either a patent foramen ovale or secundum atrial septal defect, accessory conduction pathways, increasing the risk of atrial tachycardias (approximately 25%), ventricular septal defect, and right ventricular outflow tract obstruction, among others.¹ The clinical presentation ranges from no symptoms to patients

with dyspnea, poor exercise tolerance, chest pain, and palpitations among others. On physical examination, one might find signs of right heart failure, splitting of the first sound, right third sound, and a tricuspid regurgitation murmur. The ECG is valuable in the diagnosis of EA. Right or left atrial enlargement is common. The QRS duration is usually prolonged, with a right bundle-branch block pattern. Accessory pathways may be present, usually via a right bypass tract. Supraventricular arrhythmias are more common than ventricular.¹

Echocardiography remains the “gold standard” test for diagnosis. The main findings correspond to the apical displacement of the septal leaflet or tricuspid posterior of 8 mm/m² or more, with an anterior leaflet with an elongated appearance.³ The cardiac magnetic resonance (CMR) has become increasingly important in patients with EA, either to supplement

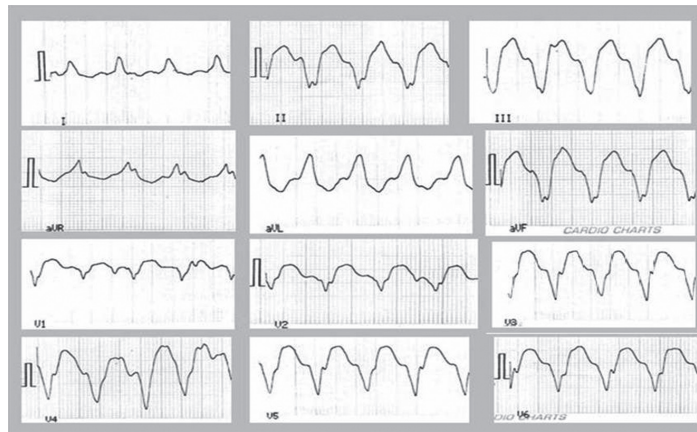


Figure 1 - Twelve lead electrocardiogram showing the sustained monomorphic ventricular tachycardia.

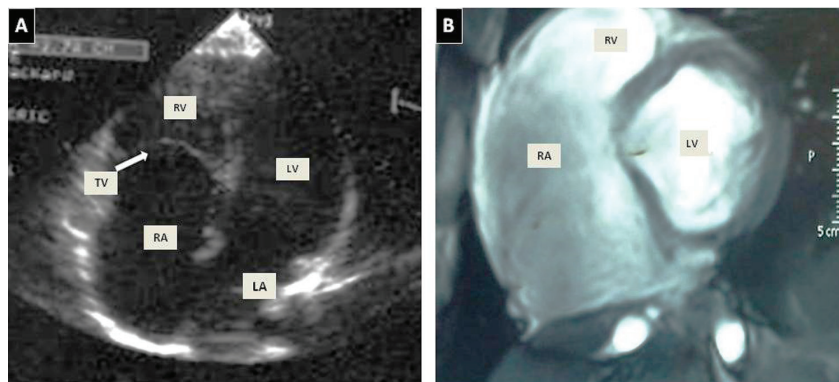


Figure 2 - Images showing the A) transthoracic echocardiogram of the low implantation of the TV and RV atrialization was visualized in a 4-chamber view. B) Vectographic image using MR showed extensive RA dilatation (53 x 103 mm) with atrialization of the RV inflow tract and showed the TV with abnormal apical implantation of the septal leaflet (31 mm). MR - magnetic resonance, RA - right atrium, TV - tricuspid valve, LA - left atrium, RV - right ventricle, LV - left ventricle.

or confirm echocardiographic findings. Our case was asymptomatic (performed physical activity 3 times a week) until the episode of ventricular tachycardia with hemodynamic instability occurred. The diagnosis of structural heart disease was made by clinical evaluation and the diagnosis of EA was confirmed based on the ECG findings using MRI. Current literature reveals that the incidence of ventricular arrhythmias in young patients with EA is 15%, and is associated with sudden death.³ Furthermore, 4% of ICD implants in patient with congenital heart disease were in those with EA.⁴

Although reports of ablation for VT in adults with congenital heart disease (ACHD) patients are still limited to small series, the risk of VT recurrence after ablation is now being more clearly defined and may exceed 20%. Perhaps a more important role for catheter ablation may be as supplemental therapy to reduce the shock burden in patients with frequent VR recurrences who already have an ICD in place.¹ In our case, ICD implantation was based on the recommendations for secondary prevention.⁵

In conclusion, EA comprises a rare complex congenital malformation with anatomical and hemodynamic associations; transthoracic ECG remains the "gold standard" for diagnosis. The presentation of the disease with ventricular tachycardia associated with hemodynamic instability was extremely rare. Considering the background and the presence of SMTV associated with hemodynamic instability, ICD implantation was an indicated therapy.

References

1. Warnes CA, Williams RG, Bashore TM, Child JS, Connolly HM, Dearani JA, et al. ACC/AHA 2008 Guidelines for the Management of Adults With Congenital Heart Disease: A Report of the American College of Cardiology/American Heart Association Task Force on Practice Guidelines (Writing Committee to Develop Guidelines on the Management of Adults with Congenital Heart Disease) Developed in Collaboration with the American Society of Echocardiography, Heart Rhythm Society, International Society for Adult Congenital Heart Disease, Society for Cardiovascular Angiography and Interventions, and Society of Thoracic Surgeons. *J Am Coll Cardiol* 2008; 52: e143-e263.
2. Qadi AM, Hamadah HK, Jijeh AM, Hijazi OM, Kabbani MS. Ebstein cardiac anomaly, functional pulmonary atresia and isovaleric acidemia: A case report. *J Saudi Heart Assoc* 2014; 26: 170-173.
3. Attenhofer Jost CH, Connolly HM, Edwards WD, Hayes D, Warnes CA, Danielson GK. Ebstein's anomaly - review of a multifaceted congenital cardiac condition. *Swiss Med Wkly* 2005; 135: 269-281.
4. Khanna AD, Warnes CA, Phillips SD, Lin G, Brady PA. Single-center experience with implantable cardioverter-defibrillators in adults with complex congenital heart disease. *Am J Cardiol* 2011; 108: 729-734.
5. Baumgartner H, Bonhoeffer P, De Groot N, Haan F, Deanfield J, Galie N, et al. ESC Guidelines for the Management of Grown-up Congenital Heart Disease (New Version 2010). *Rev Esp Cardiol* 2010; 63: e1-e59.

Related Articles

Rahman GA, Al Haizaey AH, Al-Soudi AD. Cardiac arrest as a result of ventricular tachycardia in a trauma patient. *Saudi Med J* 2011; 32: 525-527.

Vahedian J, Sadeghpour A. Arterial homograft and medical therapy in pseudoaneurysm of infrarenal aorta concomitant with recurrent right ventricular thrombus in Behcet's disease. *Saudi Med J* 2006; 27: 1401-1403.