

# Delayed presentation of Morel-Lavallée lesion

Javed Jameel, MBBS, MSOrth, Sandeep Kumar, MSOrth, MChOrth, Mohd Zabid, MBBS, MSOrth, Sohail Ahmad, MBBS, MSOrth.

## ABSTRACT

أفات لحب الجلدية المغلقة للإطراف غير شائعة، ويمكن أن يغيب التشخيص في حال تعرض المريض لصدمة حادة، وذلك لإرتباطها بكسور الحوض ويمكن حدوثها في غياب أي إصابة عظمية. عندما يحدث لحب الداخلي المغلق على المدور الكبير كما هو معروف بأفة موريل-أفالي نقوم برفع تقرير عن حالة تأخر ظهور آفة موريل أفالي التي تم التعامل معها بنجاح عن طريق إستعمال الإنضار / أو الصادات، والحشوة، و تأخير الإغلاق.

Closed degloving skin lesions of the limbs are uncommon, and diagnosis may be missed at the time of acute trauma. Usually, they are associated with pelvic fractures but may occur in absence of any bony injury. When this closed internal degloving occurs over the greater trochanter, it is known as a Morel-Lavallée lesion. We report a case of unusually delayed presentation of Morel-Lavallée lesion treated successfully by debridement, packing, and delayed closure.

*Saudi Med J 2014; Vol. 35 (7): 750-752*

*From the Department of Orthopedic Surgery (Jameel, Kumar), Hamdard Institute of Medical Sciences and Research, Jamia Hamdard, New Delhi, and the Department of Orthopedic Surgery (Zabid, Ahmad), Jawaharlal Nehru Medical College, Aligarh Muslim University, Aligarh, India.*

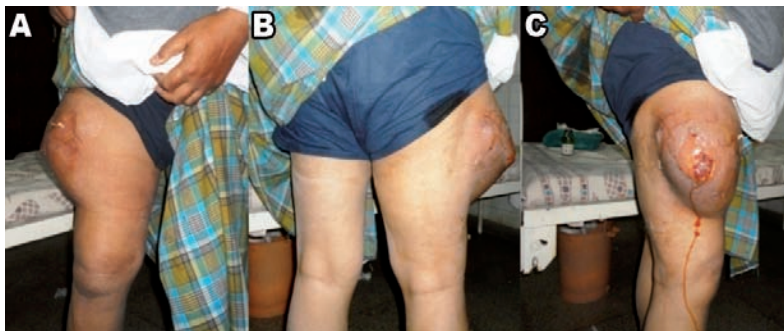*Received 12th January 2014. Accepted 15th May 2014.*

*Address correspondence and re-print request to: Dr. Javed Jameel, Assistant Professor, Department of Orthopedic Surgery, Hamdard Institute of Medical Sciences and Research, Jamia Hamdard, New Delhi 110062, India. E-mail: drjavedjameel@gmail.com*

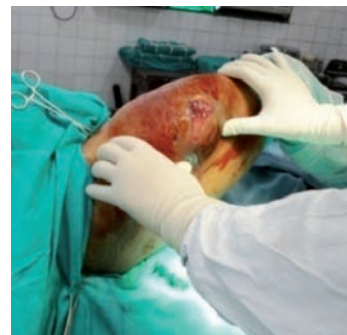**Disclosure.** Authors have no conflict of interests, and the work was not supported or funded by any drug company.

Closed degloving skin lesions of the limbs are uncommon and diagnosis may be missed at the time of acute trauma. Usually, they are associated with pelvic fractures, but may occur in absence of any bony injury.<sup>1</sup> When this closed internal degloving occurs over the greater trochanter, it is known as a Morel-Lavallée lesion.<sup>2</sup> It frequently appears as a fluctuating fluid accumulation around the pelvic girdle and greater trochanter. Most cases occur above large muscular surfaces due to excessive shearing causing the compartments of the subcutaneous fat to burst open with rupture of the septae that anchor the skin and superficial fascia. A cavity forms with migration of fat and continuous drainage of blood and lymph from interrupted capillaries, resulting in stasis and eventual encapsulation by fibrous connection or granulation tissue to form a pseudocyst. Our objective in presenting this particular case is to highlight the delayed presentation of Morel-Lavallée lesion, and its management by open debridement, packing, and delayed closure.

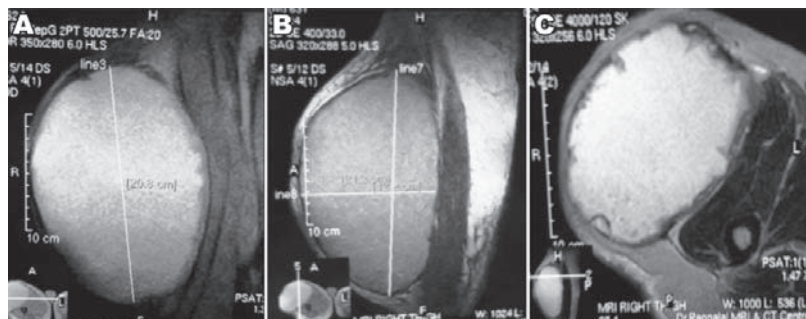
**Case Report.** A 66-year-old man was referred to the Orthopedic clinic with swelling over the upper and outer aspect of the right thigh and trochanteric region following blunt trauma 25 years back. He sustained an injury when the front tyre of a high-speed motorbike rammed over his right thigh from the side. The accident caused no major injury, but a few weeks later progressive, painless, swelling developed over his right upper thigh and trochanteric region. He managed to do all his routine daily activities without much discomfort. The swelling was aspirated 4 times in the past but every time it recurred. Examination revealed a huge swelling located over the antero-lateral aspect of right thigh and greater trochanter (Figures 1A-C), which was warm, non-tender, fluctuant with an ulcer at its apex discharging serous fluid (Figure 2). Blood investigations showed normal leucocytes count and C-reactive protein. Ultrasonography and MRI scan of the swelling were carried out, which revealed a cystic lesion (21 x 18 x 12 cms size) in the subcutaneous plane with a compressive effect on the vastus lateralis and tensor fascia latae (Figure 3A-C). Fine needle aspiration



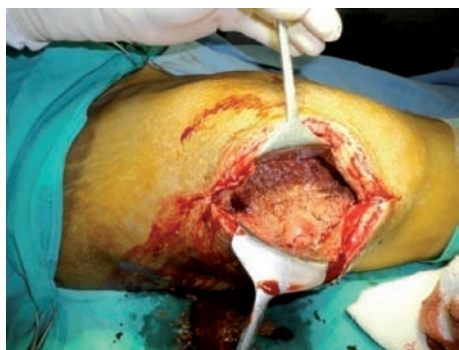**Figure 1** - Images showing: A) front; B) back; and C) side view swelling over the anterolateral aspect of the right thigh.



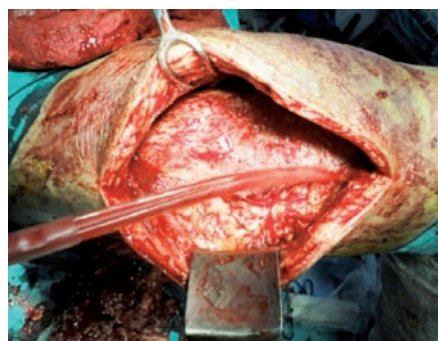**Figure 2** - Manual compression showing cystic nature of swelling.



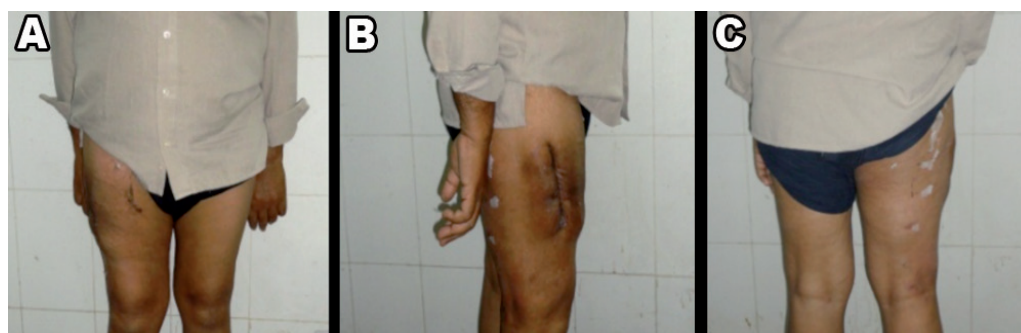**Figure 3** - An MRI scan showing: A) horizontal B) vertical; and C) oblique cuts of cystic lesion in subcutaneous plane of thigh.



**Figure 4** - Necrotic fat visible inside the subcutaneous space.



**Figure 5** - Wound debridement with fresh bleeding surface.



**Figure 6** - Images showing near normal contour: A) front; B) side; and C) back of the thigh 6 weeks after surgery.

cytology was carried out, which was suggestive of acute inflammatory exudate and the culture yielded no growth. He was planned for debridement, packing, and delayed closure of the wound.

**Surgical procedure.** With the patient supine under regional anesthesia, a 15 cm long linear skin incision was made over the lateral aspect of the thigh at the posterior margin of the swelling. Drainage of around 3 litres of hemorrhagic fluid, clotted hematoma, and subcutaneous fat was carried out through the subcutaneous space (Figure 4). The fascial compartment and underlying muscles were intact. Debridement of all dead and necrotic tissue was carried out followed by thorough curettage and pulse lavage (Figure 5). Excision of redundant skin and subcutaneous fat was carried out followed by packing of the wound with 3 sterile mops and pressure bandaging over the thigh. After surgery intravenous antibiotics were given for 3 days followed by oral for one week. Repeated cultures showed no growth. The dressing was changed every third day and gradual shrinkage in the size of the wound was noticed. Initially, 3 mops were used for packing the wound, the number of which was reduced gradually. A total of 7 dressings were carried out. Delayed primary closure of the wound was carried out at 3 weeks without insertion of drainage when there was granulation tissue appearing from within and no sliding movement of skin over the lesion. The wound healed gradually over the next 4 weeks, and he expressed satisfaction with the results (Figures 6A-C).

Informed consent was taken from the patient prior to operation and for inclusion in this report.

**Discussion.** Closed internal degloving is often caused by severe trauma resulting in tearing of subcutaneous tissues from underlying fascia, and thus creating a cavity filled with hematoma and liquefied fat. Our patient had unusual delayed presentation, massive swelling along with complications like, skin necrosis and ulceration, hence open debridement, and delayed closure was the only option left, but fortunately it worked in our patient. Different treatment modalities of closed degloving wounds were reported in the literature. While some authors achieved healing in 6 weeks by advocated compressive bandaging or

corsets,<sup>3</sup> others advocated percutaneous double incision drainage with debridement, irrigation, and suction drainage in early cases.<sup>4</sup> More invasive methods such as open debridement from a small incision followed by compressive bandaging were also advocated since the accumulated fluid was found to be infected initially by some authors,<sup>1,2</sup> while others managed with surgical drainage and use of synthetic glue and reported healing in 5 weeks.<sup>5</sup> Injection of sclerosing substances or internal drainage with surgical fascial fenestration was also reported in the management of closed degloving skin lesions.<sup>6,7</sup> Some authors recommended vacuum assisted closure (VAC therapy) of non-healing wounds, which requires repeated debridement, and achieved good results.<sup>8</sup>

We conclude that open debridement, packing, and delayed closure is one of the treatment options in complicated delayed presented Morel-Lavallée lesions.

**Acknowledgment.** We acknowledge Dr. Pannalal, MD, Radiology for reporting the MRI of patient to its clarity and correctness.

## References

- Hudson DA, Knottenbelt JD, Krige JE. Closed degloving injuries: results following conservative surgery. *Plast Reconstr Surg* 1992; 89: 853-855.
- Hak DJ, Olson SA, Matta JM. Diagnosis and management of closed internal degloving injuries associated with pelvic and acetabular fractures: the Morel-Lavallée lesion. *J Trauma* 1997; 42: 1046-1051.
- Harma A, Inan M, Ertem K. [The Morel-Lavallée Lesion: a conservative approach to closed degloving injuries]. *Acta Orthop Traumatol Turc* 2004; 38: 270-273. Turkish
- Tseng S, Tornetta P 3rd. Percutaneous Management of Morel-Lavallee Lesions. *J Bone Joint Surg Am* 2006; 88: 92-96.
- Demirel M, Dereboy F, Ozturk A, Turhan E, Yazar T. Morel-Lavallee lesion. *Results of surgical drainage with the use of synthetic glue. Saudi Med J* 2007; 28: 65-67.
- Kottmeier SA, Wilson SC, Born CT, Hanks GA, Iannacone WM, DeLong WG. Surgical management of soft tissue lesions associated with pelvic ring injury. *Clin Orthop Relat Res* 1996; (329): 46-53.
- Ronceray J. [Active drainage by partial aponeurotic resection of Morel-Lavallée effusions]. *Nouv Presse Med* 1976; 5: 1305-1306. French
- Steiner CL, Trentz O, Labler L. Management of Morel-Lavallee Lesion Associated with Pelvic and/or Acetabular Fractures. *European Journal of Trauma and Emergency Surgery* 2008; 6: 554-560.