

# Clinical Image

Submitted by: Min Yang, MD, Bo-Le Tian, PhD, An-Ping Su, MD, Yi Zhang, MD.

From the Department of Hepato-Bilio-Pancreatic Surgery, West China Hospital of Sichuan University,  
Chengdu, Sichuan Province, People's Republic of China.

Address correspondence to: Dr. Bo-Le Tian, Department of Hepato-Bilio-Pancreatic Surgery, West China Hospital of Sichuan University,  
Guoxue Road No. 37, Wuhou Chengdu, Sichuan Province, People's Republic of China. E-mail: yangmin870710@sina.com.cn

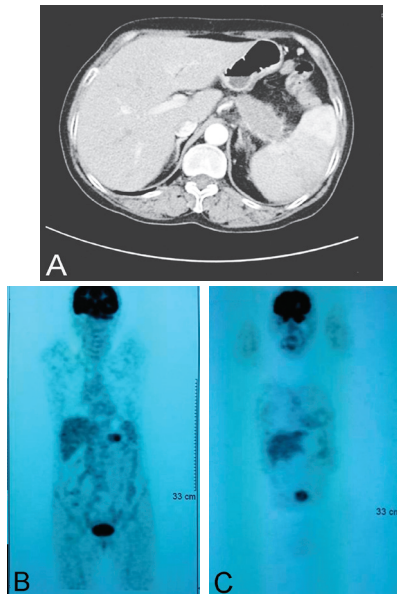
**Notice:** Authors are encouraged to submit quizzes for possible publication in the Journal. These may be in any specialty, and should approximately follow the format used here (maximum of 2 figures). Please address any submissions to: Editor, Saudi Medical Journal, Armed Forces Hospital, PO Box 7897, Riyadh 11159, Kingdom of Saudi Arabia. Tel. +966 (1) 4777714 Ext. 6570. Fax. +966 (1) 4761810 or 4777194.

## Umbilical neoplasm as the first sign of pancreatic adenocarcinoma

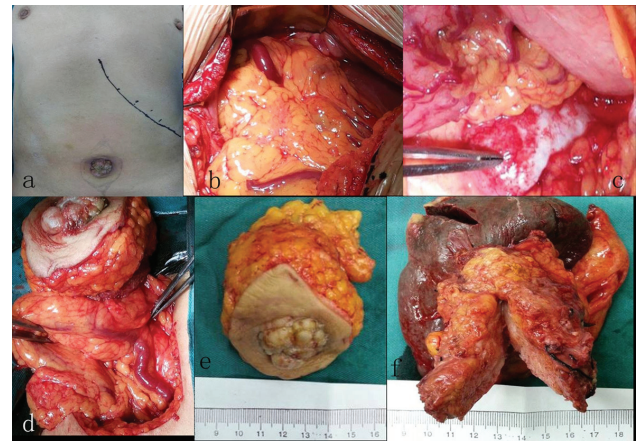
### Clinical Presentation

Advanced pancreatic cancer may readily exhibit local, or systemic metastasis through direct invasion, via the circulatory or lymphatic system through planting, and so forth.<sup>1</sup> Beside the common metastatic sites (such as, liver, peritoneum, lung, bone, brain, and others), relatively rare metastases to the heart, muscle, skin, appendix, and other organs have also been reported.<sup>2-4</sup> In the current study, based on the case of pancreatic carcinoma with umbilical metastasis in our hospital, we reviewed related literature and discuss the possible transfer mechanisms, aiming at improving the clinician understanding of this rare clinical phenomenon, and benefit patient from timely treatment.

A 58-year-old female patient was admitted into our hospital with a main complaint of umbilical discomfort 10 months ago, and a finding of an umbilical neoplasm 4 months ago. Ten months prior to hospital admission, the discomforting symptoms were slightly relieved after anti-inflammatory and symptomatic treatments by local doctors. The patient did not pay a considerable amount of attention to that until 4 months prior to hospitalization, when she discovered a neoplasm in the umbilicus. A biopsy of her umbilical mass at our hospital hinted a poorly differentiated adenocarcinoma, probably originating from the gastrointestinal tract. After admission, her tumor markers: carcinoembryonic antigen (CEA) (5.69 U/mL, normal range: <5 U/mL); carbohydrate antigen 199 (CA-199) (84.18 U/mL, normal range: <37 U/mL); and CA-125 (75.67 U/mL, normal range: <50 U/mL) exceeded the normal range slightly. The abdominal contrast-enhanced CT scan detected a low-density area in the pancreatic body and tail, approximately 5.5×2.7 cm<sup>2</sup> in size (**Figure 1A**). The positron emission tomography-CT (PET-CT) scan in the hospital also showed a mass in the pancreatic body and tail with a maximum standardized uptake value (SUV) of 4.69 (normal range: <2.0) (**Figure 1B**), and an umbilical mass with a maximum SUV of 4.1 (**Figure 1C**). Afterwards, an exploratory laparotomy was arranged for this patient, in which a cauliflower-like exogenous mass with a diameter of approximately 4 cm was found in the patient's umbilicus (**Figures 2A, 2E**); the greater omentum was firmly adhered to the abdominal wall, with a number of expanded veins (**Figure 2B-2D**). The tumor was located in the pancreatic body and tail (**Figure 2F**). Surgical procedures of "body and tail of the pancreas resection + splenectomy + umbilical mass resection" were successfully performed. The postoperative pathological examinations of the resected tissues showed: a poorly differentiated adenocarcinoma of the pancreas with visible intravascular thrombus; spread of cancer to the splenic vein; a pancreatic resection margin without the involvement of cancer cells; a poorly differentiated adenocarcinoma of umbilicus that is morphologically consistent with pancreatic tumor.



**Figure 1** - Images showing: A) low-density area, approximately 5.5×2.7 cm<sup>2</sup> in size in the pancreatic body and tail. The splenic vein was clearly invaded by the tumor; B) increased fluorodeoxyglucose uptake in the pancreatic body and tail; and C) in the umbilicus.



**Figure 2** - Images showing: A) cauliflower-like and exogenous neoplasm in the umbilicus; B & C) numerous expansive blood vessels in the abdominal cavity; D) Dense adhesion of the abdominal wall inside the umbilical tumor to the greater omentum, on which a number of expanded, tortuous veins were found; E) Umbilical neoplasm approximately 4 cm in diameter; F) pancreatic cancer approximately 5.5 cm in size, which had a close relationship with the spleen.

## Questions

1. What is the likely diagnosis?
2. What are the possible reasons of this phenomenon?
3. What is the management? Why?

## Answers

1. The patient has neoplasm in umbilicus, which was firstly misdiagnosed as inflammatory mass by the local doctors, until a biopsy of her umbilical mass hinted a poorly differentiated adenocarcinoma probably originating from the gastrointestinal tract. The imaging examinations of our hospital highly suspected pancreatic malignancy with umbilical metastasis, which was finally confirmed by the postoperative pathological examinations.
2. Advanced pancreatic cancer can readily undergo local or systemic metastasis through direct invasion, via the circulatory or lymphatic system, through planting, and others.<sup>1</sup> Umbilical metastasis from the pancreas possibly occurs through one or more of these processes, which has been reported before.<sup>5,6</sup> In our case, based on the intraoperative findings, we speculated that the dense adhesion of the greater omentum to the abdominal wall might cause the umbilicus to be directly adjacent to numerous expansive vessels. Moreover, the pancreatic segmental portal hypertension might result the reopening of some veins (such as the umbilical venous plexus), which had been partially, or totally blocked before, eventually leading to the transfer of pancreatic tumor cells to the umbilicus along these blood vessels.

# Clinical Image

3. An exploratory laparotomy was arranged for this patient. Although umbilical metastasis from pancreatic carcinoma was diagnosed before the operation was performed, no other distant metastases in the liver, lung, bone, and so forth was observed from the preoperative imaging examinations. Also, the patient was in relatively good physical condition, and her family members insisted on surgical treatment, which supported our decisions most. Meanwhile, we found intraoperatively that both the metastasis of the umbilicus and pancreatic tumors were resectable.

## Discussion

Umbilical metastasis from abdominal and pelvic malignancies remained poorly understood until a nurse, Sister Mary Joseph (1856 to 1939) from the Mayo Clinic (Rochester, USA) conducted a systematic clinical observation between umbilicus mass and visceral malignancies. Thereafter, the umbilical tumor originating from the abdominal and pelvic malignancies was called Sister Mary Joseph's nodule (SMJN), which was primarily adenocarcinoma that often originated from the stomach, colon, rectum, pancreas, uterus, and others. The SMJN from pancreatic carcinoma accounted for approximately 7-9% of all cases, and approximately 90% of these tumors originated from the pancreatic body and tail.

Advanced pancreatic cancer can readily undergo local or systemic metastasis through direct invasion, via the circulatory or lymphatic system, through planting, and others.<sup>1</sup> Umbilical metastasis from the pancreas possibly occurs through one or more of these processes. Crescentini et al<sup>5</sup> reported in 2004 that the lymphatic spread from the pancreatic body to the umbilicus could lead to umbilical involvement. In 2003, Takeuchi et al<sup>6</sup> who found that the umbilicus is the most frequent cutaneous metastatic site suggested that the circulatory and lymphatic systems were both involved in umbilical metastasis.

For our patient, the intraoperative findings (Figures 2B-2D) showed that the greater omentum was tightly connected to the umbilicus, with splenomegaly and many tortuous outspread veins. We then speculated that the pancreatic segmental portal hypertension might have occurred due to the long-term effects of the tumor on the pancreas and surrounding tissues. The dense adhesion of the greater omentum to the abdominal wall may have caused the umbilicus to be directly adjacent to numerous expansive vessels. Moreover, the portal hypertension might result the reopening of some veins (such as the umbilical venous plexus), which had already been partially or totally blocked before, eventually leading to the transfer of pancreatic tumor cells to the umbilicus along these blood vessels. Postoperative pathological diagnosis gave us the hint that tumor embolism occurred inside the splenic vein, strongly suggesting that metastasis may occurred through the circulatory system.

In conclusion, umbilical metastases of pancreatic cancer, or SMJN from pancreas are highly rare. It may occur through many approaches, which we speculate that the circulatory system might be the uppermost one. Raising the awareness of this clinical phenomenon could significantly benefit the patient's further treatment.

## References

1. Li D, Jiao L. Molecular epidemiology of pancreatic cancer. *Int J Gastrointest Cancer* 2003; 33: 3-14.
2. Borad MJ, Saadati H, Lakshmiathy A, Campbell E, Hopper P, Jameson G, et al. Skeletal metastases in pancreatic cancer: a retrospective study and review of the literature. *Yale J Biol Med* 2009; 82: 1-6.
3. Otegbayo JA, Oluswasola OA, Akere A, Yakubu A, Daramola OO, Ogun GO. Pancreatic carcinoma presenting as cutaneous nodules in a diabetic Nigerian male. *West Afr J Med* 2005; 24: 180.
4. Filik L, Ozdal-Kuran S, Cicek B, Zengin N, Ozyilkan O, Sahin B. Appendicular metastases from pancreatic adenocarcinoma. *Int J Gastrointest Cancer* 2003; 34: 55-58.
5. Crescentini F, Deutsch F, Sobrado CW, de Araújo S. Umbilical mass as the sole presenting sign of pancreatic cancer: a case report. *Rev Hosp Clín Fac Med* 2004; 59: 198-202.
6. Tacheuchi H, Kawano T, Toda T, Minamisono Y, Nagasaki S, Yao T, et al. Cutaneous metastasis from pancreatic adenocarcinoma: a case report and a review of the literature. *Hepatogastroenterology* 2003; 50: 275-277.