

Facial fistula

Long-term sequelae of a complicated exodontia

Nasser A. Alasseri, SBOMFS, MOMS RCPS (Glasg), Ahmad S. Assari, BDS.

ABSTRACT

الناصور الوجهي الجلدي هو أحد مضاعفات العدوى السنية المنشأ والتي غالباً ما يتم تشخيصها بالخطأ على أنها التهاب جلدي وبالتالي تعالج بطريقة خاطئة. نقدم تقرير لحالة ناسور وجهي حدثت بعد ثماني سنوات من خلع أحد الاسنان مع المظاهر السريرية والنتائج الأشعاعية وطريقة العلاج لها.

Facial cutaneous fistula is a complication of odontogenic infection that is often misdiagnosed with dermatological infection, and hence, mistreated. We report a case of facial fistula that developed 8 years following a dental extraction, presenting its clinical appearance, radiographical findings, and treatment approach.

Saudi Med J 2015; Vol. 36 (4): 490-493
doi: 10.15537/smj.2015.4.11702

From the Department of Oral and Maxillofacial Surgery (Alasseri), Prince Sultan Military Medical City, and the Department of Oral and Maxillofacial Surgery and Diagnostic Sciences (Assari), Riyadh Colleges of Dentistry and Pharmacy, Riyadh, Kingdom of Saudi Arabia.

Received 22nd December 2014. Accepted 4th January 2015.

Address correspondence and reprint request to: Dr. Nasser A. Alasseri, Consultant, Department of Oral and Maxillofacial Surgery, Prince Sultan Military Medical City, PO Box 240771, Riyadh 11322, Kingdom of Saudi Arabia. E-mail: dr.nasser.alasseri@gmail.com

Tooth extraction is a common procedure performed in dental clinics, and is generally considered safe. As with any procedure, complications are expected to rise during or after teeth extractions, these include; infection, dry socket, hemorrhage, and dysesthesia.¹ With the increasing number of surgical extractions, the frequency of complications is expected to increase. Fracture of the root tips during extraction is a frequent finding, in which sometimes the accessibility of the fractured fragment is difficult. It has been observed

that if these are not infected they can be left in the bone without any complications unless implants are considered as a treatment option.^{2,3} However, contaminated roots are considered a source of infection and commonly exacerbated to develop extraoral cutaneous fistula.⁴ These cutaneous lesions often present diagnostic challenges as the lesion may arise not in close proximity to the source of the infection, and therefore misdiagnosed and treated inappropriately.⁵⁻⁷ Our objective is to report a case of facial fistula that developed 8 years following a dental extraction, and to emphasize the importance of a thorough clinical examination prior to any treatment.

Case Report. A 42-year-old Saudi female patient, not known to have any chronic medical illness was referred to the Department of Oral and Maxillofacial Surgery in Prince Sultan Military Medical City, Riyadh, Saudi Arabia by a consultant dermatologist with a submandibular skin fistula, that was treated by antibiotic and local creams for 3 months with no improvement. Referral was to rule out an odontogenic cause. She was seen in the Oral and Maxillofacial Clinic complaining of recurrent pus discharge from her neck for the past 6 months with no history of dental pain. Examination showed an extraoral fistula in the left submandibular region with pus discharge upon palpation, intra oral examination showed no soft tissues abnormalities in the ipsilateral area with all molar teeth missing, panoramic radiograph showed a round radiolucent lesion in the left body of the mandible with presence of radiopaque foreign body inside the lesion resembling a remaining root (Figure 1). The cone beam computed tomography evaluation showed a 1x1 cm round radiolucent lesion causing displacement of the inferior alveolar canal medially with presence of an endodontically treated root inside the lesion (Figures 2 & 3). She mentioned later that she underwent teeth extraction on the same side 8 years earlier in a private dental clinic in Taif, and

was not informed of any intraoperative complications. Following patient consent and under general anesthesia a lateral cortical window was reflected through an intraoral approach; the remaining root was exposed then removed, and the surrounding infected tissue was excised completely with preservation of the inferior alveolar nerve that was dissected and preserved medially. The cortical window was fixed to the original place by a microplate (1.5 mm) to enhance the stabilisation of the bony segment (Figures 4 & 5). The fistula was traced and excised completely with elliptical excision and closed primarily (Figure 6). Postoperatively, she was cleared from the infection but had temporary hypoesthesia in the left cheek area, which fully recovered 3 weeks after surgery. No further complications were reported.

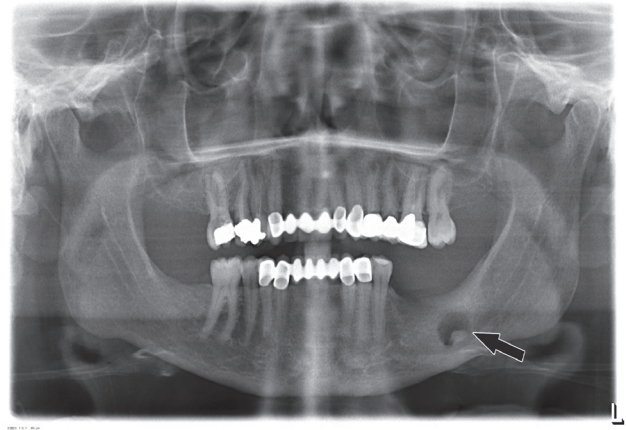


Figure 1 - Orthopantomogram showing the remaining root of the tooth extracted 8 years earlier and the fistula (arrow).

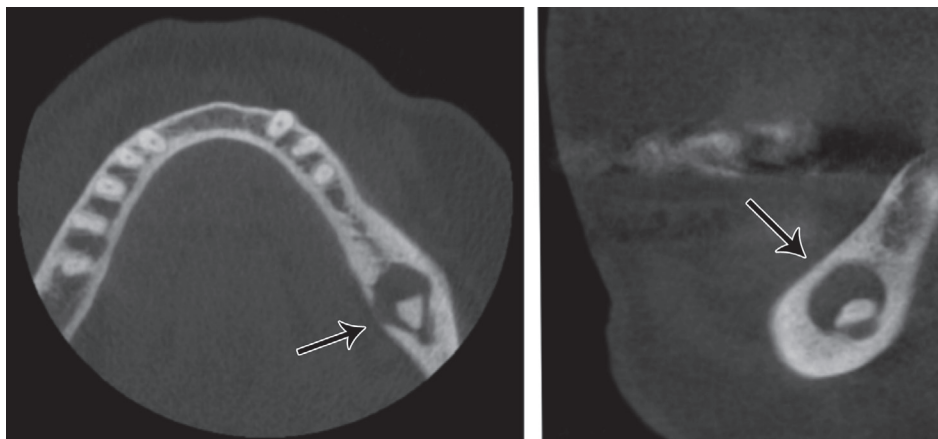


Figure 2 - Preoperative CT view showing: A) axial view, and B) curved view of the remaining root of the tooth extracted 8 years ago (arrows).

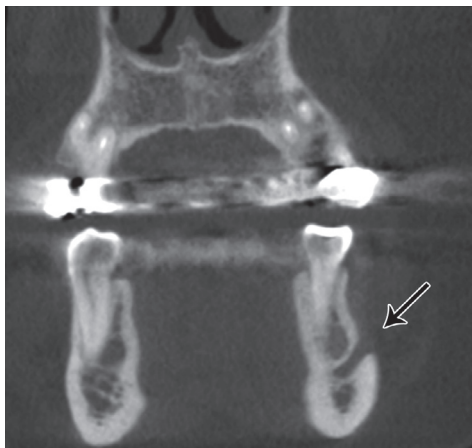

Figure 3 - Preoperative coronal view of the remaining root of the tooth extracted 8 years ago (arrow).

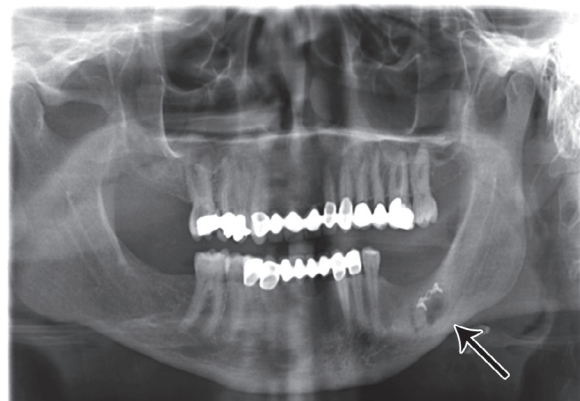


Figure 4 - Orthopantomogram post removal of remaining root and fixation of the cortical window (immediate postop) (arrow).

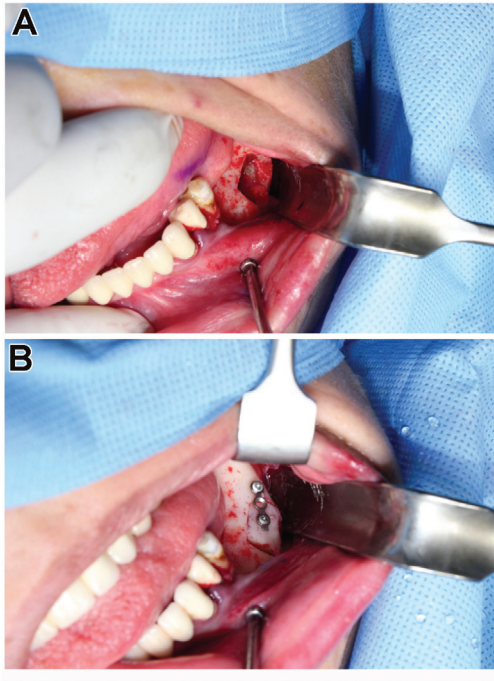


Figure 5 - Intraoral view of the cortical window showing: A) before, and B) after removal of the remaining root and fixation of the cortical window.

Discussion. Long-standing odontogenic infections have been implicated in the development of cutaneous fistulae, commonly manifested from an infected tooth. These conditions are frequently misdiagnosed by general practitioners; thus, patients receive the wrong treatments, and an exacerbation of the illness occurs. Patients also seek a dermatologist for skin lesions, with subsequent frequent misdiagnosis and inappropriate treatments methods.^{5,7-9} For facial lesions, history and physical examination of the oral cavity condition is critical. This should include intraoral examination and radiographs as it is common for an odontogenic infection to develop extraoral pathological symptoms, and physicians have to rule out any dental origin to achieve a better prognosis.¹⁰

This paper reports a long-term cutaneous fistula development as an exacerbation of an infected displaced remaining root; a rare complication following dental extractions. Oddly, there were no signs of infection intraorally, and the socket was completely healed. The patient remained asymptomatic for 8 years before developing the reported extraoral fistula, and radiographic evidence indicates a healing process with remodelling that took place after the tempted extraction. Edentulous areas should not be neglected

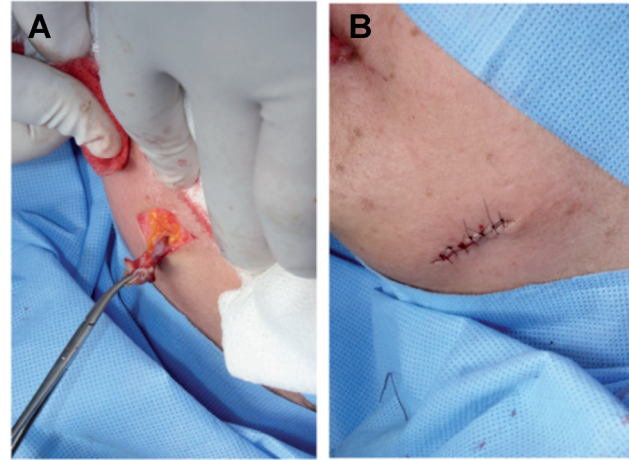


Figure 6 - Photograph showing: A) fistula traced and completely removed with elliptical excision, and B) suturing of the wound.

during intraoral examination, even when there are no signs of infection or abnormalities in the area. Our patient showed normal intraoral features with no apparent soft tissue abnormalities. It was not until the radiographs were taken that the presence of the infected root was confirmed.

In this case, the remaining root was removed through an intraoral approach with a crestal and distal releasing incision then a lateral cortical window was created and reflected inferiorly to maintain the lower part of the bone window partially attached to the underlying bone. The root was exposed and removed gently with preservation of the inferior alveolar nerve, and then the inflamed tissues around it was excised and removed completely. This approach provided ease of locating the root and minimizing the dissection through the facial layers, which provided better accessibility and minimal scarring, and vital structures injury. Contrary to protocol, the facial fistula was excised during the same procedure as it did not show any signs of active infection or any purulent discharge of any kind as the patient was already on systemic antibiotics.

In conclusion, although odontogenic facial fistulas most frequently arise from a decayed tooth with periapical infection, the possibility of a deep bony source should be considered, especially in edentulous areas such as in this case. We emphasize the importance of radiographic examination to rule out deep bony infection, which cannot be detected by clinical examination alone. Displaced roots may cause chronic infection, which could be manifested as facial fistula. When such complication occurs, detailed documentation should be

created regarding the incidence, and the patient should be informed of the current situation. Whenever there is a facial fistula, dentists or physicians should rule out an odontogenic source by obtaining a proper dental history, examination, and radiographic investigations to find the source of the infection. In complicated extractions, infected root fragments should be removed either on the same extraction visit or after referral to a specialist.

References

1. Pierse JE, Dym H, Clarkson E. Diagnosis and management of common post extraction complications. *Dent Clin North Am* 2012; 56: 294-312.
2. Lieblch SE, Kleiman MA, Zak MJ. Dentoalveolar surgery. *J Oral Maxillofac Surg* 2012; 70 (11 Suppl 3): e50-e71.
3. Yamashita DD, McAndrews JP. Complications in dentoalveolar surgery. *Oral Maxillofac Surg Clin North Am* 2011; 23.
4. Chkoura A, Elwady W, Taleb B. Surgical management of a cutaneous sinus tract: a case report and review of the literature. *J Contemp Dent Pract* 2010, 11: 49-55.
5. Rudagi K, Rudagi BM. Cutaneous Sinus Tract of Odontogenic origin a Misdiagnosed Lesion: Report of two Cases. *Acta Stomatologica Croatica* 2012; 46: 317-322.
6. Brown RS, Jones R, Feimster T, Sam FE. Cutaneous sinus tracts (or emerging sinus tracts) of odontogenic origin: a report of 3 cases. *Clin Cosmet Investig Dent* 2010; 2: 63-67.
7. Kishore Kumar RV, Devireddy SK, Gali RS, Chaithanyaa N, Chakravarthy C, Kumarvelu C. Cutaneous sinuses of cervicofacial region: a clinical study of 200 cases. *J Maxillofac Oral Surgery* 2012; 11: 411-415.
8. Sammut S, Malden N, Lopes V. Facial cutaneous sinuses of dental origin - a diagnostic challenge. *Br Dent J* 2013; 215: 555-558.
9. Hwang K, Kin CW, Lee SI. Cutaneous sinus tract from remaining tooth fragment of edentulous maxilla. *J Craniofac Surg* 2000; 11: 254-257.
10. Peermohamed S, Barber D, Kurwa H. Diagnostic challenges of cutaneous draining sinus tracts of odontogenic origin: a case report. *Dermatol Surg* 2011; 37: 1525-1527.

Related Articles

Almutairi TK, Albarakati SF, Aldrees AM. Influence of bimaxillary protrusion on the perception of smile esthetics. *Saudi Med J* 2015; 36: 87-93.

Batinjan G, Filipovic Zore I, Vuletic M, Rupic I. The use of ozone in the prevention of osteoradionecrosis of the jaw. *Saudi Med J* 2014; 35: 1260-1263.

Hassan AH, Turkistani AA, Hassan MH. Skeletal and dental characteristics of subjects with incompetent lips. *Saudi Med J* 2014; 35: 849-854.

Dayal P, Ahmed J, Ongole R, Boaz K. Solitary neurofibroma of the gingiva. *Saudi Med J* 2014; 35: 607-611.