

Gastroesophageal stenting for the management of post sleeve gastrectomy leak

A single institution experience

Noha Guzaiz, MD, Mohammad Arabi, MD, Azzam Khankan, MD, Refaat Salman, MD, Mohammed Al-Toki, MD, Shabbaz Qazi, MD, Abdulmohsin Alzakari, MD, Mohammad Al-Moaiqel, MD.

ABSTRACT

الأهداف: لتقييم فعالية دعامات المعدة لتسربات خط التيلة بعد تكميم المعدة باستخدام دعامات التوسيع القابلة للإزالة.

الطريقة: خلال الفترة من أبريل 2012م و يونيو 2015م، 12 مريض بالتوالي 6 ذكور معدل عمر 34 عام (38-21 عام) يعانون من تسربات خط التيلة 1-8 أسابيع بعد العملية (متوسط 2.8 أسبوع). خضع المرضى لدعامات المعدة باستخدام الأشعة العلاجية. استخدم عدد 23 دعامة متوسط الطول 17.8 سم (24-7 سم) ومتوسط القطر 25.6 ملم (36-18 ملم). كان هنالك حاجة في إعادة تثبيت الدعامة في 7 مرضى (9 عمليات)، بينما احتاج 6 مرضى لجمع التسرب عن طريق الجلد، واحتاج 3 مرضى إلى منظار حقن الغراء مع القطع. وكان 2 من إجراءات إزالة الدعامة التي نفذت تحت إجراء التصوير بالمنظار بعد فشل استخدام الدعامة تحت التنظير، في حين أن النسبة المتبقية تم إزالة الدعامة بنجاح بالأشعة التداخلية.

النتائج: كان تثبيت الدعامة ناجح من الناحية التقنية في جميع المرضى. ظهرت هجرة الدعامة في 6 مرضى (50). هناك ميل لهجرة الدعامة مع قصر طول الدعامة ($R=-0.557$, $p=0.008$). كان متوسط مدة الدعامة 60.5 يوم (137-14 يوم). خضع جميع المرضى لإزالة الدعامة واستؤنفت تناول عن طريق الفم مع عدم وجود تكرار تسرب حتى فترة المتابعة 190 يوم (410-14 يوم). وشملت مضاعفات الجهاز الهضمي النزيف ($n=1$)، تضيق المريء الداني ($n=1$) وانسداد الدعامة ($n=1$).

الخلاصة: تعد دعامات المعدة مقياس ابتدائي بعد التشخيص الأولي لتسرب المعدة بعد تكميمها لتقديم خيار بديل آمن وفعال لتفادي تكرار التدخلات الجراحية. قد لا يزال هناك حاجة للتدخلات التنظيرية للسيطرة على التسرب المستمر.

Objectives: To retrospectively evaluate the effectiveness of gastroesophageal stenting for post sleeve gastrectomy staple line leaks using removable self-expandable stents.

Methods: Between April 2012 and June 2015, 12 consecutive patients (6 males) with mean age of 34 years

(21-38 years) presented with staple line leak 1-8 weeks after the operation (mean 2.8 weeks). Patients underwent gastroesophageal stenting by interventional radiology. A total of 23 stents were deployed with mean length of 17.8 cm (7-24 cm) and mean diameter 25.6 mm (18-36 mm). Stent re-insertion was needed in 7 patients (9 procedure), while 6 patients required percutaneous collection drainage and 3 patients required endoscopic glue injection with clipping. Two stent removal procedures were carried out under endoscopic visualization after failed stent capture under fluoroscopy, while the remaining stents were successfully removed by interventional radiology.

Results: Stent placement was technically successful in all patients. Stent migration occurred in 6 patients (50%). There is a tendency for stent migration with shorter stent length ($R=-0.557$, $p=0.008$). The mean duration of stenting was 60.5 days (14-137 days). All patients underwent stent removal and resumed oral intake with no recurrence of leak at a mean follow up time of 190 days (14-410 days). Complications included gastrointestinal bleeding ($n=1$), proximal esophageal stricture ($n=1$) and stent occlusion ($n=1$).

Conclusion: Gastroesophageal stenting as a primary measure after diagnosis of early post sleeve gastrectomy leak appears to offer a safe and effective alternative option in obviating repeat surgical interventions. Minimally invasive interventions may still be required for the management of persistent leak.

*Saudi Med J 2016; Vol. 37 (12): 1339-1343
doi: 10.15537/smj.2016.12.15761*

From the Department of Medical Imaging (Guzaiz), King Abdulaziz Medical City, Makkah, the Departments of Medical Imaging (Guzaiz, Arabi, Khankan, Salman, Al-Toki, Qazi, Al-Moaiqel) and Surgery (Alzakari), King Abdulaziz Medical City, Riyadh, Kingdom of Saudi Arabia.

Received 11th July 2016. Accepted 4th September 2016.

Address correspondence and reprint request to: Dr. Mohammad Arabi, Consultant Interventional Radiologist, King Abdulaziz Medical City, Riyadh, Kingdom of Saudi Arabia. E-mail: marabi2004@hotmail.com

Post sleeve gastrectomy staple line leak occurs in approximately 1-5% of patients.¹⁻⁴ Several endoscopic and surgical interventions have been implemented in treatment of post sleeve gastrectomy leaks depending on the time of diagnosis, size of leak and the presence of peritonitis.^{2,3,5-7} Gastroesophageal stents provide a barrier between the gastric contents and the staple line leak facilitating gradual healing while allowing for resumption of oral intake. Existing stents in the market include covered self-expandable metallic stents, partially covered self-expandable metallic stents, and covered self-expanding plastic stents. The overall reported success rate ranges between 80-95% when used for 6-12 weeks.^{5,7,8} This minimally invasive procedure is traditionally carried out under endoscopic guidance after visualization of the leak. In this study, we report techniques and clinical outcomes of esophageal stent placement and retrieval by interventional radiology.

Methods. The Institutional Review Board approved this retrospective study and patient's consent form was waived. The inclusion criteria for this retrospective study were: a) patients who had sleeve gastrectomy complicated by post operative leak, b) patients who underwent esophageal stenting by interventional radiology. The exclusion criteria were: a) patients who were managed by surgical re-interventions, b) patients who underwent stenting by services other than interventional radiology, c) patients with missing clinical or imaging data, and d) patients who missed follow up.

Between April 2012 and June 2015, 12 consecutive patients (6 males) with a mean age of 34 years (21-38 years) were diagnosed with staple line leak 1-8 weeks after the operation (mean 2.8 weeks). No patients were excluded based on the exclusion criteria. Ten patients presented within 1-3 weeks after operation and 2 presented after 6 weeks. No patients were managed surgically prior to stent placement. Two patients were septic at the time of diagnosis. The remaining patients presented with chest infection (n=1) and upper abdominal pain associated with fever (n=9). Patients underwent gastroesophageal stenting by interventional radiology. A total of 23 fully covered self-expandable stents were deployed; PolyFlex[®] (Boston Scientific, Natick, MA, USA) (n=4); WallFlex[®] (Boston Scientific, Natick, MA, USA) (n=8); Hanarostent[®] (M.I.TECH, Gyeonggi-Do,

Korea) (n=3), Niti-S[™] (Taewoong Medical, Gyeonggi-Do, South Korea) (n=7); AliMaxx-ES (Alveolus[®] Inc., Charlotte, NC, USA) (n=1). The mean stent length was 17.8 cm (7-24 cm), and the mean diameter was 25.6 mm (18-30 mm).

Placement and retrieval procedures were preferably carried out under general anesthesia with nasotracheal, or orotracheal intubation. After cannulation of the esophagus, water-soluble contrast is injected in the distal esophagus to define the level and severity of leak. Intermittent oral and nasal suctioning is carried out to minimize the risk of aspiration. Once the duodenum is cannulated, the stent is introduced over a stiff guide wire without sheath to cover the area of leak. No post deployment balloon dilatation is performed (Figure 1). Post stenting feeding was resumed through nasojejunal tube or total parenteral nutrition, then liquid/solid oral diet was advanced as tolerated. Stent retrieval is carried

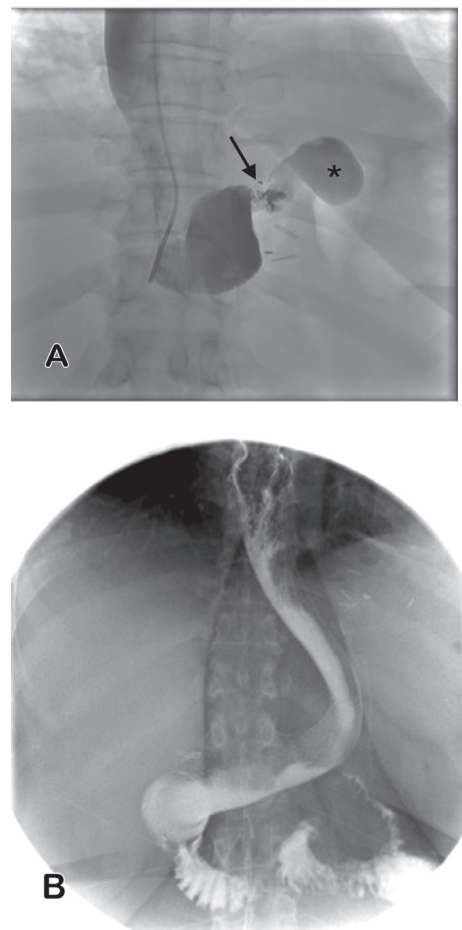


Figure 1 - Esophagogram showing A) the initial proximal staple line leak (arrow) into a left subdiaphragmatic collection (asterisk) and B) follow up with stent in place with patent stent with no residual leak.

Disclosure. Authors have no conflict of interests, and the work was not supported or funded by any drug company.

out using a Raptor™ grasping device (US endoscopy, Mentor, Ohio) introduced through a 9 Fr sheath after placing a safety guide wire to maintain access after stent removal. The proximal edge of the stent is captured and removed along with the sheath through the mouth (Figure 2). Post removal esophagogram was carried out to check for persistent leak. Technical success is defined as successful sealing of the leak using the stent at the conclusion of procedure. Clinical success is defined as healing of the leak and resumption of oral intake at the time of follow up without the need for surgical intervention. Duration of stenting is the time between the initial stent placement and removal of the last stent. Follow up time is the time between removal of the last stent and last clinical follow up.

Linear Pearson correlation and univariate regression analysis was performed on Microsoft Excel® version 14.5.5 (Microsoft Corporation, Redmond, WA) supported by StatPlus:mac program Version 5 (AnalystSoft Inc., Walnut, CA, USA)

Results. Stent placement was technically successful in all patients. Asymptomatic stent migration occurred in 6 patients (50%). Migration occurred in cranial direction (n=1) and caudally (n=5). One stent migrated immediately after placement and required adjustment during the same session, while other stents migrated during follow up period. There is a tendency for stent migration with shorter stent length ($R = -0.56$, $p = 0.008$). There is a weak negative correlation between migration and stent diameter ($R = -0.47$, $p = 0.03$). The mean duration of stenting was 60.5 days (14-137 days). Patients reported no symptoms of stent intolerance or symptomatic reflux. No patients required additional surgical interventions. Nine stent re-insertion procedures were performed in 7 patients due to either stent migration (n=6) or persistent leak (n=5) after removal of the first stent. Additional interventions included percutaneous peri-gastric collection drainage in 6 patients. Endoscopic glue injection with clipping (n=3) was carried out due to persistent leak identified on esophagogram during stent removal earlier than 4 weeks. No subsequent endoscopic or surgical interventions. Two stent removal procedures were carried out under endoscopic visualization after failed stent capture under fluoroscopy, while the remaining stents were successfully removed by interventional radiology. One patient with Polyflex silicon covered stent required ballooning of the distal end of the stent as the stent was blocked against duodenal wall. One patient had an episode of upper GI bleeding post stenting with no identifiable source on endoscopy or

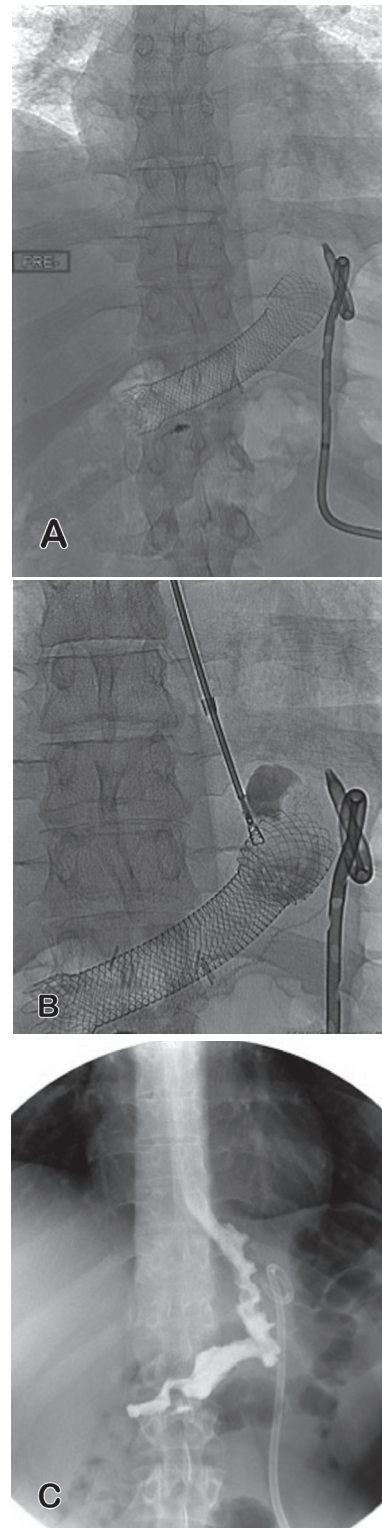


Figure 2 - Control radiograph showing A) migrating esophageal stent into the gastric lumen. B) Intra procedural radiograph with a forceps capturing the proximal edge of the stent. C) Post removal esophagogram with no residual leak.

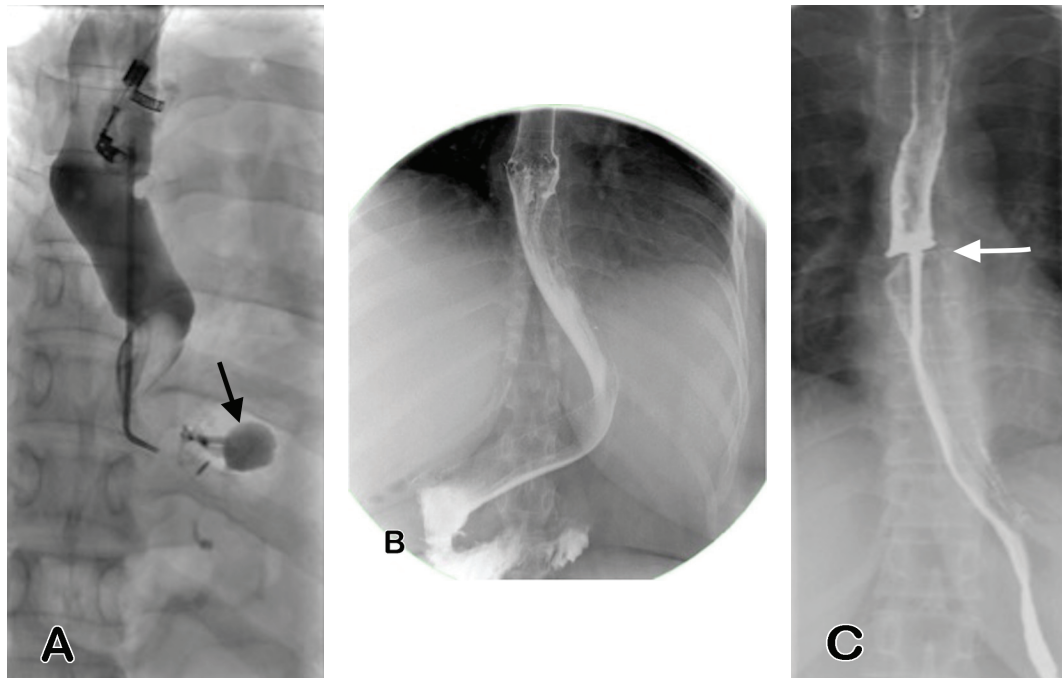


Figure 3 - Esophagogram showing A) the proximal staple line leak (arrow), B) follow up 4 days following stent placement with patent stent with no residual leak, and C) 6 month follow up study post stent removal with high grade stricture at the level of the proximal stent margin (arrow).

angiography. Another patient had esophageal stricture at the proximal stent margin 6 months after stent removal, which required esophagoplasty with 16 mm esophageal balloon and 1 mm deep incisions at 4 quadrants under endoscopic guidance (Figure 3). All patients underwent stent removal and resumed oral intake with no recurrence of leak at a median follow up time of 190 days (14-410 days).

Discussion. Despite increasing experience with laparoscopic sleeve gastrectomy and bariatric procedures, anastomotic and staple line leak continues to be a serious complication.^{1,3,9-11} While surgical interventions remain the mainstay in management of patients with symptomatic leak,^{3,10,12} covered stents are increasingly used as an effective adjunct method to isolate the leak from gastric contents and facilitate resumption of oral intake.^{2,3,5-8,10,12-21} According to the international sleeve gastrectomy expert panel consensus statement in 2012,¹¹ leak is defined as acute <7 days, early 1-6 weeks, late 6-12 weeks, chronic >12 weeks. As majority agreed upon in the mentioned consensus document, stenting is a valid option for proximal acute or early leak as a primary management or after failed conservative treatment. In the absence of peritonitis or sepsis, early stent placement after diagnosis of gastric leak is associated with shorter healing time,^{8,12-14,17,18} while it has a limited role in the management of chronic

leaks.^{3,11} In addition, smaller leaks are more likely to seal using covered stents in a shorter time compared to larger leaks. In a series of 19 patients, Nedelcu et al¹³ proposed the primary use of covered stents in patients who have early leak greater than 10 mm or for smaller leaks associated with stenosis. Using this algorithm, complete healing was achieved in all patients in average time of 3.4 months with no additional surgical interventions. However, time to complete healing was shorter in leaks smaller than 10 mm (2.8 month) compared to larger leaks (3.9 month). A retrospective review of stenting in 29 patients with acute staple line leak following sleeve gastrectomy (n=10) and a Roux-en-Y gastric bypass (n=19) showed a success rate of 96.5%.⁸ Primary stenting (with or without simultaneous surgery) resulted in shorter leak resolution time as compared to the secondary stenting (after surgical repair) (mean 50 versus 109 days, $p=0.008$).⁸ Based on findings of previous studies, the recommended duration of stenting varies between 4-12 weeks.^{14,17,18,21} In our cohort, the duration of stenting ranged between 2-20 weeks. Stent removal earlier than 4 weeks showed persistent leak and required either endoscopic glue injection with clipping or stent re-insertion.

Stent migration, which occurs in 15-60% of cases, is the most common complication that frequently requires re-intervention to maintain coverage of the leak.^{5,8,13,18} Migration occurred in our cohort in 50%, which was

primarily linked to shorter stent length (<18 cm) and to a lesser extent to small stent diameter (<25 mm). While the use of partially covered stents is associated with less risk of migration, retrieval may become difficult requiring modified techniques due to tissue ingrowth and proximal mucosal injury.^{5,22} All stents used in this series were fully covered and there was no difficulty in the retrieval procedure.

Our study is inherently limited by its retrospective nature and small sample size that limit its statistical power. The use of different types of stents with variable diameter and length is an additional limitation. The duration of stenting also varied significantly among patients, which may affect the efficacy of stenting in management of leak. The exact fluoroscopy time for stent placement and retrieval procedures was not available in our archives.

In conclusion, stenting as a primary measure after diagnosis of early leak achieved successful healing in all patients. While minimally invasive interventions may still be required for management of stent migration or persistent leak, stenting appears to offer a safe and effective alternative option in obviating repeat surgical interventions.

References

- Committee ACI. Updated position statement on sleeve gastrectomy as a bariatric procedure. *Surg Obes Relat Dis* 2012; 8: e21-e26.
- Moon RC, Shah N, Teixeira AF, Jawad MA. Management of staple line leaks following sleeve gastrectomy. *Surg Obes Relat Dis* 2015; 11: 54-59.
- Gagner M, Deitel M, Erickson AL, Crosby RD. Survey on laparoscopic sleeve gastrectomy (LSG) at the Fourth International Consensus Summit on Sleeve Gastrectomy. *Obes Surg* 2013; 23: 2013-2017.
- Fuks D1, Verhaeghe P, Brehant O, Sabbagh C, Dumont F, Riboulot M, et al. Results of laparoscopic sleeve gastrectomy: a prospective study in 135 patients with morbid obesity. *Surgery* 2009; 145: 106-113.
- Walsh C, Karmali S. Endoscopic management of bariatric complications: A review and update. *World J Gastrointest Endosc* 2015; 7: 518-523.
- de Aretxabala X, Leon J, Wiedmaier G, Turu I, Ovalle C, Maluenda F, et al. Gastric leak after sleeve gastrectomy: analysis of its management. *Obes Surg* 2011; 21: 1232-1237.
- Nguyen NT, Nguyen XM, Dholakia C. The use of endoscopic stent in management of leaks after sleeve gastrectomy. *Obes Surg* 2010; 20: 1289-1292.
- Quezada N, Maiz C, Daroch D, Funke R, Sharp A, Boza C, et al. Effect of early use of covered self-expandable endoscopic stent on the treatment of postoperative stapler line leaks. *Obes Surg* 2015; 25: 1816-1821.
- Gagner M. Decreased incidence of leaks after sleeve gastrectomy and improved treatments. *Surg Obes Relat Dis* 2014; 10: 611-612.
- Sakran N, Goitein D, Raziell A, Keidar A, Beglaibter N, Grinbaum R, et al. Gastric leaks after sleeve gastrectomy: a multicenter experience with 2,834 patients. *Surg Endosc* 2013; 27: 240-245.
- Rosenthal RJ; International Sleeve Gastrectomy Expert Panel, Diaz AA, Arvidsson D, Baker RS, Basso N, et al. International sleeve gastrectomy expert panel consensus statement: best practice guidelines based on experience of >12,000 cases. *Surg Obes Relat Dis* 2012; 8: 8-19.
- Nimeri A, Ibrahim M, Maasher A, Al Hadad M. Management algorithm for leaks following laparoscopic sleeve gastrectomy. *Surg Obes Relat Dis* 2012; 8: 8-19.
- Nedelcu M, Manos T, Cotirlet A, Noel P, Gagner M. Outcome of leaks after sleeve gastrectomy based on a new algorithm addressing leak size and gastric stenosis. *Obes Surg* 2015; 25: 559-563.
- Murino A, Arvanitakis M, Le Moine O, Blero D, Deviere J, Eisendrath P. Effectiveness of Endoscopic Management Using Self-Expandable Metal Stents in a Large Cohort of Patients with Post-bariatric Leaks. *Obes Surg* 2015; 25: 1569-1576.
- Liu SY, Wong SK, Ng EK. Novel oesophago-gastro-duodenal stenting for gastric leaks after laparoscopic sleeve gastrectomy. *Obes Res Clin Pract* 2015; 9: 214-219.
- Galloro G, Magno L, Musella M, Manta R, Zullo A, Forestieri P. A novel dedicated endoscopic stent for staple-line leaks after laparoscopic sleeve gastrectomy: a case series. *Surg Obes Relat Dis* 2014; 10: 607-611.
- Alazmi W, Al-Sabah S, Ali DA, Almazeedi S. Treating sleeve gastrectomy leak with endoscopic stenting: the Kuwaiti experience and review of recent literature. *Surg Endosc* 2014; 28: 3425-3428.
- Simon F, Siciliano I, Gillet A, Castel B, Coffin B, Msika S. Gastric leak after laparoscopic sleeve gastrectomy: early covered self-expandable stent reduces healing time. *Obes Surg* 2013; 23: 687-692.
- Nwilo JO. Self-expanding stents in treatment of esophageal leaks post bariatric surgery. *Gen Thorac Cardiovasc Surg* 2013; 61: 38-42.
- Leenders BJ, Stronkhorst A, Smulders FJ, Nieuwenhuijzen GA, Gilissen LP. Removable and repositionable covered metal self-expandable stents for leaks after upper gastrointestinal surgery: experiences in a tertiary referral hospital. *Surg Endosc* 2013; 27: 2751-2759.
- Donatelli G1, Dhumane P, Perretta S, Dallemagne B, Vix M, Mutter D, et al. Endoscopic placement of fully covered self expanding metal stents for management of post-operative foregut leaks. *J Minim Access Surg* 2012; 8: 118-124.
- Wei W, Ramaswamy A, de la Torre R, Miedema BW. Partially covered esophageal stents cause bowel injury when used to treat complications of bariatric surgery. *Surg Endosc* 2013; 27: 56-60.