

# Excision of oral pyogenic granuloma in a diabetic patient with 940nm diode laser

Maha A. Al-Mohaya, ABOM, DMSc, Abdulaziz M. Al-Malik, BDS, MSc.

## ABSTRACT

الورم الحبيبي القيحي (PG) هو ورم دموي حميد مكتسب شائع الإنتشار. ينشأ عادة على شكل لطاخة حمامية صغيرة على الجلد أو سطح الغشاء المخاطي الفموي. الورم الفموي يظهر بسبب التهاب مستمر ذو درجة منخفضة، أو كدمات فموية أو إهمال في عناية الفم أو بسبب الاضطرابات الهرمونية. و تعتبر اللثة أكثر عرضة للإصابة بهذا الورم. ويمكن إستئصال الورم جراحيا مع إزالة الأسباب الكامنة وراء بعض الحالات ولكن هذا الإجراء قد يتسبب في مضاعفات غير ضرورية. حديثا يوجد أنواع متعددة من الليزر تستخدم بوضع الإعدادات المناسبة لكل جهاز لإستئصال الورم الحبيبي القيحي. وبهذا السياق، نقدم حالة إستئصال ورم حبيبي قيحي لثوي من لثة سيدة تبلغ من العمر واحد وخمسون عاما و مصابة بداء السكري الغير منضبط. وقد تم إستئصال الورم بنجاح بواسطة إستخدام جهاز ديود ليزر 940 نانومتر. و يعتبر هذا النوع من العلاج إجراء تحفظي وغير مرهق حيث أنه لا يسبب نزيف و يساعد في الإسراع من عملية الإلتئام مع الحد الأدنى من وجود ألم أو تورم أو تندب بسيط. لذا فإن ديود ليزر 940nm يقدم أداة جديدة و فعالة لاستئصال الآفات والأورام في الأنسجة الفموية الطرية وخاصة عند المرضى ذوي الحالات الطبية الحرجة.

Pyogenic granuloma (PG) is a common, acquired, benign vascular reactive proliferation that typically develops as a small erythematous papule on the skin or oral mucosal surface. Oral PG is often caused by constant low-grade infection, minor trauma, poor oral hygiene, and due to hormonal disturbances. It shows a striking predilection for the gingiva. Lesions can be excised surgically with removal of the underlying causes. However, this modality may be associated with unnecessary complications. Recently, different laser wavelengths have been used for removal of oral PG. Herein, we present a case of gingival PG in a 51-year-old uncontrolled diabetic woman. The lesion was excised successfully with a 940nm diode laser as a conservative and non-stressful procedure that resulted in a bloodless surgical and post-surgical course with rapid healing, minimal pain, swelling, and scarring. The 940nm Diode laser offers a new

efficient noninvasive tool for excising oral soft tissue lesions, especially in medically compromised patients.

*Saudi Med J 2016; Vol. 37 (12): 1395-1400  
doi: 10.15537/smj.2016.12.15941*

*From the Department of Dentistry, Prince Sultan Military Medical City, Riyadh, Kingdom of Saudi Arabia.*

*Received 21st July 2016. Accepted 4th September 2016.*

*Address correspondence and reprint request to: Dr. Maha A. Al-Mohaya, Chairman and Consultant of Oral Medicine and Special Care Dentistry, Department of Dentistry, Prince Sultan Military Medical City, Riyadh, Kingdom of Saudi Arabia.  
E-mail: malmohaya2013@gmail.com*

Pyogenic granuloma (PG), also known as lobular capillary hemangioma, is a common, acquired, benign vascular proliferation of the skin and mucous membrane.<sup>1</sup> Oral PG is a common, tumor-like, exaggerated tissue response to a localized low-grade irritation or minor trauma, or hormonal factors such as in lesions occurring during pregnancy and at puberty. The name PG is a misnomer, it was originally thought to be caused by pyogenic organisms. It is now believed to be unrelated to infection, and the condition is neither associated with pus nor represents a granuloma histologically.<sup>2,3</sup>

Clinically, a PG appears as a smooth mass, or the lesion exhibits a lobular architecture that is usually pedunculated, although some lesions are sessile. The amount of vascularity determines the surface color and

**Disclosure.** Authors have no conflict of interests, and the work was not supported or funded by any drug company. Dr. Maha A. Al-Mohaya is a member of the Editorial Team, and was therefore excluded from any final editorial decisions regarding this paper.

the age of the lesion. While newly developed lesions tend to be highly vascular and bluish or purple in color with a tendency to bleed and ulcerate even with minor trauma, older lesions are more fibrotic and pink in color. They vary from small growths only a few millimeters in size to larger lesions that may measure several centimeters in diameter. Typically, the mass is painless, although it often bleeds easily because of its extreme vascularity.<sup>2</sup>

Oral PG shows a striking predilection for the gingiva. The lip, tongue, and buccal mucosa are the next common sites. It is most common in children and young adults with definite female predilection (female to male ratio of 2:1), possibly because of the vascular effects of female hormones. Pyogenic granuloma of the gingiva develops in pregnant women frequently; therefore, the terms pregnancy tumor or granuloma gravidarum are often used.<sup>4</sup> The differential diagnosis of PG includes peripheral giant cell granuloma, peripheral ossifying fibroma, and hemangioma. The final diagnosis is mainly based on biopsy and histopathological examination.<sup>2</sup>

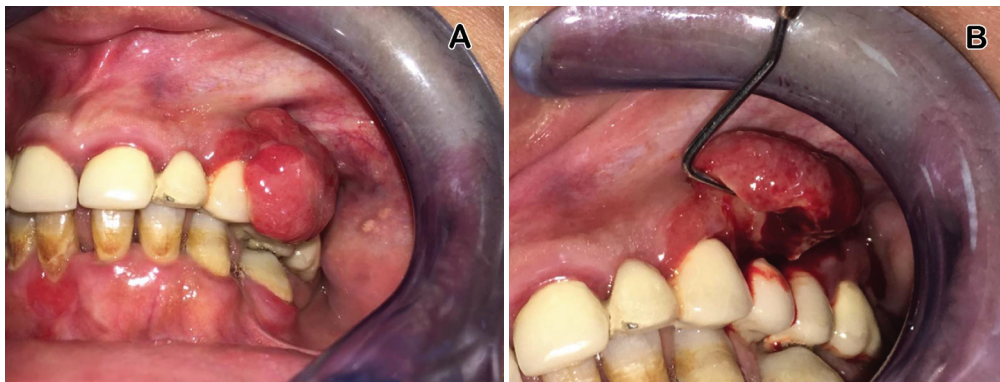
Oral PG can be treated by conservative excision. Local irritants or the source of trauma must be eliminated to minimize the risk of recurrence. Although, surgical excision is considered a simple procedure, it might be complicated by several complications such as intraoperative bleeding, and postoperative infection that might delay the healing of the wound. Other treatment modalities such as cryosurgery, injection of sclerosing agents (corticosteroid or ethanol, and sodium tetradecyl sulfate) have been used previously.<sup>3-6</sup>

Lasers were introduced into dentistry more than 4 decades ago. Since that time, different wavelengths have been used for oral soft tissue dental procedures. The dental laser can provide clean incision of tissues,

immediate coagulation, and minimal postoperative pain, and edema. Various laser devices have been successfully used to treat PG, such as neodymium-doped yttrium aluminium garnet (Nd:YAG),<sup>7</sup> carbon dioxide laser,<sup>6</sup> erbium-doped yttrium aluminum garnet (Er:YAG),<sup>8</sup> and the diode laser.<sup>9,10</sup>

A diode laser is a semiconductor device using aluminum, gallium, arsenide, and occasionally indium as the active medium. The device produces coherent radiation (in which the waves are all at the same frequency and phase) in the visible or infrared spectrum with wavelengths ranging from 810nm to 980nm. Therefore, all wavelengths are absorbed properly by pigmented tissue, which contains melanin and hemoglobin. However, they are poorly absorbed by calcified tissue such as hydroxyapatite and water present in the enamel. The diode laser-tissue interaction makes it considerably safe and well-indicated for soft oral tissue surgeries in regions near the dental structures.<sup>9</sup> In this report, we present a case of a large PG in an uncontrolled diabetic patient excised successfully with a 940nm diode laser with minimal postoperative complications.

**Case Report.** We report on a 51-year-old female, with a long history of uncontrolled type II diabetes mellitus, referred to the Oral Medicine Division, Department of Dentistry, Prince Sultan Military Medical City, Riyadh, Saudi Arabia with the complaint of a localized gingival growth for more than 2 years, and which had gradually increased in size. The lesion was asymptomatic but bothersome due to spontaneous bleeding, which lead her to refrain from practicing good oral hygiene. Intraoral examination (**Figure 1**) revealed a discrete lobulated pedunculated hemorrhagic tender



**Figure 1** - A) Large gingival exophytic ulcerated and lobulated mass covering the buccal surfaces of the teeth and extending into the vestibule. B) Reflecting the mass to examine the point of origin.

nodular mass covering the buccal aspect of the gingiva on the region of 23-25, measuring approximately 2 x 1.5 x 0.7 cm. On palpation, the mass was soft to firm in consistency, and readily bled on probing. The differential diagnosis includes: PG, peripheral giant cell granuloma, and Kaposi sarcoma. Due to the bleeding tendency of the lesion, and risk of postoperative surgical site infection, a 940nm diode laser was used as a minimally invasive procedure to excise the lesion. Blood investigations were all within normal except for a high glycosylated hemoglobin level.

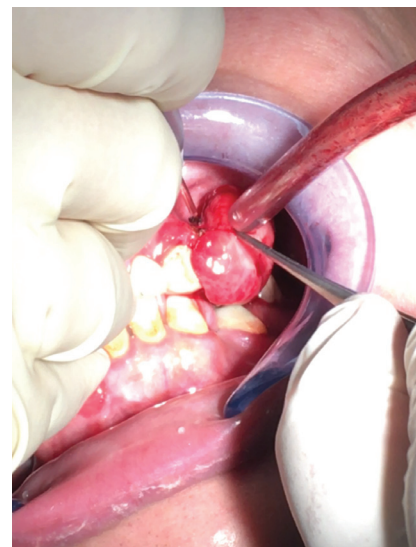Written informed consent was obtained from the patient prior to excising the lesion, and all protective precautions were taken throughout the procedure.

After infiltration of local anesthesia (2% lidocaine with 1/100,000 epinephrine), the diode laser gallium/aluminum/arsenide (GA-AL-AS) (Biolase ePic 10 Diode laser 940nm, USA) with the following specifications: continuous wave, in contact mode with a power output of 3 watt and a 0.4-mm diameter initiated disposable fiber optic (Figure 2) was introduced. The tip was directed at an angle of 10 to 15 degrees, moving around the base of the lesion with a circular motion (Figure 3). The lesion was cut at the base, but massive hemorrhage from the surgery area was observed. Therefore, we moved the laser fiber tip in a sweeping motion on the surgical site in order to achieve coagulation, and after 30 seconds hemostasis was achieved. The area was not sutured, and left for healing with secondary intention. The procedure took 3-4 minutes to complete. The mass was excised completely as one piece (Figure 4A), and immersed in 10% formalin fixative solution for histopathological examination. She was discharged with all the necessary post-operative instructions for maintenance of good oral hygiene with a prescription of 1 gm Augmentin, and 0.12% Chlorohexidine mouth rinse for 10 days, and scheduled for routine scaling and curettage. She was followed up after 5 days, 2 weeks, and 2 months to evaluate the healing process (Figure 5). The diode laser provided an optimum combination of clean cutting of the tissue and hemostasis. She was extremely comfortable, reported no post-operative complications, and healing was observed within a couple of days after surgery.

Histological examination using hematoxylin and eosin staining (H & E) revealed an exophytic mass with an ulcerated surface and underlying fibrovascular granulation tissue like stroma. The stroma consisted of a large number of budding and dilated capillaries and lobular endothelial proliferation, plump fibroblasts, and a dense chronic inflammatory cell infiltrate in the deeper connective tissue. These features confirmed the diagnosis of PG (Figures 4B-4C).



**Figure 2** - Biolase ePic 10 Diode laser 940nm, showing the applied Laser parameters

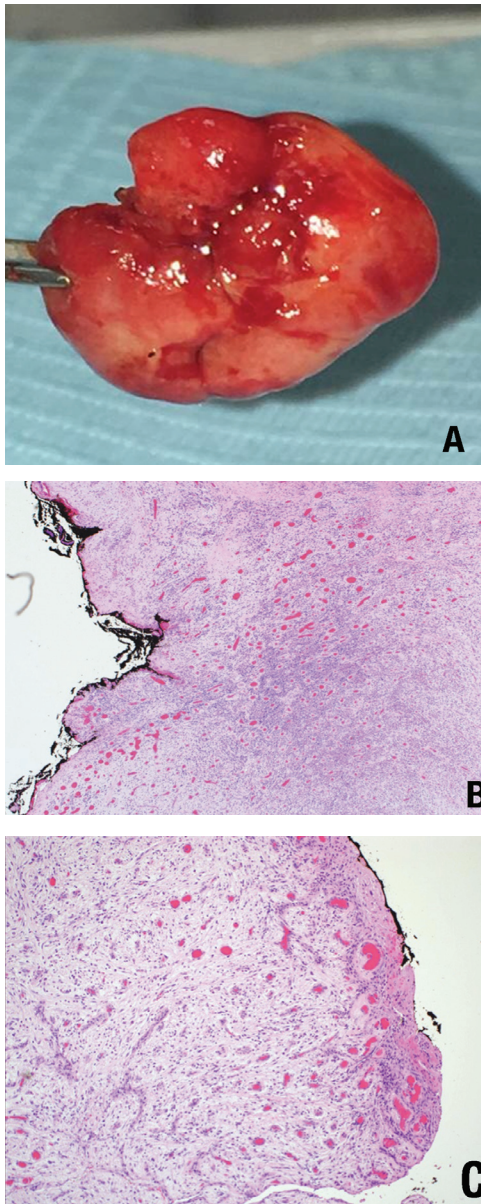


**Figure 3** - The tip directed at the base of the lesion and cut around with a circular motion.

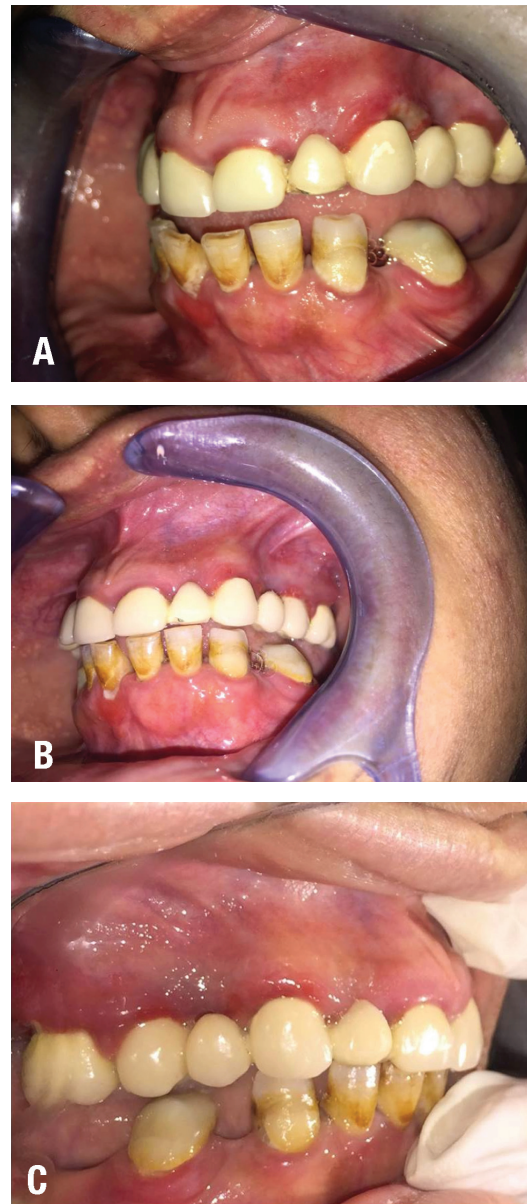
**Discussion.** Oral PG is a common reactive lesion that may appear at any age, but incidence peaks during the third decade of life, and women are twice as likely to be affected. Clinically, it appears as a small papule that evolves rapidly into an exophytic nodular pedunculated or sessile mass with color ranging from pink to red to blue according to the age of the lesion and amount of vascularity. The lesion has a greater tendency to bleed or ulcerate even with minimum trauma. The gingiva is the most common location, which accounts for 75% of all cases.<sup>1-3</sup>

Gingival irritation and inflammation that results from poor oral hygiene or hormonal imbalances may





**Figure 4 -** A) Excisional biopsy specimen (macroscopic examination). B) Hematoxylin and eosin staining histological examination shows numerous engorged blood vessels with intense inflammatory cell infiltrate. C) The surface ulceration.



**Figure 5 -** A) Follow up visit in 5 days; note the healing with minimal surface ulcerations. B) Follow up visit in 2 months (direct view) C) Follow up visit in 2 months (mirror view).

be a precipitating factor in many patients.<sup>4</sup> In this case, uncontrolled high levels of blood glucose in addition to poor oral hygiene are believed to contribute to the considerable size of the lesion. Conservative surgical excision of a PG is the treatment choice that is usually curative. The specimen should be submitted for microscopic examination to rule out other more serious diagnoses. For conventional scalpel surgical excision of gingival lesions, the excision should extend

down the periosteum and the adjacent teeth should be thoroughly scaled to remove any source of continuing irritation. Bleeding, suturing, and postoperative discomfort complications are major drawbacks of surgical intervention. Occasionally, the lesion recurs and reexcision is necessary.<sup>2</sup> Other less invasive treatment modalities have been attempted in the past with limited benefits, such as: cryosurgery, cauterization with silver nitrate, sclerotherapy with sodium tetra

decyl sulfate, and absolute ethanol injection dye.<sup>3</sup> Laser technology has been widely utilized in surgical dentistry due to its friendly doctor and patient uses. The excision of exophytic lesions is one of these utilizations. The laser transmits energy to the cells causing warming, coagulation, protein denaturation, vaporization, and carbonization.

The advantages of laser application are relatively bloodless surgery as it seals the blood vessels and nerve bundles while cutting, which aids in better visualization of the site and a sutureless procedure with minimal postoperative pain. Additionally, the laser instantly disinfects the surgical wound with consequent less postoperative infection, minimal swelling, and enhanced healing. In areas where aesthetics are important, the laser is a less invasive method compared to scalpel and cryosurgery techniques.<sup>6</sup>

Laser excision was reported to be well tolerated by patients with no or minimal adverse effects. Gex-Collet et al<sup>7</sup> applied the Nd:YAG laser for excision of PG, and the authors observed and reported a lower risk of bleeding compared with other surgical techniques. In a more recent study, Kocaman et al<sup>11</sup> used Nd:YAG laser for oral PG removal and concluded that the use of Nd:YAG laser reduced intraoperative bleeding, operating time, and had better patient acceptance. The Er:YAG laser has also been used for removal of gingival PG followed by root curettage. One study<sup>8</sup> reported that the Er:YAG laser is an effective technique for both soft and hard tissue treatment due to its good absorption by hydroxyapatite and water.<sup>8</sup>

Most laser wavelengths are expensive, and their machines are bulky; hence, it may not be cost effective for simple surgical excision. In contrast, the diode laser devices have specifications such as relatively small size, portability, and lower costs that attract the dental practitioners and oral surgeons to their use in various surgical indications in comparison with other laser equipment. The pump source is an electrical current, the photons are produced by an electric current, and the laser's active medium is a semiconductor (GA-AL-AS). The diode lasers have been used in 3 wavelengths 810, 940, and 980nm in surgical treatments. Provided there is correct selection and application of diode lasers in soft tissue oral surgery; for example, frenectomy, epulis fissuratum, fibroma, facial pigmentation, and vascular lesions. They are safe and useful.<sup>12</sup>

Rai et al<sup>6</sup> suggested a diode laser as a powerful tool for the treatment of oral PG. They used an 808 diode laser with an output energy of 0.1-7.0 W for the successful removal of PG. Iyer and Sasikumar<sup>10</sup> highlighted the advantages of a 940nm diode laser over the conventional

treatment option in excision of oral PG. Moreover, a diode laser with 810-980nm wavelengths has been used for soft tissue cutting in pediatric patients.<sup>9</sup> The advantages of lasers in removal of soft tissue lesions in pediatric patients include no need for anesthesia, which reduces the child's apprehension, and less hemorrhage, and postsurgical discomfort.

The use of a 940nm diode laser in the presented case offered the best treatment option to reduce the risk of postoperative infection and impaired healing that are well-known complications of uncontrolled diabetes. This finding is in correlation with numerous studies demonstrating that the laser creates locally sterile conditions, which would result in the reduction of bacteremia concomitant to the operation due to the bactericidal effect of laser energy.<sup>9-10, 12</sup>

In conclusion, the presented case adds to the existing evidence supporting the usefulness of the 940nm diode laser as a minimally invasive procedure for excision of oral PG, especially in patients with underlying medical conditions that might decelerate healing, such as uncontrolled diabetes mellitus. The advantages of the tool used in this report can be summarized as follows; rapid blood vessel sealing, which improves the visibility of the surgical site and reduces the need for post-surgical dressings and improves hemostasis and coagulation, suture-less procedures, nerve depolarization, thus reducing post-operative pain, bactericidal effects that reduce postoperative infection, rapid healing and reduced post-operative discomfort, edema, and scarring.

**Acknowledgment.** *We would like to thank Dr. Muna Juboury consultant histopathologist for histopathological examination of the case and we extend our appreciation to Dr. Lubna Majed Al-Otaibi for her valuable help in taking photographs during the procedure.*

## References

1. Leung AKC, Barankin B, Hon KL. Pyogenic granuloma. *Clinics in Mother and Child Health* 2013; 11: 1-3.
2. Neville BW, Damm DD, Allen CM, Bouquet JE. In: Oral and maxillofacial pathology, 4th ed. Netherlands: Elsevier; 2015. p. 513-517.
3. Jafarzadeh H, Sanatkhan M, Mohtasham N. Oral pyogenic granuloma: a review. *J Oral Sci* 2006; 48: 167-175.
4. Kamal R, Dahiya P, Puri A. Oral pyogenic granuloma: Various concepts of etiopathogenesis. *J Oral Maxillofac Pathol* 2012; 16: 79-82.
5. Raulin C, Greve B, Hammes S. The combined continuous wave/pulsed carbon dioxide laser for treatment of pyogenic granuloma. *Arch Dermatol* 2002; 138: 33-37.
6. Rai S, Kaur M, Bhatnagar P. Laser: a powerful tool for treatment of pyogenic granuloma. *J Cutan Aesthet Surg* 2011; 4: 144-147.

7. Gex-Collet C, Itin PH, Scherer K. Pyogenic granuloma treated with pulsed Nd:YAG (1064 nm) laser. A case series. *Medical Laser Application* 2008; 23; 115-119.
8. Fekrazad R, Nokhbatolfoghahaei H, Khoei F, Kalhori KA. Pyogenic granuloma: surgical treatment with Er:YAG laser. *J Lasers Med Sci* 2014; 5: 199-205.
9. Asnaashari M, Mehdipour M, MoradiAbbasabadi F, Azari-Marhabi S. Expedited removal of pyogenic granuloma by diode laser in a pediatric patient. *J Lasers Med Sci* 2015; 6: 40-44.
10. Iyer VH, Sasikumar R. Management of oral pyogenic granuloma with 940 nm diode laser: a rare case report. *International Journal of Laser Dentistry* 2013; 3: 100-104.
11. Kocaman G, Beldüz N, Erdogan C, Ozbek E, Sadik E, Kara C. The use of surgical Nd:YAG laser in an oral pyogenic granuloma: a case report. *J Cosmet Laser Ther* 2014; 16: 197-200.
12. Azma E, Safavi N. Diode laser application in soft tissue oral surgery. *Med Sci* 2013; 4: 206-211.