

# A giant tonsillolith

Abdulrhman Alfayez, MD, Meshal B. Albeshar, MBBS, Mohammed A. Alqabasani, MD.

### ABSTRACT

الحصى اللوزية هي نتاج ترسب تجمعات متصلبة من بقايا الخلايا الميتة وبعض الأحياء الدقيقة الميكروبية حيث تتكوّن هذه الترسبات في تجاويف اللوز الحنكية. تكوّن الحصى اللوزية هو أمر شائع بين الناس وأبرز علاماتها هي رائحة الفم الكريهة. على النقيض، تكوّن الحصى اللوزية الضخمة يعتبر نادر الحدوث. هناك حالات قليلة سُجّلت في قواعد البيانات العلمية لتكوّن الحصى اللوزية الضخمة. في هذه الورقة العلمية نستعرض رجلاً عمره خمس وأربعون سنة مصاباً بداء السكري يشتكي من التهاب متكرر في الحلق واللوزتين لمدة طويلة وشخير. المريض لم يكن يشتكي من أعراض أخرى متعلقة بالأنف والأذن والحنجرة. خلال الفحص السريري تم ملاحظة حصى ضخمة حجمها 3.1 × 2.3 سم في اللوزة الحنكية اليسرى. خضع المريض لعملية استئصال للوزتين اختياريًا مع إزالة الحصى.

Tonsillar stones are the products of calcified accumulates of cellular debris and microorganisms, in the crypts of palatine tonsils. Tonsillar stones are common findings and the known cause of bad breath (halitosis). Development of large tonsillar stones, however, is rare with only a few cases reported in the literature. We present the case of a 45-year-old man with a history of recurrent sore throat and tonsillitis for a long period, and snoring with other unremarkable ears, nose and throat findings. A large-sized tonsillar stone detected in the left tonsil measured 3.1 × 2.3 cm. The patient underwent elective stone removal and tonsillectomy.

*Saudi Med J 2018; Vol. 39 (4): 412-414  
doi: 10.15537/smj.2018.4.21832*

*From the Department of Ears, Nose and Throat (Alfayez, Alqabasani), King Abdulaziz Medical City, and King Saud bin Abdulaziz University for Health Sciences (Albeshar), Riyadh, Kingdom of Saudi Arabia.*

*Received 11th December 2017. Accepted 25th January 2018.*

*Address correspondence and reprint request to: Dr. Meshal B. Albeshar, King Saud bin Abdulaziz University for Health Sciences, Riyadh, Kingdom of Saudi Arabia. E-mail: meshalbassam@gmail.com  
ORCID ID: orcid.org/0000-0002-1792-7537*

Tonsillar stones (tonsilloliths) are white or yellow concretions in tonsillar crypts that originate as a result of microorganism and cellular debris retention in the crypts of palatine tonsils. Calcium hydroxyapatite and calcium carbonate along with other minerals including phosphorus, ammonia, and magnesium are the common types of stones identified in histology studies of tonsilloliths.<sup>1</sup> Tonsillolithiasis, the formation of tonsil stones, is thought to occur mainly due to repeated inflammation of the tonsillar crypts with recurrent tonsillitis and calcification. The age of patients with tonsil stones ranges between 10 and 77 years with a median age of 50 years with a male to female ratio of 1:1.<sup>2</sup> Tonsil stones are common findings, observed in excised tonsils on gross inspection and specimen sectioning, and are associated with recurrent sore throat. Halitosis (bad breath) is the main clinical complaint in small tonsilloliths.<sup>3</sup> In contrast, tonsillolithiasis of large stones is a rarity with a few cases reported in the literature.<sup>4</sup>

**Case Report. Patient Information.** A 45-year-old man presented with a history of recurrent sore throat and tonsillitis since a long period of time. Patient is a diagnosed case of diabetes mellitus and hypertension and on medical treatment. There was no remarkable past medical or surgical history (Table 1).

**Clinical findings.** History of recurrent sore throat and tonsillitis since a long period of time. The sore throat was associated with snoring. There were no odynophagia, dysphagia, or other ears, nose and throat (ENT) symptoms. Throat examination showed enlarged tonsils grade 4 plus cellulitis of the left tonsil and a large left tonsil stone (Figures 1 & 2). Ear and nose examination results were normal. The other ENT examinations were unremarkable.

**Therapeutic intervention.** The patient was admitted for elective surgery for removal of the tonsillolith and bilateral tonsillectomy. A large-sized tonsillolith observed during the surgery, had led to the expansion of the entire left upper pole. It was dissected gently using a freer dissector and the stone was removed prior to tonsillar excision. The tonsillolith measured

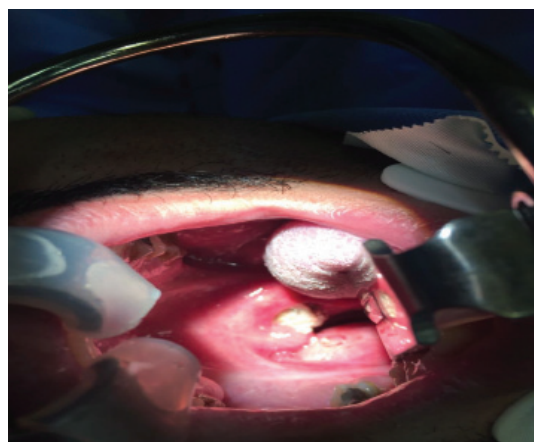
**Table 1** - Case report timeline table.

Date	Relevant past medical history and intervention		
10 November 2015	A 45-year-old man presented with a history of recurrent sore throat and tonsillitis since a long period of time. Patient is a diagnosed case of diabetes mellitus and hypertension and on medical treatment. There was no remarkable past medical or surgical history.		
Date	Summaries from initial and follow up visits	Diagnostic testing	Interventions
10 November 2015	Patient was seen and examined in ENT clinic. Decision for tonsillectomy was made.	None	Book for elective tonsillectomy. Patient to be seen by pre-anesthesia clinic.
23 December 2015	Patient admitted for elective tonsillectomy and stone removal in surgical day care unit.		Tonsillectomy and stone removal done successfully. Patient was kept for 24 hours observation afterwards as per anesthesia recommendation.
24 December 2015	Patient discharged.		On discharge, the patient was stable. Throat was normal. There were no bleeding points or clots. Patient was tolerating orally and was ambulating.
06 January 2016	Secondary hemorrhage post tonsillectomy		Controlled intra-operatively under general anesthesia.
Follow up visits	Patient followed up post-operatively.		Recurrent sore throat and snoring improved. No complications.

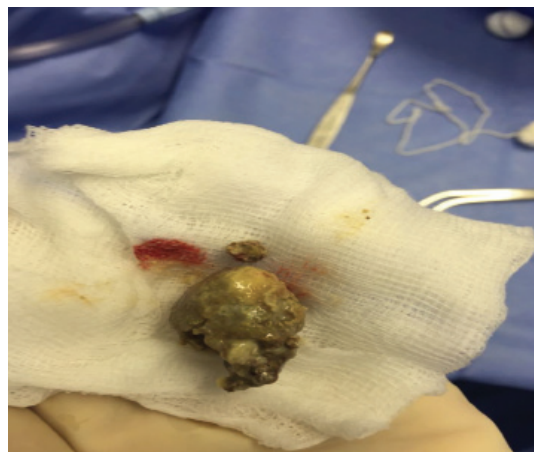3.1 × 2.3 cm, right tonsil 3 × 2 × 0.5 cm and the left tonsil 4 × 1.5 × 0.5 cm (Figures 3 & 4). The pathology report for the right and left tonsils revealed a reactive squamous epithelium and reactive lymphoid hyperplasia as well as actinomyces and focal acute inflammation. The occurrence of stone formation in the left tonsil is possibly secondary to the recurrent chronic tonsillitis process. There was no evident malignancy identified.

**Follow-up and Outcomes.** Two weeks later, the patient presented with secondary hemorrhage post-tonsillectomy, which was controlled under general anesthesia with no complications thereafter. Patient followed up post-operatively, recurrent sore throat and snoring improved. No complications afterward.

**Discussion.** Tonsillar stones (tonsilloliths) are products of calcified accumulates of food, cellular debris, and microorganism aggregates in the crypts of palatine tonsils.<sup>3</sup> Tonsillar crypts are fissure-like invaginations in the medial side of the palatine tonsils and serve to increase the surface area of the tonsils with more than 10 crypts in each tonsil. Small tonsilloliths are common findings associated with recurrent sore throat and if symptomatic, usually present with a chief complaint of halitosis or bad breath.<sup>3</sup> However, large tonsilloliths are rare entities and a few cases are reported in literature.<sup>4</sup> The exact mechanism of development of tonsillar stones is not well understood. However, several hypotheses exist to explain formation of these

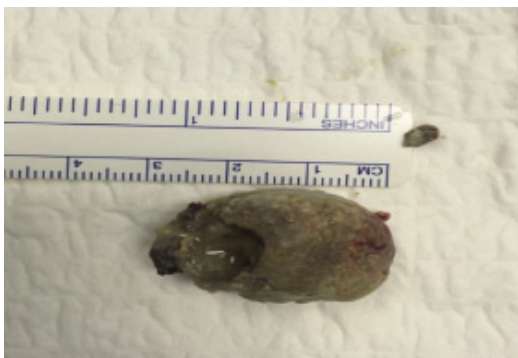

**Figure 1** - Enlarged tonsils grade 4 plus cellulitis of the left tonsil and a large left tonsil stone.

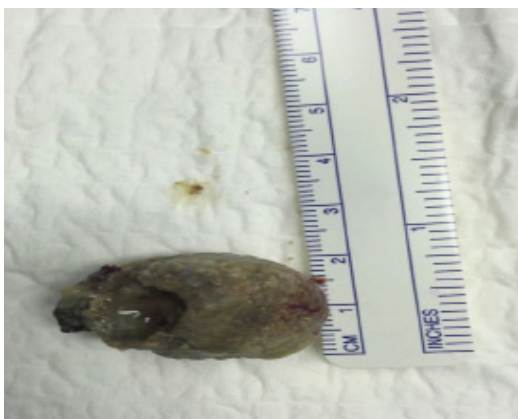

**Figure 2** - A giant tonsillolith extracted of left tonsil.

**Disclosure.** Authors have no conflict of interests, and the work was not supported or funded by any drug company.



**Figure 3** - Tonsillolith measured 3.1 × 2.3 cm.



**Figure 4** - Tonsillolith measured 3.1 × 2.3 cm.

calculi. One hypothesis attributes stone formation to recurrent tonsillitis and subsequent crypt fibrosis that lead to epithelial cell retention, which creates an environment for microorganism overgrowth and calcification due to deposition of inorganic salts from salivary gland secretions.<sup>5</sup> Stoodley et al<sup>6</sup> concluded that tonsilloliths share common characteristics with biofilms. Biofilms are aggregates of aerobic and non-aerobic microorganisms enclosed in an extracellular matrix. Due to the nature of biofilms, it is difficult to treat the microorganisms with antibiotics. In fact, a biofilm serves as a nidus for acute infections rendering it a source of recurrent ENT infections.<sup>7</sup> Cases of giant tonsillolith have not been reported in Saudi Arabia. Literature review shows that the largest tonsillolith was reported in a 12-year-old female child in the left tonsil and measured 4.2 × 3.6 × 2.1 cm. A majority of the cases of giant tonsilloliths reported a left tonsil stone rather than the right. Two reported cases showed bilateral giant tonsilloliths.<sup>8,9</sup> A patient with tonsillar stone is approached through history taking, physical examination, and imaging studies. A giant tonsillolith

may be an incidental finding in asymptomatic patients or maybe associated with common symptoms and signs of tonsilloliths.<sup>9</sup> Reported clinical presentations of giant tonsilloliths include recurrent sore throat, halitosis, foreign body sensation, painful swallowing (odynophagia), hoarseness, and rarely, upper airway obstruction. Differential diagnosis of tonsillar stones include foreign body, calcified granulomas, tonsillar malignancy, enlarged styloid processes, embryonic rests originating from the branchial arches.<sup>10</sup> Imaging studies may be helpful to identify the size, extension, and location of the stone. Symptomatic giant tonsilloliths are usually treated with tonsillectomy with the pathology report on type of the stone and disease process.

In conclusion, Tonsilloliths are common findings associated mainly with halitosis. However, giant tonsilloliths are rare with few cases reported in the literature. This case supports the hypothesis of tonsillolith formation secondary to recurrent tonsillitis and subsequent crypt fibrosis that lead to epithelial cell retention in the crypts of palatine tonsils. Differential diagnosis of tonsillar stones include foreign body, calcified granulomas, tonsillar malignancy, enlarged styloid processes, embryonic rests originating from the branchial arches. Imaging studies might be necessary to identify the size and extension of the stone beyond the palatine tonsils. This case was managed with tonsillectomy and pathology report on disease process.

## References

1. Dykes M, Izzat S, Pothula V. Giant tonsillolith – a rare cause of dysphagia. *J Surg Case Rep* 2012; 2012: 4.
2. Mesolella M, Cimmino M, Di Martino M, Criscuoli G, Albanese L, Galli, V. Tonsillolith. Case report and review of the literature. *Acta Otorhinolaryngol Ital* 2004; 24: 302-307.
3. Hung CC, Lee JC, Kang BH, Lin YS. Giant tonsillolith. *Otolaryngol Head Neck Surg* 2007; 137: 676-677.
4. Kanotra S1, Kanotra S, Paul J. A giant tonsillolith. *Indian J Otolaryngol Head Neck Surg* 2008; 60: 277-280.
5. Thakur JS, Minhas RS, Thakur A, Sharma DR, Mohindroo NK. Giant tonsillolith causing odynophagia in a child: a rare case report. *Cases J* 2008; 1: 50.
6. Stoodley P, Debeer, D, Longwell M, Nistico L, Hall-Stoodley L, Wenig B et al. Tonsillolith: not just a stone but a living biofilm. *Otolaryngol Head Neck Surg* 2009; 141: 316-321.
7. Krespi YP, Shrimel MG, Kacker A. The relationship between oral malodor and volatile sulfur compound-producing bacteria. *Otolaryngol Head Neck Surg* 2006; 135: 671-676.
8. Lo RH, Chang KP, Chu ST. Upper airway obstruction caused by bilateral giant tonsilloliths. *J Chin Med Assoc* 2011; 74: 329-331.
9. Srivastava PR, Warhekar AM, Phulambrikar T, Wanjar PV, Srivastava R. Panoramic Radiographic Appearance of Giant Bilateral Tonsilloliths. *J Clin Diagn Res* 2016; 7: ZJ10-ZJ11.
10. Silvestre-Donat FJ, Pla-Mocholi A, Estelles-Ferriol E, Martinez-Mihi V. Giant tonsillolith: Report of a case. *Med Oral Patol Oral Cir Bucal*. 2005; 10: 239-242.