

Mixed epithelial and stromal tumor of the kidney on ¹⁸F-FDG PET/CT in a 21-year-old female

Jin-Ling Tian, MD, Bang-Ping Cui, MD.

ABSTRACT

يعد الورم الطلائي المختلط والورم السَدَوِيّ للكلَى (MESTK) ورم نادر يتكون من نسيجٍ سطحيّ وَخِلَالِيّ. في التصوير الإشعاعي، تظهر الكيسات صلبة ومتينة، ومن الصعب التمييز بين MESTK والأورام الكيسية الكلوية. التشخيص النهائي للـ MESTK يعتمد على علم الأمراض. نستعرض في هذا التقرير حالة MESTK نادرة شخصت لدى امرأة تبلغ من العمر ٢١ عاماً. نستعرض هنا ¹⁸F-FDG PET / CT والتصوير مُقَطِعِيّ مُحَوَسَّب لـ MESTK، والتي يمكن أن توفر معلومات مفيدة لتشخيص أورام الكلَى الكيسية المختلفة عنها والتّصنيف قبل الجراحة للورم

Mixed epithelial and stromal tumor of the kidney (MESTK) is a rare tumor composed of epithelium and interstitium. In radiological imaging, the masses are cystic and solid, and it is difficult to distinguish MESTK from renal cystic lesions. A final diagnosis of MESTK depends on pathology. We report this rare case of MESTK that was diagnosed in a 21-year-old woman. ¹⁸F-labeled fluoro-2-deoxy glucose (¹⁸F-FDG) positron emission tomography (PET)/computerized tomography (CT) and contrast-enhanced computerized tomography features of MESTK are presented, and could potentially provide useful information for the differential diagnoses of cystic renal neoplasms and preoperative staging of the tumor.

Saudi Med J 2019; Vol. 40 (5): 499-502
doi: 10.15537/smj.2019.5.24177

From the Department of Nuclear Medicine, Yichang Central People's Hospital, Yichang Hubei, China.

Received 12th February 2019. Accepted 16th April 2019.

Address correspondence and reprint request to: Dr. Bang-Ping Cui, Department of Nuclear Medicine, Yichang Central People's Hospital, Yichang Hubei, China. E-mail: yccb@126.com
ORCID ID: <https://orcid.org/0000-0003-0570-6945>

Mixed epithelial and stromal tumor of the kidney (MESTK) is a relatively rare renal tumor, which often occurs in perimenopausal women.^{1,2} It is rarely reported in literature, and even less reported in ¹⁸F-labeled fluoro-2-deoxy glucose (¹⁸F-FDG) positron emission tomography (PET)/computerized tomography (CT). The patient we reported was a 21-year-old young woman. The tumor was found on physical examination and confirmed to be MESTK by surgical resection.

The objective of the study is to report a rare case and provide possible diagnostic suggestions for clinical and imaging diagnosis.

Case Report. Patient's information. The patient is a 21-year-old female and the tumor of the kidney was unexpectedly found with no obvious clinical symptoms during a physical examination.

Clinical findings. Renal function and tumor markers were normal, and she had no family history of kidney disease. She underwent an enhanced CT scan, and the possibility of kidney cancer was considered. She therefore subsequently underwent a preoperative ¹⁸F-FDG PET/CT examination.

Diagnostic assessment. Axial enhanced abdominal CT showed a mass of 46×56×81 mm in the lower pole of the left kidney that was composed of solid and cystic components. A heterogeneous delayed enhancement was found in this mass (Figure 1A-1C, white arrow). ¹⁸F-labeled fluoro-2-deoxy glucose PET/CT imaging showed mild FDG uptake in the mass of the left kidney and no abnormal foci in other locations in MIP (Figure 2A-2G). Delayed abdominopelvic PET/CT scan still revealed mild FDG uptake in the mass (Figure 2H-2J).

Disclosure. Authors have no conflict of interests, and the work was funded by the Yichang Health Scientific Guidance Project, Yichang Hubei, China (No: k17-05).

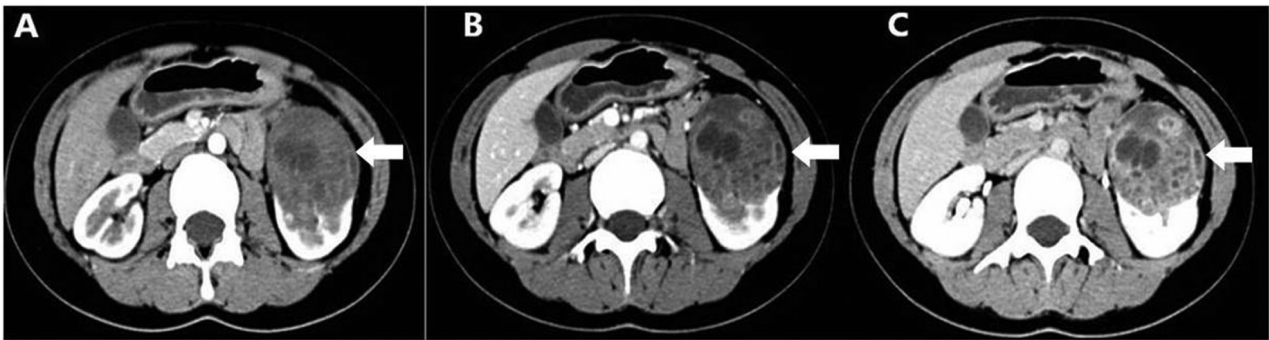


Figure 1 - Axial enhanced abdominal CT imaging (A-C): a mass of 46×56×81 mm in the lower pole of the left kidney (arrow) that was composed of solid and cystic components. A heterogeneous delayed enhancement was found in this mass.

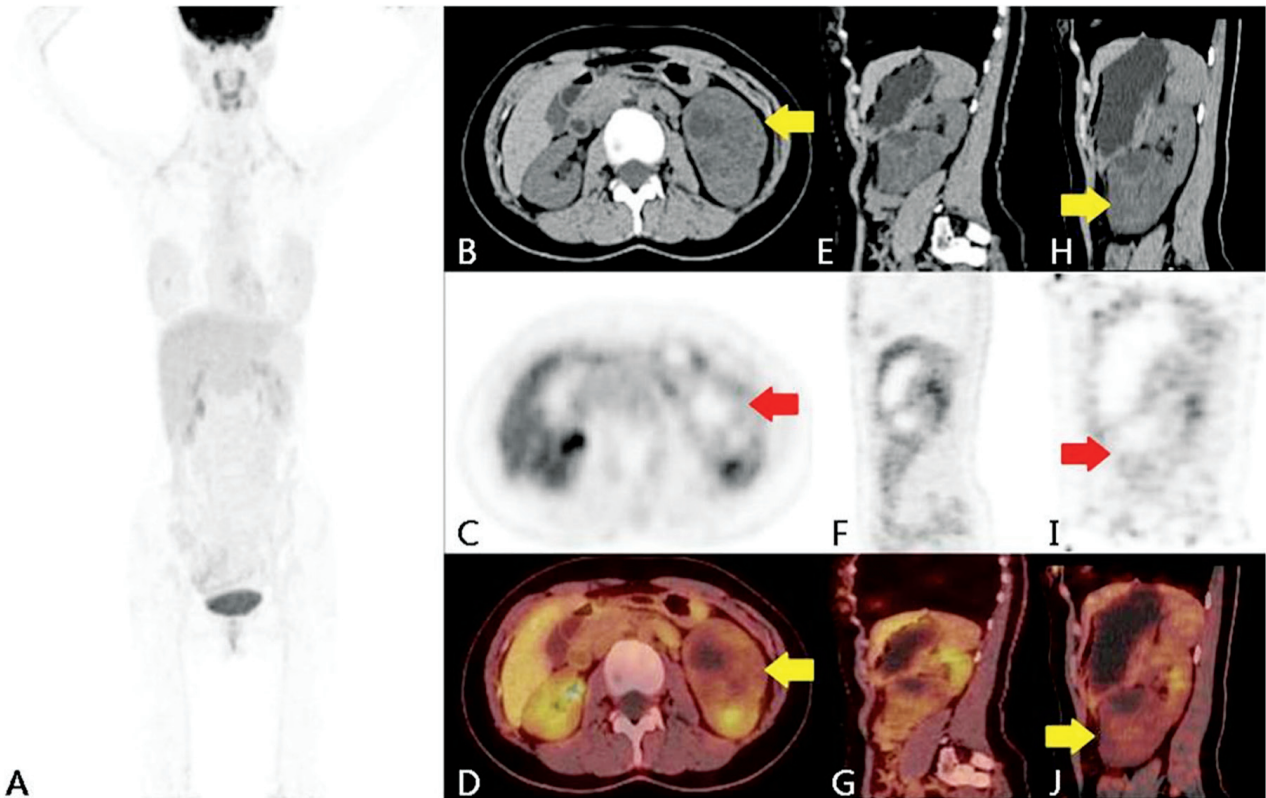


Figure 2 - ¹⁸F-labeled fluoro-2-deoxy glucose imaging (A-J) a mild FDG uptake (SUVmax 2.6) in the mass of the left kidney (arrow), delayed abdominopelvic PET/CT scan showed still mild FDG uptake (SUVmax 1.8) (H-J).

Therapeutic intervention. She underwent a left radical nephrectomy.

Follow-up and outcomes. Subsequent surgical pathology revealed MESTK with Ki-67 of approximately 3%. The immunohistochemical analysis was positive for estrogen receptor and progesterone receptor in tumor tissues, and it was negative for inhibin (Figure 3A-3D). The patient recovered well after surgery. Figure

4 represents the timeline from patients disease process.

Discussion. Mixed epithelial and stromal tumor of the kidney is a rare renal tumor and is more common in perimenopausal women. Mixed epithelial and stromal tumor of the kidney has no pathognomonic imaging features,¹ and preoperative diagnosis is very difficult.³ This patient was a young female with no obvious

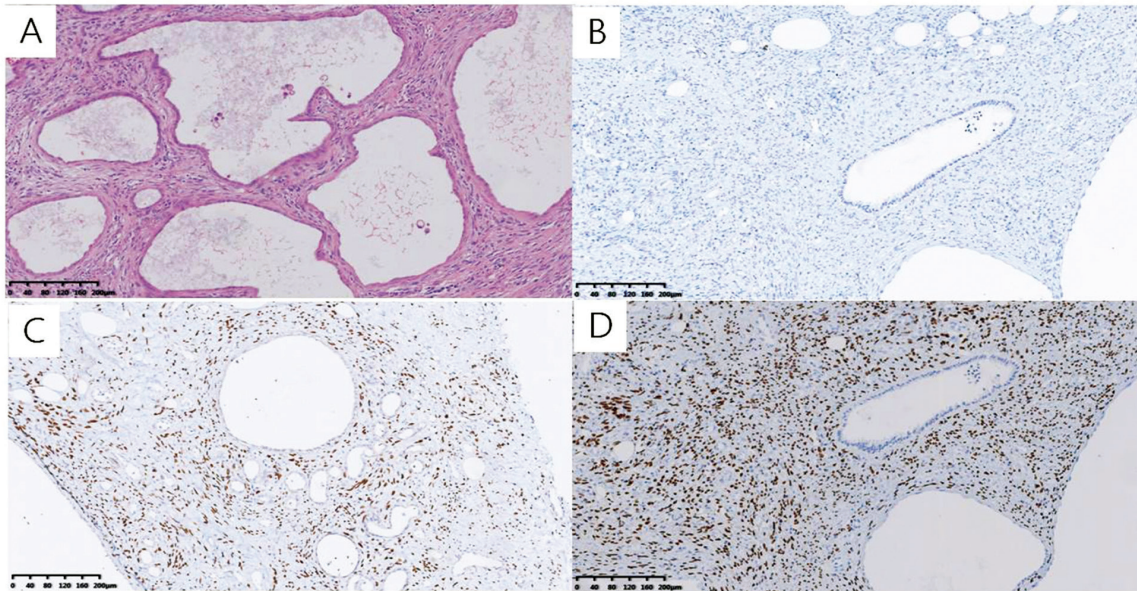


Figure 3 - The immunohistochemical showing A) hematoxylin and eosin is positive, B) negative findings for inhibin, C) positive for estrogen receptor, and D) progesterone receptor in tumor tissues (A-D, original magnification ×10).

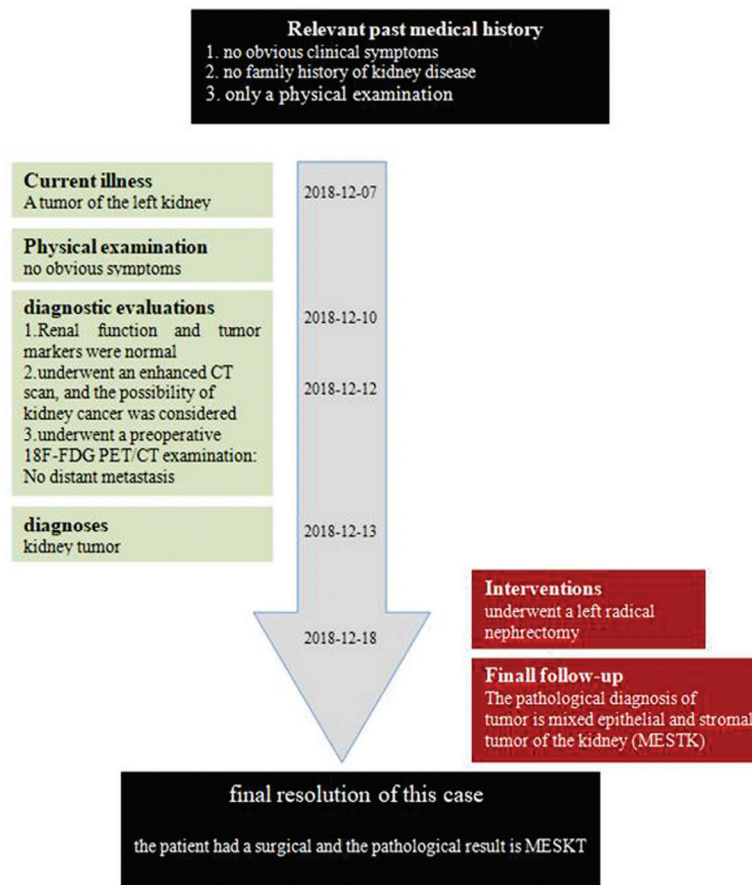


Figure 4 - Timeline summarizing the patient's past medical history, current illness, physical examination, diagnostic evaluations, diagnosis, interventions, final follow-up and the final resolution of the case. ¹⁸F-FDG = ¹⁸F-labeled fluoro-2-deoxy glucose.

clinical symptoms and no family history. Computerized tomography enhancement showed some characteristics, but the preoperative diagnosis was not clear. ¹⁸F-labeled fluoro-2-deoxy glucose PET/CT whole-body scanning, provides preoperative staging information and allows patients to choose reasonable treatment options. Our report was consistent with that of Kalra et al,⁵ suggesting that the clinical manifestations of this tumor was non-specific, and it was a rare cystic and solid tumor. Preoperative diagnosis of MESTK is difficult, and the final diagnosis depends on pathological diagnosis. However, only one case of MESTK reported on ¹⁸F-FDG PET/CT was identified in a search of PubMed² and it was also reported that the metabolism of this tumor was not very high, they reported the SUVmax was 2.8. Our study is consistent with the results of some studies.^{6,7}

In conclusion, CT enhancement can provide some information for the diagnosis of renal cystic masses and ¹⁸F-FDG PET/CT whole-body imaging has certain value in the selection of treatment options.

Acknowledgment. We would like to thank Chong Yin, radiologist, for reviewing the scan images and to Yu-fei Liu, histopathologist, for reviewing the histopath. We would like to thank the American Journal Experts for English language editing.

References

1. Simpson E, Koppisetty S, Alessio RC, Kumar A. Mixed epithelial and stromal tumour of the kidney. *BMJ Case Rep* 2015; 2015: bcr2015209373.
2. Li C, Tian Y, Shen M, Wen B, He Y. Mixed epithelial and stromal tumor of the kidney mimicking malignancy on ¹⁸F-FDG PET/CT in a patient with breast cancer. *Clin Nucl Med* 2018; 43: e239-e241.
3. Tsai SH, Wang JH, Lai YC, Chang YH, Chung HJ, Chang LS. Clinical-radiologic correlation of mixed epithelial and stromal tumor of the kidneys: cases analysis. *J Chin Med Assoc* 2016; 79: 554-558.
4. Yang C, Wang J, Du H, Chen M, Zhu X, Zhou J. Mixed epithelial and stromal tumor of the kidney: a rare case report and review of the literatures. *Int J Clin Exp Med* 2015; 8: 14180-141803.
5. Kalra S, Manikandan R, Dorairajan LN. Giant renal mixed epithelial and stromal tumour in a young female: a rare presentation. *J Clin Diagn Res* 2015; 9: XD01-XD02.
6. Arriola AGP, Taylor BL, Ma S, Malkowicz SB, Lal P. Malignant mixed epithelial and stromal tumor of the kidney with 2 simultaneous renal carcinomas in a male patient: case report and review of the literature. *Int J Surg Pathol* 2018; 26: 56-63.
7. Wang Y, Yuan J, Wang J, Fu Q. Mixed epithelial and stromal tumor of the kidney: report of a rare case and review of literature. *Int J Clin Exp Pathol* 2015; 8: 11772-11775.