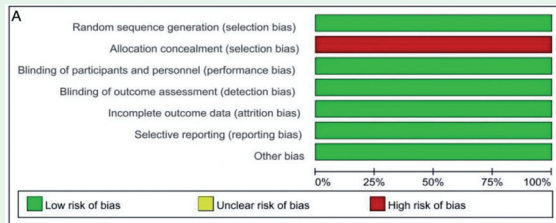


SYSTEMATIC REVIEW

Effect of laparoscopic intracorporeal reinforcing sutures to prevent anastomotic leakage. *A meta-analysis*



The Cochrane risk of bias assessment tool was used to evaluate the included articles' quality. A) Risk of bias graph

Wang et al assess a total of 3147 individuals on the effectiveness of reinforcing sutures after surgery for rectal cancer and its associated impact on postoperative recovery. From inception to 2024, the literature search was conducted using a variety of databases, including PubMed, the Chinese biomedical literature database, Wanfang, EMBASE, the Cochrane Library, VIP, and China National Knowledge Infrastructure, to identify relevant articles. A total of 3147 individuals were identified, with 1512 receiving reinforcing sutures and 1635 not. The occurrence of AL can be greatly decreased through the use of a laparoscopic approach for anastomotic reinforcement, which may be a better option after radical surgery for rectal patients.

see page 9

ORIGINAL ARTICLES

Development and validation of a nomogram to predict survival after neoadjuvant chemotherapy in elderly women with triple-negative invasive ductal breast cancer. *A SEER population-based study*

Gao et al verify a nomogram for a total of 382 patients with post-neoadjuvant chemotherapy survival predication in elderly women with triple-negative invasive ductal breast cancer. Elderly patients diagnosed as triple-negative invasive ductal breast cancer between 2019-2000 were screened from surveillance, epidemiology, and end results database. Depending on the post-neoadjuvant chemotherapy pathological response, they were assigned to the complete or non-complete response group. Inter-group clinicopathological characteristics and disease-specific and overall survivals were compared. The training cohort included 196 patients and the validation cohort included 82 patients. A total of 7 variables (age, race, tumor location, tumor-node-metastasis stage, summary stage, receipt of surgery, and response to neoadjuvant chemotherapy) were integrated to construct a survival prediction nomogram. In elderly women with triple-negative invasive ductal breast cancer, post-neoadjuvant chemotherapy pathological complete response could indicate improved disease-specific survival.

see page 43

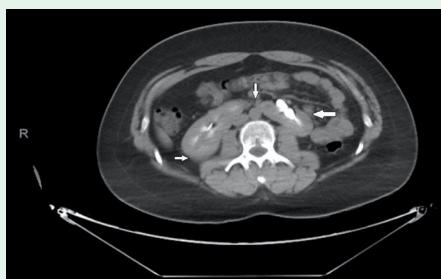Oncological surgical outcomes for colorectal cancer surgery with loco-regional anesthesia. *A feasibility study*

Marthi et al evaluate 53 patients who underwent mesocolicomesorectal surgery under regional anesthesia at Ankara Bilkent City Hospital, Ankara, Turkey, between May 2019 and May 2023. All the patients had clear proximal, distal, and circumferential surgical margins. The median number of lymph nodes removed was 23.45 (min-max: 3-97). When patients (n=24) who received neoadjuvant therapy were excluded, an insufficient number (<12) of lymph nodes were removed in 3 (7.69%) patients. A total of 3 patients died postsurgery, resulting in a 30-day mortality rate of 5.6%. For elderly and comorbid individuals with colorectal cancer, regional anesthesia can be used to carry out surgery with oncological principles.

see page 59

CASE REPORT

A rare case of a horseshoe kidney with a single left-sided ureter presented with recurrent urinary tract infection



Axial section of computed tomography urogram with a delayed film of a 27-year-old Saudi male. The section shows fused kidneys in the midline (a horseshoe kidney) (white arrows). The contrast appears bright white in the renal pelvis.

Ayed et al present a 27-year-old male patient presented with mild recurrent lower abdominal pain associated with dysuria. No history of renal disease. Laboratory investigations revealed red blood cells (RBC), white blood cells (WBC), and bacterial growth in the urine. A CT urogram showed an Horseshoe kidney (HSK) with a unilateral left-sided ureter. The patient was diagnosed with a urinary tract infection (UTI) and managed with regular follow-up. An HSK with a unilateral left-sided normally implanted ureter is rare. The present case of HSK was associated with recurrent UTI, which was managed accordingly.

see page 102