

REVIEW ARTICLE

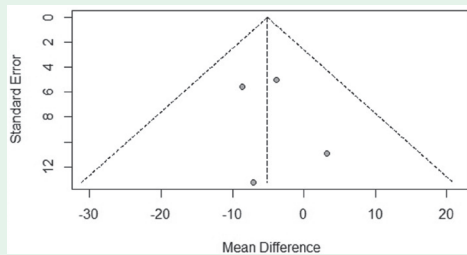
Effects of antidiabetic drugs on the level of serum uric acid in patients who have type 2 diabetes

Wang & Wang describes the effects of multiple antidiabetic drugs on the serum uric acid (SUA) level and their possible mechanisms of action in patients with type 2 diabetes mellitus (T2DM). The results show that sodium glucose cotransporter-2 inhibitors (SGLT2is), thiazolidinediones, metformin, and linagliptin decreases the SUA; insulin, sitagliptin, and alogliptin increases the SUA; and glucagon-like peptide-1 receptor agonists (GLP-1 RAs), sulfonylureas, and alpha-glucosidase inhibitors have little effect on the SUA. Sodium glucose cotransporter-2 inhibitors appear to have the greatest effect on lowering SUA, possibly because they reduce pentose phosphate pathway metabolism and increase the renal excretion of urate by altering renal tubular uric acid transporters. They concluded that SGLT2is, among all antidiabetic drugs currently used, appeared to be the most promising therapeutic option for T2DM patients with hyperuricemia.

see page 213

SYSTEMATIC REVIEW

Effectiveness of social skills training interventions for children with autism spectrum disorder. *A systematic review and meta-analysis*



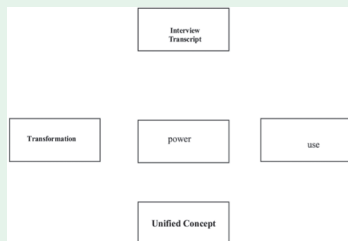
Funnel plot of social skills training interventions (4 studies included)

Alahmari et al evaluate the effectiveness of social skills training (SST) interventions for children with autism spectrum disorder (ASD). A systematic review and meta-analysis is carried out to identify relevant studies published between 2000-2023. A total of 17 studies are included in the meta-analysis. The overall effect size for SST interventions is 0.28-0.60 (95% confidence interval: [0.23-0.41]), indicating a small to moderate effect. Social skills training interventions are effective in improving a range of social skills, including social communication, reciprocity, and joint attention. They concluded that social skills training interventions demonstrate modest to moderate effectiveness in improving social skills in children with ASD, with outcomes varying depending on intervention type, participant characteristics, and implementation fidelity. While SST interventions offer potential benefits, they should be considered as one component of a broader, individualized treatment plan for children with ASD, rather than a standalone solution.

see page 226

ORIGINAL ARTICLE

Understanding artificial intelligence through the eyes of future nurses. *Insights from nursing students*



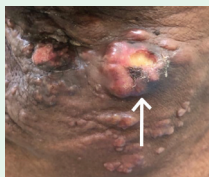The interrelationship among the core themes

Alenazi & Al-Anazi explore nursing students' perceptions and understanding of artificial intelligence (AI), aiming to identify and address critical knowledge gaps to support effective integration into educational practices. An exploratory qualitative study is carried out using semi-structured interviews with 20 nursing students from King Saud University, Riyadh, Saudi Arabia, in October 2023. Data collection focus on their definitions, conceptualizations, and perspectives regarding AI in healthcare. A total of 3 key themes emerge: I) transformation, where AI represents a shift in nursing education from traditional methods to technological integration; II) power, viewing AI as a driver of knowledge creation and scientific advancement; and III) use of technology, focusing on AI applications to enhance efficiency, automate tasks, and augment human abilities across sectors. They concluded that the need to integrate AI-related content into nursing curriculum, preparing students for its application in healthcare. These insights emphasize AI's role in shaping the future of nursing education and practice.

see page 238

CASE REPORT

Cutaneous metastasis of signet ring cell adenocarcinoma of the colon



Large ulcerative tumor 7.7 cm in the left axilla

Alamri et al present a unique case of cutaneous metastasis of signet ring adenocarcinoma. A 65-year-old Saudi male sought medical advice in July 2020, after developing nausea, vomiting, abdominal pain, and constipation. Histopathology confirmed the diagnosis of mucinous adenocarcinoma of the left colon, and staging was determined as PT3N2Mx in August 2020. The patient presented with generalized asymptomatic subcutaneous nodules 2 years after primary tumor diagnosis. Skin metastasis appeared 3 months before the liver and lung metastasis. However, the patient died 4 months later. They concluded that clinicians should observe signs of distant metastasis of colorectal cancer to enhance survival and improve outcomes.

see page 316