

# Post carotid endarterectomy seizure

Hussein M. Rabee, FRCS, MD, Nabil M. Aly, MRCP, Ahmed M. Ahmed, FRCS.

---

## ABSTRACT

Post carotid endarterectomy seizure is a known clinical presentation in patients who suffer from hyperperfusion syndrome. This case focuses on the importance of identification of high risk patients for developing this syndrome and delaying their discharge from the hospital after successful carotid endarterectomy.

**Keywords:** Carotid, seizure, hyperperfusion.

Saudi Medical Journal 2000; Vol. 21 (10): 977-978

---

**S**ymptomatic significant carotid artery stenosis (>70%) is the main indication of carotid endarterectomy (CEA). Hyperperfusion syndrome (HS) after surgical revascularization is an uncommon but potentially serious complication and there have been only a few studies on factors that precipitate hyperperfusion after CEA.<sup>1</sup> Low cerebral blood flow (CBF) and poor cerebral perfusion reserve are among the factors implicated in the production of HS.<sup>1</sup> Other risk factors include severe hypertension, especially during the post-operative period, and high grade internal carotid artery stenosis although, some studies suggested that even normotensive, neurologically intact patients without demonstrable cerebral infarction or post-operative hyperperfusion may suffer cerebral hemorrhage after the relief of high grade carotid artery stenosis.<sup>2</sup>

**Case Report.** A controlled hypertensive 65 year old female presented with completely recovered right sided hemiparesis. Duplex scan showed 90% stenosis of the left internal carotid artery and an occluded right internal carotid artery. She underwent left internal carotid endarterectomy 5 months post stroke under general anesthesia. Stump pressure was 32mmHg and intraoperative shunt was used. Blood pressure was well controlled during the procedure

and she had an uneventful recovery. Aspirin was started on the first post-operative day as well as anti-hypertensive medications. She was discharged home 4 days after the operation. Three days later, she came to the emergency room suffering from severe temporal headache, seizure and left wrist contusion when she fell down during the fits. Blood pressure was 200/100mmHg. The patient was admitted and computerized tomography (CT) brain showed a hemorrhagic area in the left temporal lobe with a picture of diffuse edema involving the left brain hemisphere. Carotid duplex revealed patent carotid arteries at the operation sites (Figure 1). The patients' complaints disappeared gradually over 3 days and high blood pressure was controlled. A posterior slab was advised by an orthopedic surgeon for 5 weeks to recover from the wrist contusion.

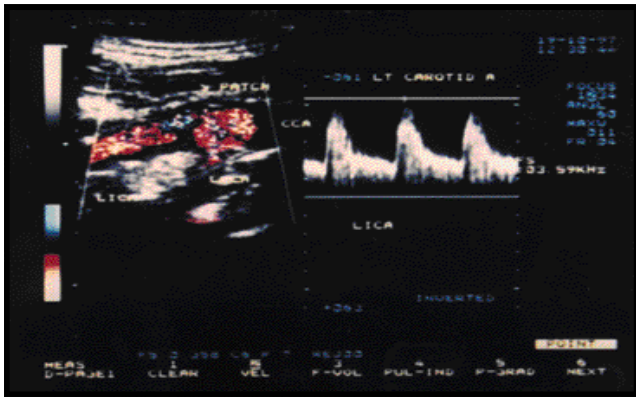
**Discussion.** Several attempts have been made to identify patients who are at risk of developing HS by pre-operative transcranial Doppler (TCD) to assess the collateral blood flow and intra-operative monitoring using somatosensory evoked potentials (SEP), electroencephalogram (EEG) and TCD to assess the regional CBF and to detect any intra arterial emboli. Transcranial Doppler and acetazolamide provocation test may be used to assess

---

From the Division of Vascular Surgery, Department of Surgery (Rabee), King Khalid University Hospital, Riyadh, Kingdom of Saudi Arabia, Department of Medicine, (Ahmed, Aly), Liverpool University Hospital, Liverpool, United Kingdom.

Received 29th April 2000. Accepted for publication in final form 5th June 2000.

Address correspondence and reprint request to: Dr Hussein M. Rabee, Assistant Professor & Consultant Vascular Surgeon, King Khalid University Hospital, PO Box 7805, Riyadh 11472, Kingdom of Saudi Arabia. Tel. +966 (1) 467 1589. Fax. +966 (1) 467 9493. E-mail: hmrabee@ksu.edu.sa



**Figure 1** - Duplex scan shows patent carotid arteries at the operation site.

the cerebral perfusion reserve.<sup>3</sup> The usefulness of TCD as an intraoperative monitor was limited by a high failure rate in comparison to SEP. Those patients with contralateral carotid artery occlusion and poor recruitment of collateral flow via the Circle of Willis are more vulnerable for post CEA hyperperfusion syndrome. Stenosis of 95% to 99% carries the highest risk for developing HS.<sup>4</sup> At operation, they have the highest pressure gradients over stenosis and the lowest stump pressure.<sup>3</sup>

The onset of the clinical features of HS are usually sudden, between the 4th and 7th days post operatively and most of these will resolve within 2 weeks. The clinical features of HS include severe headache, seizures, confusion, local neurological deficit (stroke), and intracerebral hemorrhage (IH). The incidence of hyperperfusion-related seizure varies from 0.4% to 10% and usually occurs within the first 10 post operative days, often preceded by severe, ipsilateral frontotemporal or periorbital headaches.<sup>4</sup> Post endarterectomy headache occurs in the first few days after surgery and usually is of moderate severity and bilateral, but in most cases requires no treatment. The most widely accepted theory to explain the pathogenesis of HS is the disturbance of cerebral autoregulatory mechanisms following correction of high grade stenosis with a subsequent increase in perfusion pressure and uncontrolled hyperperfusion.<sup>5</sup> Intracerebral hemorrhage tends to be secondary to progressive microcirculatory changes. The onset of intracerebral bleeding ranges from just after operation to 17 days

with a mean onset time of 4 to 5 days. Jansen et al have shown that patients with a >100% increase in middle cerebral artery velocity (MCAV) following restoration of flow were significantly more likely to suffer late hemorrhage than patients with lesser increases in MCAV.<sup>6</sup> Thus, analysis of ultrasound Doppler waveforms, obtained distal to the stenosis may identify patients at risk. Nielsen et al used to allow them to stay in the intensive care unit for intraarterial blood pressure monitoring the first 24 hours post CEA and blood pressure is kept at normal to subnormal levels.<sup>7</sup>

From this case, we would like to remind the surgeon about the possibility of developing post carotid endarterectomy hyperperfusion syndrome in hypertensive patients with tight carotid artery stenosis and defective cerebral circulation after discharging these patients early from hospitals. Anti-hypertensive therapy should probably be aggressive during the first post-operative week. The tendency for short hospital stay should not lead to underestimation of the potential hazards of hyperperfusion related seizure following carotid endarterectomy.

## References

1. Yoshimoto T, Houkin K, Kuroda S, Abe H, Kashiwaba T. Low cerebral blood flow and perfusion reserve induce hyperperfusion after surgical revascularization: Case report and analysis of haemodynamics. *Sur Neurol* 1997; 48: 132-138.
2. Lepojarvi M, Peltola T, Ylonen K, Juvonen T, Pokela R, Karkola P. Cerebral haemorrhage after carotid endarterectomy. *Ann Chir Gynae* 1996; 85: 23-26.
3. Sbarigia E, Speziale F, Giannoni MF, Colonna M, Panico MA, Fiorani P. Post carotid endarterectomy hyperperfusion syndrome. *Eur J Vasc Surg* 1993; 7: 252-256.
4. Penn AA, Schomer DF, Steinberg GK. Imaging studies of cerebral hyperperfusion after carotid endarterectomy. Case report. *J Neurosurg* 1995; 83: 133-137.
5. Jorgensen LG, Schroeder TV. Defective cerebrovascular autoregulation after carotid endarterectomy. *Eur J Vasc Surg* 1993; 7: 370-379.
6. Jansen C, Sprengers AM, Moll FL, Vermeulen FE, Hamerlijnck RP, Van Gijn J et al. Prediction of intracerebral haemorrhage after carotid endarterectomy by clinical criteria and intraoperative transcranial Doppler monitoring. *Eur J Vasc* 1994; 8: 303-308.
7. Nielsen TG, Sillesen H, Schroeder TV. Seizure following carotid endarterectomy in patients with severely compromised cerebral circulation. *Eur J Vasc* 1995; 9: 53-57.