

# Frequency of tracheobronchial foreign bodies in children and adolescents

Mohammad A. Siddiqui, FRCS, Ahmed H. Banjar, FRCS, Sami M. Al-Najjar, MD,  
Mohammad M. Al-Fattani, MRCP, Magdi F. Aly, FRCS.

---

## ABSTRACT

**Objective:** The problem of foreign body aspiration in the community has been studied and compared with other reports.

**Methods:** We have retrospectively studied patients who had bronchoscopy for suspected foreign bodies in the tracheobronchial tree, attending or referred to Al-Noor Specialist Hospital, Makkah over a period of 3 years from May 1996 to May 1999.

**Results:** The total number of patients was 94 (62 male and 32 female). Ages ranged from 4 months to 45 years (mean age 3.77 years), 85% of children being under the age of 5 years. One hundred bronchoscopies (6 repeat bronchoscopies) and one thoracotomy were carried out. Foreign bodies were removed from 60 patients (64%). Six (10%) did not have any definite history, while 15 patients (21%) with definite history of foreign body aspiration had negative bronchoscopy. An aspirated Fis-Fis (Alfalfa, Lucerne) seed accounted for more than one-third of all

foreign bodies. The most frequent symptoms, signs, radiological findings and site of foreign body lodgment in the tracheobronchial tree are discussed.

**Conclusions:** We conclude that a negative history, clinical examination and chest x-ray do not necessarily exclude aspirated foreign body material. Bronchoscopy is the most effective diagnostic and therapeutic modality to prevent complications related to neglected foreign body aspiration. In addition to children, teenagers and adolescents are also not immune to this problem. We recommend early referral to an appropriate hospital on suspicion or if symptoms persist. However, preventive measures, remain the best means of protecting these children.

**Keywords:** Foreign bodies, bronchus, children, bronchoscopy.

**Saudi Medical Journal 2000; Vol. 21 (4): 368-371**

---

We are presenting our experience of a number of cases with aspiration of varieties of foreign bodies (FBs) among different age groups and different nationalities residing or visiting the holy city of Makkah. This study highlights various presentations and management of foreign body aspiration (FBA) as well as emphasizing the continued need for increased awareness on the part of the parents and medical practitioners of the need of early referral if a FB is suspected.

**Methods.** A retrospective study of patients with FBs in the tracheobronchial tree attending or referred

to Al-Noor Specialist Hospital Makkah was carried out. The duration of the study was 3 years (from May 1996 to May 1999). The demographic characteristics, clinical presentation, chest radiographic appearance, types of FBs and the sites of their lodgment in the tracheobronchial tree were noted. All FBs were removed under general anesthesia using thiopentone sodium, oxygen, nitrous oxide or halothane delivered through a ventilating channel of bronchoscope. Suxamethonium (a short acting muscle relaxant), atropine and hydrocortisone were used to prevent bradycardia and bronchospasm. A storz rigid ventilating bronchoscope with

---

From the Thoracic Surgery Unit (Siddiqui, Banjar, Aly) and the Pediatric Department (Al-Najjar, Al-Fattani), Al-Noor Specialist Hospital, Makkah, Kingdom of Saudi Arabia.

Received 17th October 1999. Accepted for publication in final form 29th January 2000.

Address correspondence and reprint request to: Dr. Ahmed H. Banjar, PO Box 6834, Makkah, Kingdom of Saudi Arabia. Tel/Fax No. +966 (2) 5280527. E-mail: Saad\_sa@Yahoo.com

**Table 1** - Foreign body bronchus according to age.

Age	Number of patients
0 - < 1 year	14
1 - 2 years	45
> 2 - 5 years	22
> 5 - 12 years	4
> 12 - 26 years	8
45 years	1

**Table 2** - Types of foreign bodies extracted.

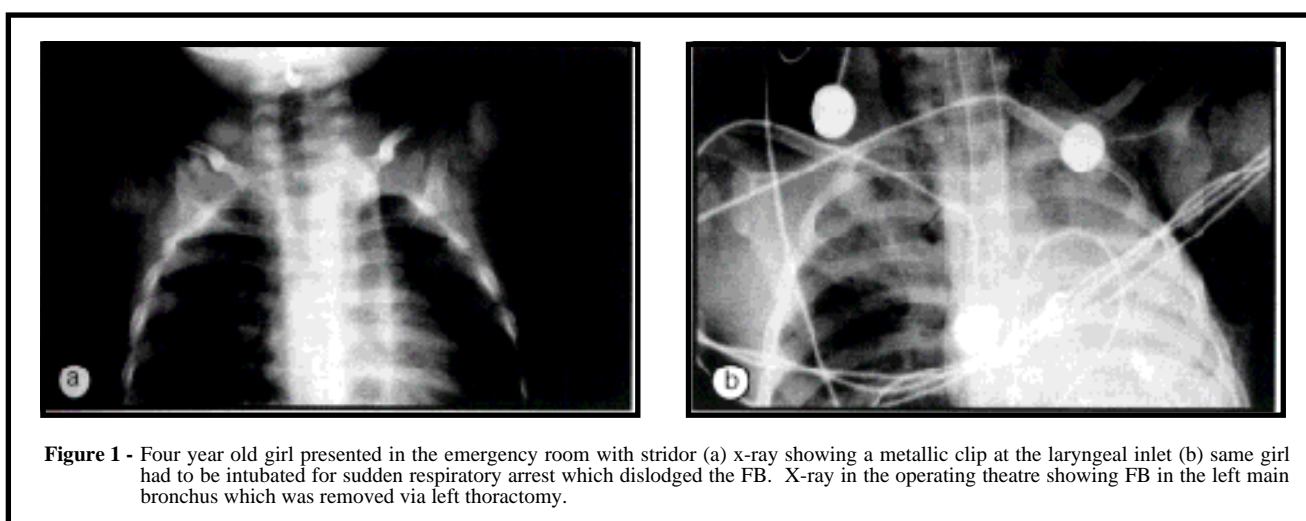
Types of foreign bodies	No.
Fis Fis seed (alfalfa, lucerne)	20
Metallic	11
Peanuts	9 (+2*)
Plastic	5
Watermelon seed	4
Bone piece	2
Nut Shell	2
Tooth	1
Betel nut	1
Carrot	1
Corn seed	1
Sunflower seed	1
Marble bead	1
Meat and vegetable	1
<b>TOTAL</b>	<b>60 (+2*)</b>
* Spontaneous expulsion	

fiberoptic light source was used in all cases. In a few cases of older children a pediatric fiberoptic bronchoscope was used as an additional diagnostic help. In one case a thoracotomy had to be performed for removal of foreign body. As for the technique of bronchoscopy, the bronchoscope was routinely introduced after direct laryngoscopy using the anesthetist laryngoscope (Mackintosh).

**Results.** The total number of patients was 94 including 62 males and 32 females. Ages ranged from 4 months to 45 years with the majority (85%) of children being under the age of 5 years (Table 1). Among them 61 were Saudis and 33 were non-Saudis. Ninety nine rigid bronchoscopies and 1 thoracotomy were carried out with the additional help provided by fiberoptic bronchoscope in about 20% of cases. One patient had fiberoptic bronchoscopy

through endotracheal tube as he was ventilated for severe head injury resulting in inhalation of partial teeth denture which was lodged in the left main bronchus. Persistence of symptoms and suspicion led to the use of repeat bronchoscopy in 6 patients and one patient required thoracotomy for impacted metallic FB in the left main bronchus complicated by bronchial tear, later she developed pneumothorax during an attempt at removal of sharp metallic FB requiring tube thoracostomy in the operating theatre (Figure 1).

Foreign bodies were removed from 60 patients (64%). There was no mortality but morbidity (9%) in the form of thoracotomy (n=1), post operative ventilation (n=5) because of bronchospasm and pneumothorax (n=2) was encountered. One of the patients developed pneumothorax as a complication of foreign body before bronchoscopy and the other



**Figure 1** - Four year old girl presented in the emergency room with stridor (a) x-ray showing a metallic clip at the laryngeal inlet (b) same girl had to be intubated for sudden respiratory arrest which dislodged the FB. X-ray in the operating theatre showing FB in the left main bronchus which was removed via left thoracotomy.

patient developed pneumothorax after bronchoscopy for removal of foreign body. An aspirated Fis-Fis (alfalfa, lucerne) seed accounted for one third (33%) of all foreign bodies followed by metallic foreign body, peanuts, and others (Table 2). FB location was distributed evenly to the right (n=24) and left (n=24) primary bronchi; tracheal FB was noted in 11 patients and in one patient FBs were removed from both left and right lower lobar bronchi. The most frequent symptoms were sudden onset of cough (65%) and wheezing/stridor (60%). Chest examination was clinically unremarkable in 17% and normal radiological appearance noted in 38% of the cases. The most common radiographic findings in order of frequency were radio-opaque (22%) shadow, localized atelectasis (18%), followed by hyperlucency (17%), consolidation (3%) and others (2%). The mean period between inhalation and removal of the foreign body was 9 days with a range of 1 hour to 3 months. Out of 60 positive bronchoscopies there was no definite history of FBA in 6 patients (10%) and in 15 patients (21%) out of 69 with definite history of FBA no FB was detected. We have removed two pieces of betel nuts from intermediate bronchus on routine bronchoscopy before surgery for a patient presented with right empyema thoracic.

**Discussion.** Despite several reports in the literature and emphasis on the dangers of FBA, it remains a persistent problem for young children all over the world. Foreign body aspiration is responsible for approximately 2,000 deaths a year in children under 6 years of age in USA,<sup>1</sup> and there is no evidence that the incidence is declining.<sup>2</sup> The reason seems to be multi-factorial. The age distribution, with the majority of patients between 12 and 48 months, has been attributed to poor chewing ability from a lack of posterior dentition, a tendency to put things into the mouth and a tendency to have frequent, vigorous, uninhibited inspirations when startled, laughing or coughing.<sup>3</sup> The community at large is not aware of the hazards of Fis Fis or peanuts (common FBs in our series apart from objects presented to small children. Many people in our community have the habit of eating the inside meat of roasted seeds (Fis Fis) after breaking the outer hard shell with their teeth. These seeds are being picked up by the children who introduced them into their mouths, resulting in aspiration. A solid object entering the pharynx elicits a startle response permitting the FB to enter the open larynx during forced inspiration.<sup>2</sup> Another factor is carelessness that may contribute to FBA in many ways, hasty eating and drinking habit, permitting children to play while eating or talking with food in the mouth, giving food such as Fis Fis and peanuts to young children.<sup>4</sup> The nearly 70% male preponderance appears to be one of the fixed mathematical constants of nature and

has been observed in other series.<sup>2,5</sup> It has been attributed to rougher and more adventurous play in male children<sup>2,3</sup> as well as the more curious and inquisitive nature of boys than girls.<sup>6</sup> Although the presentation of FBA may be variable, the triad of symptoms and signs, comprising of sudden onset of cough, wheezing and decreased air entry should alert the physician to the possibility of foreign body.<sup>7</sup> With large FBs, the net result can be acute upper airway obstruction and sudden death.<sup>8</sup> This has happened to one girl in our series but she was saved by immediate intubation. Most children with FBA, however, present with respiratory distress followed by cyanosis, cough and wheezing. Sudden appearance of wheeze in a child who has not previously manifested asthma should arouse a strong suspicion of the presence of a FB. Neglected FBs result in recurrent attacks of wheezing and may lead to pneumonitis, bronchiectasis and rarely empyema thoracis<sup>5</sup> as recorded in one adult in our series. Therefore, history of repeated chest infection or persistent lobar or segmental pneumonia not responding to antibiotics, demands investigation for FB. Radiological findings may vary from being diagnostic to totally unremarkable. Most aspirated FBs in our series (78%) as well as in all reported series were, unfortunately, radiolucent. Radiographic findings vary with the size of FB in relation to that of bronchus. We have noticed atelectasis (18%) with large FB, obstructive emphysema (17%) when FB acting as a valve or swinging mediastinum on fluoroscopy when there is partial obstruction on deep inspiration and expiration. The yield of positive chest x-rays can be enhanced by fluoroscopy and films taken both during deep inspiration and expiration. To induce deep respiration, it may be necessary to make the child cry by pinching him or her.<sup>5</sup> The unrecognized or missed FB is still common and constitutes 25% of cases.<sup>9</sup> More recently, computed tomography has been demonstrated to show occult tracheobronchial FBs.<sup>10</sup> The most important factor enabling early diagnosis remains a positive history of aspiration together with a high index of suspicion, the combination constituting an indication for bronchoscopy.<sup>11</sup> However, in our series a definite history of FBA was obtained in 90% of cases. Bronchoscopy through tracheostoma<sup>12</sup> and various non-endoscopic techniques (Hemlich or abdominal thrust maneuver) to relieve airway obstruction is extremely controversial.<sup>13</sup> Medical treatment prior to bronchoscopy, consisting of physiotherapy and postural drainage has been reported sporadically<sup>14</sup> but in a report by law and Koslorke<sup>15</sup> the success rate was only 25%, with efficacy of bronchoscopic removal exceeding 90%. With the advent of the pediatric storz endoscopic equipment, most FBs can be extracted successfully with minimal morbidity and mortality.<sup>16</sup> Concomitant use of fluoroscopy and

use of a Fogarty balloon catheter has been employed for successful extraction of more peripherally located FBs.<sup>17</sup> In our series, rigid bronchoscopy, with the additional diagnostic help by fiberoptic bronchoscope (20%) in older children, was successful in extracting all endoscopically visualized foreign bodies except one, a metallic clip which required thoracotomy for extraction. We observed that the type of FB extracted varied with the age of the patient. Organic foreign bodies like Fis Fis and peanuts were found below the age of 5 years. Plastic and metallic foreign bodies were encountered in older children and teenagers. One 45 year old gentleman had betel nuts removed from right intermediate bronchus. Similar to other reported series, FBs in our series were evenly distributed between the right and left bronchial trees.<sup>2,6</sup> This is felt to be due to symmetrical bronchial angles in children upto 15 years of age.<sup>18</sup> Time lag between the onset of symptoms and endoscopic removal of FB is directly proportional to the complications such as atelectasis, pneumonia, lung abscess and empyema thoracis. Organic foreign bodies are liable to evoke violent laryngotracheobronchitis and predispose to lung infection. There has been no improvement in the rapidity of diagnosis of FBA, in the last 20 years.<sup>19</sup> In our series the mean period between inhalation and removal of the FB was 9 days with a range of 1 hour to 3 months. These unnecessary delays can be circumvented by maintaining a high index of suspicion in children between the ages of 4 months and 5 years, presenting with a history suggestive of FBA. Physicians examining a child, for the first time, with a history suspicious of aspiration or unexplained wheezing should consider the possibility of FBA and resort to early endoscopic examination. We conclude that foreign body aspiration carries its hazards including morbidity and mortality,<sup>20</sup> therefore, early referral to appropriate hospital on suspicion should be made. A negative clinical examination and chest x-ray do not necessarily exclude aspirated FB material. Bronchoscopy is the most effective diagnostic and therapeutic modality due to the shortcomings of the history, physical examination and radiology. Preventive measures, however, continue to remain the best means of protecting these children. Furthermore public education is needed as regard to dangers of allowing young children to have Fis Fis or peanuts or leaving them unattended with small objects.

**Acknowledgments.** We thank Abdul Wahab Junaid for his technical assistance and Abdul Moez Saad and Seema Yunus for their help in preparation of the manuscript.

## References

1. Sandford CC. Aspirated foreign bodies in children. *Am Fam Physician* 1979; 20: 104-108.
2. Rothman BF, Boeckman CR. Foreign bodies in the larynx and tracheobronchial tree in children. A review of 225 cases. *Ann Otol Rhinol Laryngol* 1980; 89: 434-436.
3. Svensson G. Foreign bodies in the tracheobronchial tree. Special references to experience in 97 children. *Int J Pediatr Otorhinolaryngol* 1985; 8: 234-251.
4. El-Sayed Y, Ismail S. Foreign bodies in the tracheobronchial tree. *Saudi Medical Journal* 1996; 17: 73-77.
5. Kim IG, Brumitt WM, Humphry A, Siomra SW, Wallace WB. Foreign body in the airway: A review of 202 cases. *Laryngoscope* 1973; 83: 347-354.
6. Gupta A, Chopra K, Saha M, Khanna SK, Gupta RK, Narayanan PS et al. Foreign bodies in the tracheobronchial tree. *Indian Pediatrics* 1977; 14: 133-134.
7. Harboyan G, Nassif R. Tracheobronchial foreign bodies. A review of 14 years experience. *J Laryngol Otol* 1970; 403-412.
8. Abdulmajid OA, Ebeid AM, Motaweh MM, Kleibo IS. Aspirated foreign bodies in the tracheobronchial tree: report of 250 cases. *Thorax* 1976; 31: 635-640.
9. Al-Majed SA, Ashour M, Al-Mobeirek AF, Al-Hajjaj MS, Alzeer AH, Al-Kattan K. Overlooked inhaled foreign bodies: late sequelae and the likelihood of recovery. *Respir Med* 1997; 91: 293-296.
10. Burger PE, Kuhn JP, Kuhn LR. Computed tomography and the occult tracheobronchial foreign body. *Radiology* 1980; 133-135.
11. Moazam F, Talbert JL, Rodgers BM. Foreign bodies in the paediatric tracheobronchial tree. *Clin Pediatr* 1983; 22: 148-150.
12. Saijo S, Takasaka T, Takasaka T, Kawamoto K. Foreign bodies in tracheobronchial tree. *Arch Otorhinolaryngol* 1979; 225: 1-7.
13. Tucker GF, Holinger LD. Foreign bodies in the esophagus or respiratory tract. In: Paperella MM, Shumrick DA, eds. *Otolaryngology* 3. Philadelphia: WB Saunders Co 1980; 42: 2628-2640.
14. Burrington JD, Cotton EK. Removal of foreign bodies from the tracheobronchial tree. *J Pediatr Surg* 1972; 7: 119-122.
15. Law D, Kosloske AM. Management of tracheobronchial foreign bodies in children: A re-evaluation of postural drainage and bronchoscopy. *Pediatrics* 1976; 58: 362-367.
16. Moussalli H. How to remove a foreign body from the trachea and bronchial tree. *Br J Hosp Med* 1981; 25: 300-304.
17. Hight DW, Philippart AI, Hertzler JH. The treatment of retained peripheral foreign bodies in the paediatric airway. *J Pediatr Surg* 1981; 16: 694-699.
18. Cleveland RH. Symmetry of bronchial angles in children. *Radiology* 1979; 133: 89-93.
19. Inglis AF, Wagner DV. Lower complication rates associated with bronchial foreign bodies over the last 20 years. *Ann Otol Rhinol Laryngol* 1992; 101: 61-66.
20. Yagi HI. Foreign bodies in the tracheobronchial tree in Sudanese patients. *J R Coll Surg Edinb* 1997; 42: 235-237.