Case Report

Ankylosing spondylitis presenting with discitis

Reda A. Ebrahim, *MRCP(UK),* ***Nabeel I. Sarwani****, MD,* ***Sangam G. Kanekar****, MBCHB, DMRD.*

ABSTRACT

Ankylosing spondylitis is not an uncommon disease worldwide, yet is relatively rare in Bahrain. There is a typical pattern of joint involvement in cases of ankylosing spondylitis, but the presentation of discitis is rare. We present a case of a patient presenting with backache and was diagnosed to have discitis. The diagnosis of ankylosing spondylitis was made only after he was found to be Human Leukocyte Antigen-B27 positive. This is the first case report of ankylosing spondylitis presenting as discitis in Bahrain.

Keywords: Ankylosing spondylitis, discitis, Magnetic Resonance Imaging, Human Leukocyte Antigen, B27.

Saudi Medical Journal 2000; Vol. 21 (9): 884-886

Spondyloarthropathy constitutes of a group of inflammatory rheumatic diseases in which the major target of the inflammatory process is the enthesis, rather than the synovium as in rheumatoid arthritis. The enthesis represents the interface between tendous, capsules or ligaments and bone.[1] Ankylosing spondylitis (AS) is a disease of the young with age onset of mainly the second to the fourth decade.[2] It has a classical presentation with low backache, but could present with a myriad of other clinical manifestations.[3]

Case report. A 33 year old Bahraini male who presented to our hospital with a history of back pain, mainly in the midback (lower dorsal and upper lumbar). It was increasing in severity with time, persistent throughout the day, radiating to both flanks and was aggravated on spinal movements and lifting heavy loads. In addition, the patient had a mild fever and lethargy. On examination, his vitals signs were normal.

His spinal range of motion was also normal with pain. He had tenderness at the level of thoracic spine 11 and 12. Examination of other joints and systems were unremarkable. Blood investigation showed normal hemoglobin, normal white blood cell counts and an elevated ESR (96 mm/hr). Rheumatoid factor, anti-nuclear antibody, anti-dsDNA antibody were all normal. CRP was 20 (normal <10). Plain X-rays of the spine were unremarkable, but the patient continued to have backache. Magnetic resonance imaging (MRI) study revealed endplate irregularity in the region of T11-T12 with hyperintensity in the adjacent vertebral body and loss of disc height on T1-weighted images (Figure 1). These end-plates turned hypointense on T2-weighted images. An impression of query spinal infection was made, and the patient was started on IV antibiotics. Brucellosis and tuberculosis were excluded by serology, blood culture, chest X-ray and PPD skin test which were all negative for both diseases. During his hospital stay, the patient's condition did not improve. He started to develop new complaints of neck and shoulder pain, as well as right knee effusion. Aspiration of the knee was carried out twice which was always negative for Gram stain and culture, AFB and crystals. Synovial fluid glucose concentration was normal, protein was normal, as

From the Department of Medicine (Ali Ebrahim), Department of Radiology (Sarwani, Kanekar), Salmaniya Medical Complex, Manama, Bahrain.

Received 18th January 2000. Accepted for publication in final form 31st May 2000.

Address correspondence and reprint request to: Dr Reda Ali Ebrahim, Department of Medicine, Salmaniya Medical Complex, PO Box 12, Manama, Bahrain. Tel. 255 555/279 774. Fax. 275 612.

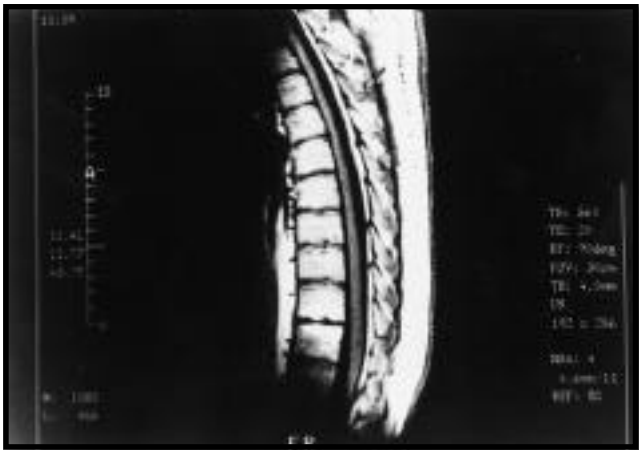

Figure 1 - T1 (TR 560 msec, TE 20 msec) weighted saggital section shows end-plate irregularity with disc height reduction at the level of T11-T12, and hyperintensity in adjacent vertebral bodies.

Figure 2 - PA view of sacro-iliac joints shows irregularity of joints on both sides, with sclerosis of the iliac bone.

well as polymorphs. Repeat ESR was 109 mm/hr with a white cell count still within normal limits. The patient's condition settled with conservative measures.

A month after his initial presentation, he attended the Out-patient Clinic, again having the same complaints. Physical examination revealed right sided quadriceps wasting, mild joint effusion of the right knee with decreased range of movement. Spine and other joints were normal, apart from local tenderness at T11-T12 level. NSAIDs were started with no relief of his complaints. Follow-up visit 3 weeks later showed more joints becoming involved with early morning stiffness for half an hour. At this point, a diagnosis of seronegative rheumatoid arthritis was made, and the patient was started on methotrexate, as well as NSAIDs and steroids. Skeletal survey was carried out and showed irregularity of sacro-iliac joints on both sides with sclerosis on the iliac side of the lower third (Figure 2).

These findings were suggestive of AS. HLA screening was carried out which revealed that he was HLA-B27 positive, and a bone scan revealed increased uptake of both sacro-iliac joints, costovertebral joints and the right knee. The same management was advised, in addition, to physiotherapy. Further questioning revealed that for the past 20 years, the patient had been complaining of low back pain in the buttock area, but was so used to it that he thought it was not worth mentioning. He also gave a history of redness of the eyes on and off with no loss of vision, and again, never sought any medical advice. Family history revealed that he has a 30 year old cousin, diagnosed to have classical ankylosing spondylitis and was HLA-B27 positive. Currently, the patient is managed with NSAIDs as necessary and weekly methotrexate and physiotherapy. He is seen regularly in out-patients with complete blood count, sedimentation rate and liver function test (LFT) as a monitor to his disease and medications. His LFT has continued to be normal and his ESR has returned to normal (10 mm/hr), he is back to full employment at his usual job, and complains of only occasional mild neck pain during lateral rotation.

Discussion. Ankylosing spondylitis is a disease which affects approximately 0.5 - 1% of the population. It tends to afflict males more than females, involving members of the younger age groups (20-30 years). The prevalence and distribution of this disease follows that of the HLA-B27 antigen with which AS is associated. Ankylosing spondylitis is an oligoarthropathy with asymmetric involvement of the joints. Larger joints are more involved than smaller ones, and lower limbs are affected more than the upper limbs. Sacro-iliac joint involvement is typically symmetrical with irregularity of the joint and iliac bone sclerosis with eventual fibrous or bony fusion of the joint. Spinal involvement typically starts in the lumbar region and ascends, with features of fusion of the vertebrae as a result of enthesopathy, leading to kyphotic deformity, and the development of pseudoarthroses.[2] Our patient presented with a discitis which is a known manifestation of AS, and was later found to be HLA-B27 positive. Discitis is a rare and uncommon finding in cases of AS.[4] Usually when it is present, AS has already been established for many years. Discitis may be asymptomatic or symptomatic with no real predictors available to determine why one patient may have symptoms while others do not. Symptomatic cases have a prevalence ranging

between 1-10% whereas no data is available regarding asymptomatic cases.[4] Our case is unusual as he presented with a history of localized low back pain only. In the clinical findings and laboratory results, and the absence of any history of a chronic illness, an initial diagnosis of spinal infection was thought most likely, and he was managed accordingly. Normal or near normal, plain radiographs in the early stages of discitis is well documented in the literature.[5,6] Other imaging modalities, such as bone scans and computerized tomography scans, offer better diagnostic yield with regards to sensitivity, but are not very specific and do not always grade the extent of the disease process. Magnetic resonance imaging, however, has been described as the imaging modality of choice for diagnosing spondylodiscitis with regards to sensitivity and specificity.[7] Findings early in the disease process, the extent of disease, as well as possible etiopathologies can all be better eluded to via MRI of the spine.[3] Magnetic resonance imaging study of our patient showed features typical of discitis with end-plate irregularity with a hyperintensity in the adjacent vertebral body and loss of disc height on T1- weighted images, and the end-plates turned hypointense on T2-weighted images. Features of spinal infection such as tuberculosis present with hypointensity on T1-weighted images and turn hyperintense on T2-weighted images. There may be associated pre or paraspinal soft tissue.[8] However, early features of this condition make it difficult to distinguish it from aseptic discitis. Tuberculous infection should be kept in mind when considering patients from the Middle East Region, as it is not an uncommon illness.

The etiology of discitis in cases of AS in not clear, and several studies have been carried out in an attempt to find out the possible cause or causes. One possibility is that the discitis is as a result of the enthesopathy of AS itself, while another theory is that it is a result of the presence of pseudoarthroses of the spine. There is data for and against both possibilities, and it could also be that both mechanism are involved in the disease process.[1] In our case, the MRI findings, high ESR, localized T11-12 tenderness and non-response to intravenous antibiotics make the discitis most likely to be due to AS inflammatory process.

In conclusion, young patients between the ages of 20 and 30 presenting with backache with features of discitis on plain X-rays or MRI who do not respond to conventional treatment, the possibility of aseptic discitis due to a seronegative spondyloarthropathy should be considered. Our case is the first reported case of AS with discitis in Bahrain.

References

1. Ball J. Enthesopathy of Rheumatoid and Ankylosing Spondylitis. Ann Rehum Dis 1971; 30: 213-223.
2. Kelly WN. Textbook of Rheumatology. 2nd ed. Philadelphia: WB Saunders; 1987. p. 1022.
3. Maiuri F, Iaconetta G, Gallicchio B, Manto A Brigati F. Spondylos discitis: Clinical and Magnetic Resonance Diagnosis. Spine 1997; 22: 1741-1746.
4. Rasker J, Prevo R, Lanting P. Spondylodiscitis in Ankylosing Spondylitis, Inflammation or Trauma? Scand J Rheumatol 1996; 25: 52-57.
5. Price A, Allen J, Eggers F, Shaff M, Everette JA. Interventional disk-space Infection: CT changes. Radiology 1983; 149: 725-729.
6. Sharif H, Osarugue A, Clark D, Madkour MM, Aabed MY Mattsson TA et al. Brucellar and tuberculous spondylitis: Comparative imaging features. Radiology 1989; 171: 419-425.
7. Frank A, Trappe A. The role of magnetic resonance Imaging (MRI) in the diagnosis of spondylodiscitis. Neurosurg Rev 1990; 13: 279-283.
8. Bruns J, Maas S. Advantages of diagnosing bacterial spondylitis with magnetic resonance imaging. Arch Orthop Trauma Surg 1989; 108: 30-35.