

Clinical Note

Male variant of cloacal extrophy

Cloacal extrophy also referred to as OEIS complex (Omphalocele, vesicle Extrophy, Imperforate anus, and Spinal abnormalities), or vesico-intestinal fissures, is a rare and complex congenital anomaly.^{1,2} It was first reported by Littre in 1709.³ One hundred and fifty seven cases had been reported in the world literature in a comprehensive review of Welch in 1976.⁴ Until recent years this catastrophic defect was considered fatal. We report a case of a term neonate with male variant of cloacal extrophy and hemiphallus. The frequency, embryological description, diagnosis and prognosis of this rare condition are presented in this report. A male neonate weighing 3005 grams was born at 37 weeks of gestation by spontaneous vaginal delivery. Apgar score was 7 and 9 at one and 5 minutes. He was transferred to King Faisal Specialist Hospital and Research Center Riyadh, for further evaluation and management of the complex congenital malformation. There was no history of maternal illness or drug ingestion during pregnancy. The parents were first-degree cousins. On physical examination there was an omphalocele, complete extrophy of the bladder, and rectosigmoid bowel, imperforate anus, hemi-phallus with undescended testes, widely separated pubic rami, bilateral talipes equinovarus, and sacral meningomyelocele (Figures 1 and 2). He underwent numerous diagnostic studies and procedures, including pelvic x-ray that showed widely separated pubic bones and short sacrum. The abdominal ultrasound showed absence of the left kidney. Head ultrasound was unremarkable. The neonate was evaluated by a multidisciplinary team and based on poor prognosis, following careful evaluation and discussion with the family a decision was made to treat him conservatively. The neonate died at 7 days of age. Parents did not permit autopsy to be

performed. Cloacal extrophy (OEIS complex) is a rare complex congenital anomaly, which occurs once in every 200,000 to 400,000 live births, with equal sex distribution.^{1,2} This complex anomaly is the most severe manifestation of the Epispadias-Extrophy spectrum of birth defects. This defect is thought to be due to premature rupture of the cloacal membrane prior to complete descent of the urorectal septum.⁵ Essential features consist of extrophy of the bladder with the bladder split in 2 halves, by an interposed strip of intestinal mucosa representing the ileocecum, with the distal opening of the ileum at the cephalic margin and the proximal opening of a blind hindgut at the caudal margin of the cloacal.² The anorectal agenesis associated with this complex anomaly is a spectrum of distal small intestine and colon anomalies, as well as a range of genital defects have been reported.^{1,2,6} In males the penis is usually bifid, as it has been shown in our patient, and each half is epispadic and attached to the medial aspects of the widely separated pubic rami.⁷ In females the clitoris is generally bifid and associated with a duplex vagina and bicornuate uterus.⁸ Manzoni et al reported many variants of this condition.⁹ The other commonly associated defects include omphalocele in 90% of cases.¹⁰ Central nervous system deformities most commonly involving the lumbosacral spine and hydrocephalus. Upper urinary tract anomalies have been reported in 50% of cases, as has been shown in our patient, as well as pubic diastases, and defects of the lower limb.⁸ As early as 1900 Steinbuchel made the first attempt to salvage a child with cloacal extrophy through staged surgical intervention.⁶ More remarkable is the fact that, the first reported surgical success was in 1960 by Rickham.¹¹ Since then numerous advances have been achieved in the reconstruction of all the components of OEIS complex anomalies. This in turn has led to the

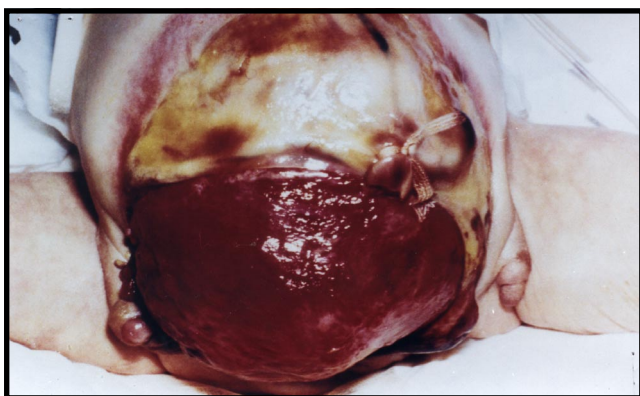


Figure 1 - Photograph shows omphalocele, everted bladder mucosa and cecum, and double penis. (Patient's chest is at top of picture, pelvis at bottom).

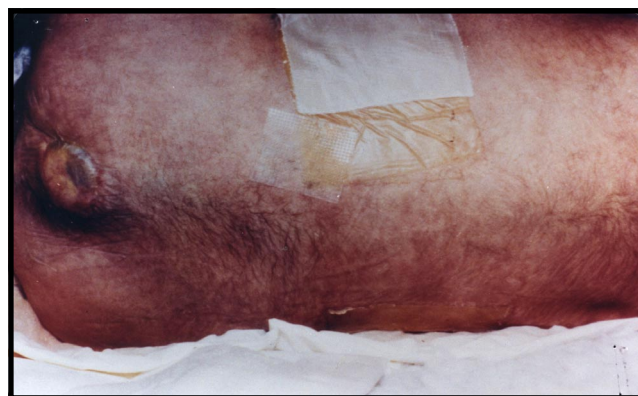

Figure 2 - Photograph of the same patient shows sacral meningomyelocele and imperforate anus. (Patient's chest is at right side of picture, pelvis at the left).

development of a staged surgical scheme for the management of these complex patients that has not only resulted in a high rate of survival, but also in successful reconstruction so that these patients can lead socially acceptable lives. Recent advances in antenatal ultrasound scanning made the suspicion of OEIS complex feasible, in addition to an omphalocele, it detects spinal segmentation disorders, bladder absence contrasting with the presence of renal parenchyma, meningomyelocele, club feet, renal malformation, and ascites, particularly in fetuses small for gestational age with normal amounts of amniotic fluid, and abnormal umbilical arteries.¹² Advances in neonatology and surgical techniques have improved the prognosis of patients with OEIS complex, in the last decade; several centers have reported 90% survival rate.¹³ Consequently, several studies considered that OEIS complex is compatible with a meaningful quality of life.^{13,14} The optimal mode of delivery for an infant with this disorder is controversial, but delivery by planned cesarean section is commonly recommended.¹⁵ However, in the view of the serious nature of this malformation and the care required for such infants, including early and aggressive multidisciplinary surgical intervention. If the diagnosis is made during pregnancy, the family should be counseled with regard to transfer in utero to tertiary care center for further management.

References

1. Tank ES, Lindenauer SM. Principles of management of extrophy of the cloaca. *Am J Surg* 1970; 119: 95-98.
2. Johnston JH, Penn IA. Extrophy of the cloaca. *Br J Urol* 1966; 38: 302-307.
3. Litre A. Cited by Duncan. *Mem Acad R Sci* 1709; 4: 9.

4. Welch KJ. Cloacal Extrophy (vesicointestinal fissure). In: Ravitch MM, Welch KJ, Benson CD et al, editors. *Pediatric Surgery Vol 2*. Chicago, IL; Year Book Med Publ; 1979. p. 802-808.
5. Thomalla V, Rudolph RA, Rink RC, Mitchell ME. Induction of cloacae extrophy in the chick embryo using the CO2 laser. *J Urol* 1985; 134: 991-995.
6. Steinbuechel H. Ueber Nabelschnurbruch und Blasenbauchspalte mit Cloakenbildung von Secten des Danndarmes. *Arch Gynakol* 1900; 60: 465.
7. Uson AC, Lattimer JK, Melicow MM. Types of Extrophy of urinary bladder and concomitant malformations. *Pediatrics* 1953; 23: 927.
8. Soper RT, Kilgerr K. Vesico-intestinal fissure. *J Urol* 1964; 92: 490-501.
9. Manzoni GA, Ransley PG, Hurwitz RS. Cloacal extrophy and cloacal extrophy variants: A proposed system of classification. *J Urol* 1987; 138: 1065-1068.
10. Beckwith JB. The congenitally malformed. VII. Extrophy of the bladder and cloaca Extrophy. *Northwest Med* 1966; 65: 407-410.
11. Rickham PP. Vesico-intestinal fissure. *Arch Dis Child* 1960; 35: 97-102.
12. Chitrit Y, Zorn B, Filidori M, Robert E, Chasseray JE. Cloacal Extrophy in monozygotic twins detected through antenatal ultrasound scanning. *J Clin Ultrasound* 1993; 21: 339-342.
13. Hurwitz RS, Manzoni GAM, Ransley PG, Stephens FD. Cloacal Extrophy: Report of 34 cases. *J Urol* 1987; 138: 1060-1064.
14. Stolar CH, Randolph JG, Flanigan LP. Cloacal Extrophy: Individualized management through a staged surgical approach. *J Pediatr Surg*, 1990; 25: 505-507.
15. Kutzner DK, Wilson WG, Hogge WA. OEIS complex (cloacal Extrophy): Prenatal diagnosis in the second trimester. *Prenat Diagn* 1988; 8: 247-253.

Khalid M. Saïdy

*Neonatology Section, Department of Pediatrics
Madina, Maternity & Children's Hospital
Medina 935
Kingdom of Saudi Arabia*