

Case Reports

Fraser syndrome with bladder pseudoexstrophy

Jehad A. Daia, MD.

ABSTRACT

We report a one year old girl with Fraser Syndrome (the association of craniofacial abnormalities, syndactyly and cryptophthalmos) and multiple urogenital abnormalities including clitorimegaly, left renal agenesis and a unique urinary bladder exstrophy variant (psuedoexstrophy) with intact bladder which herniates through the lower abdominal wall defect.

Keywords: Fraser syndrome, pseudoexstrophy, urological abnormality.

Saudi Med J 2001; Vol. 22 (5): 455-456

The association of craniofacial abnormalities, syndactyly, cryptophthalmos was first described by Fraser in 1962.¹ Inheritance in Fraser Syndrome is by an autosomal recessive mode. Urogenital abnormalities such as renal agenesis or hypoplasia and enlarged clitoris are a common occurrence.^{2,3} Pseudoexstrophy; bladder exstrophy variant was described as a rare isolated abnormality of the urinary bladder. To the best of our knowledge herein we describe a unique case of Fraser Syndrome with bladder pseudoexstrophy.

Case Report. A one year old girl with Fraser syndrome had the typical abnormalities associated with the syndrome i.e. cryptophthalmos and depressed broad nasal bridge, syndactyly of both hands and feet and laryngeal stenosis Figure 1. Also she had multiple urogenital abnormalities including clitorimegaly, left renal agenesis and abdominal wall/skeletal abnormalities similar to what usually seen in bladder exstrophy – but with an intact bladder (psuedoexstrophy). These included lower abdominal wall defect through which the bladder was herniated, a low set umbilicus and separated pubic bones (Figure 2). The lower abdominal wall defect was corrected surgically by simple dissection and

approximation with minimal tension.

Discussion. According to the diagnostic criteria proposed by Thomas et al,⁴ the findings in this patient are compatible with the diagnosis of Fraser Syndrome. The major criteria are cryptophthalmos, syndactyly, abnormal genitalia and sibling with cryptophthalmos syndrome, and the minor criteria are congenital malformation of ears, nose, larynx, cleft lip, skeletal defect, umbilical hernia, renal agenesis and mental retardation in survivors. In this report we have a one year old girl with most of the major and minor criteria of Fraser Syndrome. The findings of a low set umbilicus, separated pubic symphysis and an intact urinary bladder that herniated through the lower abdominal wall defect is considered to be a bladder exstrophy variant which is best described as pseudoexstrophy. Bladder exstrophy is considered to be secondary to failure of cephalad movement of the body stalk, rendering the midline mesenchymal interposition impossible and causing subsequent rupture of the superficial colocal membrane. It would appear that in the present case the first embryological event took place (to produce the abdominal wall defect) without rupture of the

From the Department of Urology, King Faisal Specialist Hospital and Research Centre, Riyadh, Kingdom of Saudi Arabia.

Received 30th September 2000. Accepted for publication in final form 29th November 2000.

Address correspondence and reprint request to: Dr. Jehad A. Daia, Pediatric Division, Department of Urology, King Faisal Specialist Hospital & Research Centre, MBC 83, PO Box 3354, Riyadh 11211, Kingdom of Saudi Arabia. Tel. +966 (1) 464 7272 Fax. +966 (1) 441 4839.

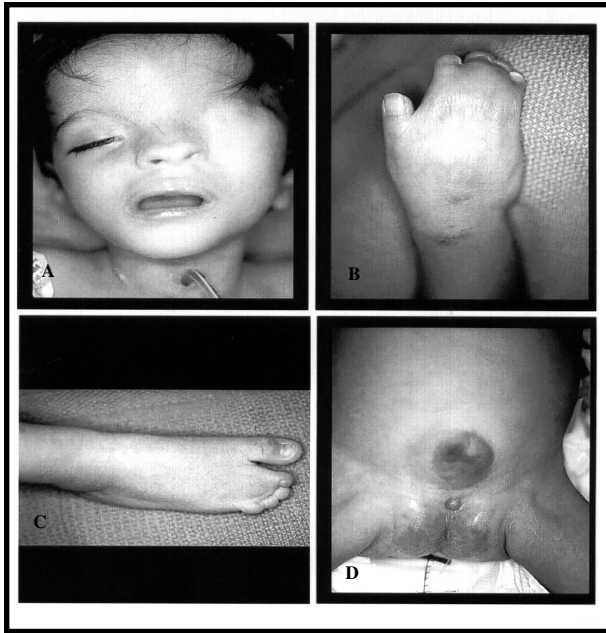

Figure 1 - Clinical photograph showing: (a) Cryptophthalmos and tracheostomy (for laryngeal stenosis); (b,c) Syndactyly of hand and foot; (d) Lower abdominal hernia, a low set umbilicus and clitorimegaly.

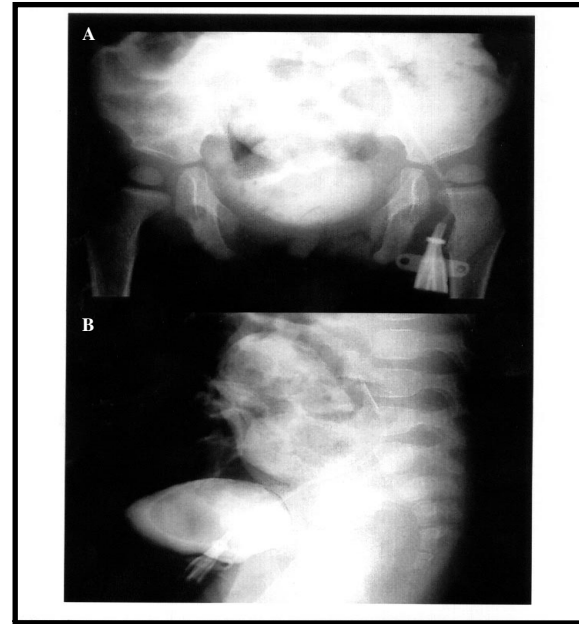


Figure 2 - Radiological photograph showing: (a) Plain x-ray showing wide separation of pubic bones; (b) Cystogram showing urinary bladder herniating through the lower abdominal wall defect.

coloacal membrane (to produce the exstrophy).⁵ The variant of an exstrophic abdominal wall with normal bladder with or without association with Fraser Syndrome is unique. To the best of our knowledge this is the first case of bladder pseudoexstrophy reported in association with Fraser Syndrome. In Saudi population due to the high consanguinity rate, we believe that Fraser Syndrome does exist but under reported.

Acknowledgment. I am most grateful and indebted to Susan Railey, our Urology Department Secretary, for her administrative assistance and typing of this paper.

References

1. Fraser GR. "Our genetic load": a review of some aspects of fenetical variation. *Ann Human Genet* 1962; 25: 387-415
2. Gattuso J, Patton MA and Baraitser M. The clinical spectrum of the Fraser syndrome: report of three new cases and review. *J Med Genet* 1987; 24: 549-555
3. Chattopadhyay A, Kher AS, Udwardia Adk, Sharma SV, Bharucha BA, Nicholson AD. Fraser syndrome. *Postgrad Med* 1993; 39: 228-230
4. Francois J. *Genetic Aspects of Ophthalmology*, vol 8 No 4. Boston: Little Borwn and Company, 1968; 817-837.
5. Ahmed S, Abu Daia J. Extrophic abdominal wall defect without bladder exstrophy. *Br J Urol* 1998; 81: 762-763.