

Case Report

# Caudal Regression Syndrome and Penoscrotal Transposition

*Maher M. Al-Zaiem, MD, CU (France).*

---

## ABSTRACT

Caudal Regression Syndrome is a rare anomaly affecting different systems in the caudal portion of the fetus. Penoscrotal transposition is a rare condition of variable severity often associated with Caudal Regression Syndrome. We report a case of Caudal Regression Syndrome with perineal ano-rectal duplication, incomplete penoscrotal transposition, perineal hypospadias, chordee, and thoracic hemivertebrae.

**Keywords:** Caudal regression syndrome, penoscrotal transposition.

Saudi Med J 2001; Vol. 22 (6): 544-546

---

A newborn baby admitted to the hospital with sacrococcygeal mass, perineal hypospadias and partial transposition of the penis and the scrotum is reported. We report the pathological findings, a review of the embryological development of the anomaly and literature review.

**Case Report.** A full term Saudi male infant was seen during the neonatal period with a sacrococcygeal mass measuring 5 x 5 cm which was soft, compressible and pushing the anal opening anteriorly. There was perineal hypospadias with chordee, the penis was displaced posteriorly and lying between 2 hemiscrota. The scrotum was bifid and the urethral meatus was perineal. X-ray of the spine showed T3 hemivertebrae. The infant passed urine and stool during the episodes of crying indicating bowel and bladder incontinence. The obstetric history revealed a history of fever for 5 days during the first trimester of pregnancy for which the mother was admitted to the hospital. Consanguinity was positive. The abdominal ultrasound was normal. Barium enema was carried out through the small anal opening, which showed

dilatation of the ano-rectum enrolled in the perineal mass. As there was no neonatal emergency, the child was discharged and readmitted at 10 months of age for surgery.

Exploration by a posterior sagittal approach revealed cystic dilatation of the rectum herniating through the left side of the levator muscle which was like a thin membrane coming directly into the subcutaneous space. The right side of the levator muscle was well defined. Frequent electric stimulation did not show any contraction of the external sphincter muscle. Resection of the cystic duplication of the rectum with the anal opening was carried out. The right levator muscle was dissected, turned posterior to the new rectum, and fixed to the left side of the pelvic fascia. Ano-rectoplasty was performed and closure was carried out with a drain. The post-operative period was uneventful and the child was discharged after 2 weeks with good continence (3 stool/day). He was readmitted 4 months later for first stage repair of hypospadias, perineal urethroplasty, release of chordee was carried out, and the penis was moved to a more anterior position with the 2 halves of the scrotum resutured

---

From the Department of Pediatric Surgery, Al-Noor Specialist Hospital, Makkah-Al-Mukarrama, Kingdom of Saudi Arabia.

Received 30th September 2000. Accepted for publication in final form 31st January 2001.

Address correspondence and reprint request to: Dr. Maher Al-Zaiem, Department of Pediatric Surgery, Al-Noor Specialist Hospital, PO Box 6251, Makkah, Kingdom of Saudi Arabia. Tel. +966 (2) 5454280. Fax. +966 (2) 5580965. E-mail: msfff@yahoo.com

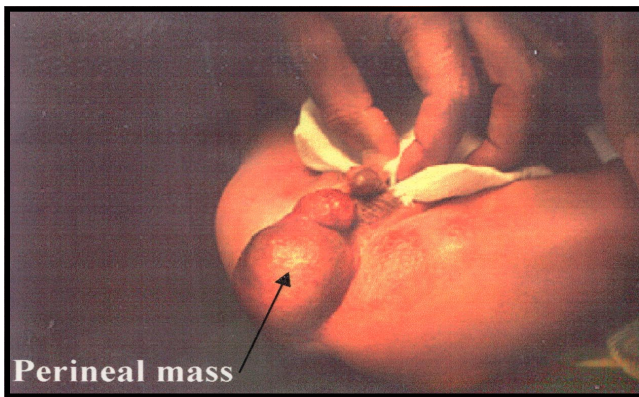


Figure 1 - The perineal mass.

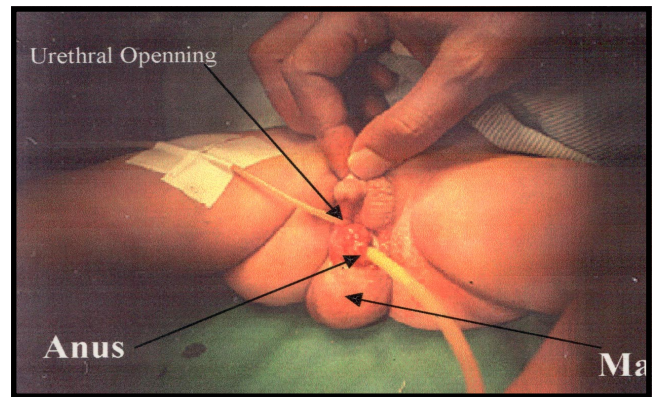


Figure 2 - One fully catheter inserted in the perineal urethral opening, another catheter inserted in the anal canal.

behind it. The patient was discharged with peno-scrotal hypospadias. He was readmitted again 6 months later for the 3rd time, and Denis-Brown urethroplasty was performed. After discharge, the patient developed a distal penile fistula which, was closed one year later with a satisfactory functional and cosmetic result, with a 5 years follow up.

**Discussion.** Caudal Regression Syndrome (CRS) is a range of structural abnormalities occurring in the distal portion of the developing fetus; rectum, genito urinary system, lumbo-sacral spine and lower limb, resulting from an insult to the caudal portion of the developing fetus at 4-8 weeks gestation.<sup>1</sup> At this time, the urorectal septum, cloaca, mesonephros and developing spine are all in proximity. This spectrum of malformations include anal imperforation and mermaid syndrome; classified by Duhamel as small lesions (imperforate anus, mild vertebral anomalies), larger lesions (urinary or genital anomalies) and extreme lesions (limbs fusion or Sirenomelia).<sup>1</sup> Sirenomelia is the severe form, consisting of lower limb fusion, sacral and pelvic bony anomalies, absent external genitalia, anal imperforation and renal agenesis or dysgenesis; resulting from injury to the caudal mesoderm between 28 and 32 days of fetal development.<sup>2</sup> Transposition of the external genitalia has been described in conjunction with CRS.<sup>3-5</sup> In a normally developed fetus the positioning of the penis in relation to the scrotum depends upon the development of the parsphallica at 4-10 weeks, and the caudal migration of the labioscrotal swelling at 4 months.<sup>3</sup> Transposition of the external genitalia is believed to result from retardation in the development of the parsphallica secondary to retardation of its predecessor, the genital tubercle. This affects the caudal migration of the labioscrotal swellings and results in the peno-scrotal transposition (PST).<sup>6</sup> Sixty patients with PST have been

documented,<sup>4,7-17</sup> of which 23 had association with caudal regression syndrome, (9 of them had complete PST and 14 cases had incomplete PST);<sup>18</sup> the remaining patients had no features of CRS. In all the forms, the testes are usually normally developed and situated, whereas the penis is most commonly short and hypospadiac.<sup>14</sup> Three females have been described with the clitoris and urogenital sinus lying posterior to fused labio-scrotal folds.<sup>4,12,19</sup>

In summary, we report a case of CRS; the gastro intestinal system involvement in our patient consisting of perineal ano-rectal duplication, the genito-urinary system involvement consisting of perineal hypospadias, chordee, bifid scrotum and the lumbo-sacral spine anomaly consisting of thoracic hemivertebrae in addition to incomplete PST. Correction of the perineal ano-rectal duplication was carried out by a posterior sagittal ano-rectoplasty technique with good functional results. Correction of hypospadias and PST was carried out by a 2-stage repair.

## References

1. Duhamel B. From the Mermaid to Anal Imperforation. The syndrome of caudal regression. *Arch Dis Child* 1961; 36: 152-155.
2. Chagen DJ, Nance WF. Symmelia in one of monozygotic twins. *Teratology* 1971; 4: 367-378.
3. Miller SF. Transposition of the external genitalia associated with the syndrome of caudal regression. *J Urol* 1972; 108: 818-822.
4. Lage JM, Driscoll SG, Bieber FR. Transposition of the external genitalia associated with caudal regression. *J Urol* 1987; 138: 387-389.
5. Smanberg AM, Rosenberg NT. Partial transposition of the penis and scrotum with anterior urethral diverticulum in the child born with the caudal regression syndrome. *J Urol* 1989; 142: 1061-1062.
6. Spaulding NH. The development of the external genitalia in the human embryo. *Contrib Embryol* 1921: 61-67.
7. Adair EL, Lewis EL. Ectopic scrotum and diphallia. *J Urol* 1960; 84: 115-117.

8. Chuang JH. Congenital urethral fistula with incomplete peno-scrotal transposition. *Pediatr Surg Int* 1989; 4: 211-213.
9. Cohen AN, Zarafu IW, Hana NK. Complete peno scrotal transposition. *J Urol* 1985; 26: 149-152.
10. Ehrlich RR, Scardino PT. Surgical correction of scrotal transposition and perineal hypospadias. *J Pediatr Surg* 1982; 17: 175-177.
11. Flanagan MJ, McDonald JH, Veifer HJ. Unilateral transposition of the scrotum. *J Urol* 1961; 6: 273-275.
12. Glenn Y, Ikoma F. Surgical correction of incomplete peno-scrotal transposition. *J Urol* 1973; 110: 603-605.
13. Mori Y, Ikoma F. Surgical correction of incomplete peno scrotal transposition associated with hypospadias. *J Pediatr Surg* 1986; 21: 46-48.
14. Paramo PG, Hinderer U, San Antonia J, Paramo JR, Silmi A, Rabadan M. Pre-penile scrotum: Report of two cases and review of the literature. *Eur Urol* 1981; 7: 246-251.
15. Parikh A, Bharucha, Kumta NB. Caudal Regression Syndrome. *Indian Pediatr* 1988; 25: 299-302.
16. Wilson RC, Wilson CL, Thickstein JN. Transposition of the external genitalia. *J Urol* 1965; 94: 600-602.
17. Turnock RR, Brereton RJ. Penoscrotal transposition and the Caudal Regression Syndrome. *Eur J Pediatr Surg* 1991; 6: 374-375.
18. Johnslon JH. Abnormalities of the scrotum and the testes. In: Williams DI, Johnslon JH editors. *Ped-Urology*. 2nd ed. London: Butterworth Scientific; 1982. p. 451-466.
19. Reyer R. Dislocation of the phallus, penis and clitoris following pelvic malformation in the human fetus. *Anat Rec* 1941; 79: 231.