

# A modified method of submental oroendotracheal intubation

*Alagumba L. Nwoku MD, DMD, Saeed A. Al-Balawi, BDS, MSc, Saeed A. Al-Zahrani, BDS.*

---

## ABSTRACT

**Objective:** The aim of this paper is to present a modification of submental intubation in the management of airway.

**Methods:** Following usual oroendotracheal intubation, the tube and cuff are exteriorized through a laterosubmental incision, and connected to the anesthetic machine.

**Results:** Ten patients comprising 8 panfacial fractures and 2 orthognathic surgical cases have successfully been managed with this approach. There were no complications, no morbidity, and the scar was inconspicuous and esthetically pleasing.

**Conclusions:** The laterosubmental intubation technique is simple, efficacious in the management of severe maxillofacial injuries, orthognathic surgical cases with nasal obstruction and in plastic surgery for concomitant approach to rhytidectomy, lip correction and rhinoplasty. This approach deserves to be widely propagated among specialists working on the face.

**Keywords:** Intubation, submental maxillofacial surgery, technique, intermaxillary fixation.

**Saudi Med J 2002; Vol. 23 (1): 73-76**

---

The management of severe injuries of the facial skeleton requires good access. Endotracheal anesthesia is today the preferred type of general anesthesia most often applied. Indeed, naso-endotracheal intubation is common practice in oral and maxillofacial surgery. But sometimes, because of severe trauma to the midface or congenital nasal deformity, this may not be possible. Several authors, among them Schulz<sup>1</sup> and Fonseca and Walker,<sup>2</sup> have pointed out the dangers of naso-endotracheal intubation in cases of midfacial and basilar skull fractures. The dangers listed include cranial intubation, epistaxis, trauma to pharynx, pressure necrosis of external nares, otitis media, sinusitis, sepsis and inability to pass a tube through the nasal passages. When naso-endotracheal intubation is not possible, oral intubation would normally be attempted. This approach significantly hinders

establishment of proper occlusion for reduction, and immobilization of the jaws with intermaxillary fixation. Consequently, some specialists resort to tracheostomy as the preferred route for airway management. However, tracheostomy may be accompanied by morbidity such as infection, hemorrhage, subcutaneous emphysema, pneumothorax, pneumomediastinum, recurrent laryngeal nerve damage, tracheal stenosis and tracheoesophageal fistula.<sup>3,4</sup> For these reasons, other less complicated approaches to airway management must be considered. It appears that sub-mental intubation is not well known amongst specialist surgeons, although there is a dearth of literature on this technique. The purpose of this paper is to present a modification to the technique originally described by Altemir in 1986<sup>5</sup> and include our experience in the management of 10 cases.

---

From the Department of Dentistry, Division of Oral and Maxillofacial Surgery, Riyadh Armed Forces Hospital, Riyadh, Kingdom of Saudi Arabia.

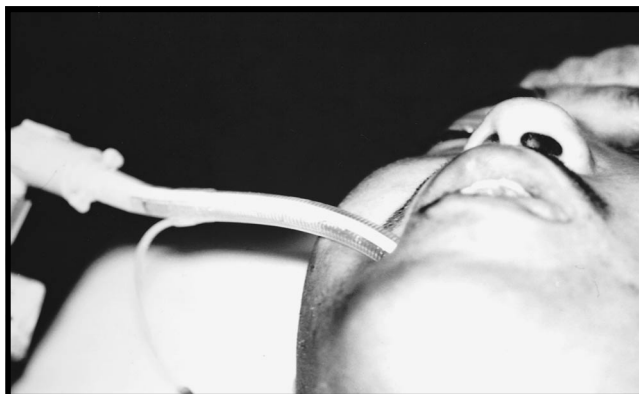Received 23rd June 2001. Accepted for publication in final form 3rd September 2001.

Address correspondence and reprint request to: Dr. A. L. Nwoku, Division of Oral & Maxillofacial Surgery, Department of Dentistry, Riyadh, Armed Forces Hospital, PO Box 7897, Riyadh 11159, Kingdom of Saudi Arabia. Tel. +966 (1) 4777714 ext 4330. Fax +966 (1) 4777714 ext. 2282. E-mail: anwoku@hotmail.com

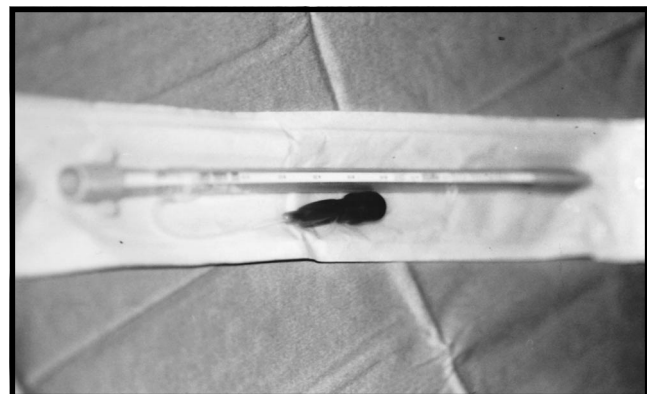**Methods.** The technique as described originally involves the usual oro-endotracheal intubation. The free end of the tube is then exteriorized through a submental incision and then reconnected. In our case a laterosubmental incision of about 2cm in a natural skin crease, is made. Where a scar or wound is present, this could be utilized with advantage. The intubation is performed orally in the usual manner (**Figure 1**). We prefer an armored or anode tube reinforced with built in spiral wire, which minimizes collapse or kinking of the endotracheal tube (**Figure 2**). Following the skin incision, a large curved hemostat is passed from the laterosubmental incision into the mouth, where an incision of 2cm in length is made parallel to the gingival margin. This incision must be so placed as to avoid major anatomic structures in the antero-lateral aspect of the floor of the mouth, such as the lingual nerve, sublingual gland, Wharton's and Bartholin's ducts (**Figures 3a and 3b**). The endotracheal tube is then disconnected and the pilot tube cuff deflated. This is first held with the curved hemostat and passed extraorally, followed by the re-inforced endotracheal tube, which has been disconnected, from the standard connector (**Figure 4a and 4b**). The correct placement and connection to the anesthetic machine is checked. Intraorally, the tube is positioned snugly on the floor of the mouth between the tongue and the mandible. The tube is finally fixed to the skin with 2-0 silk sutures (**Figure 5**). On completion of surgery, extubation is carried out in reverse order, that is, the skin sutures are removed, the cuff deflated and withdrawn into the mouth, followed finally by the endotracheal tube. If an intermaxillary fixation is maintained, the cuff is deflated and the tube pulled through the laterosubmental incision. The wound is then closed with 3 to 4 interrupted sutures using 4-0 or 5-0 silk. Extubation may also be carried out in the recovery room or even after 72 hours as suggested by

Bartkowski et al.<sup>4</sup> In this case, it would be judicious to close the wound under local anesthetic.

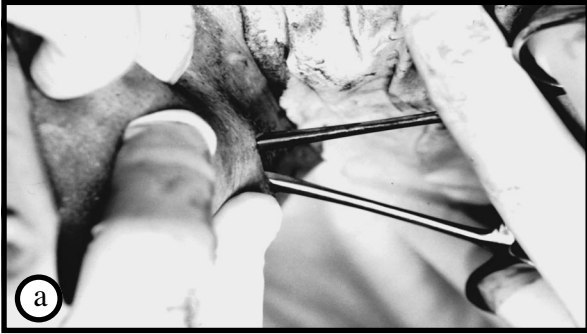**Results.** Between July 1999 and June 2001, we have utilized this approach in 10 patients. Nine of them were males and there was one female with the ages ranging from 18 years to 33 years. Eight patients suffered severe panfacial fractures, which also involved the naso-ethmoidal complex. The 2 other cases were dentofacial deformities where naso-endotracheal intubation failed. The technique is illustrated with one such trauma case. A 32-year-old military officer was transferred to us from another hospital. He had sustained facial injuries as a result of vehicular accident. On admission he was fully conscious and alert, and examination showed massive facial swelling, bilateral periorbital ecchymosis, however both pupils reacted to light and convergence. The maxilla was freely mobile, and there was comminuted fracture of the naso-ethmoid complex. The mandible also showed abnormal mobility on the left side. There was gagging of occlusion. Radiographic examination confirmed extensive maxillomandibular naso-ethmoidal fractures with gross displacement. Diagnosis of maxillary fractures with Le Fort I and Le Fort III, naso-ethmoidal complex fractures, as well as, fracture of the left body of mandible were made. The airway management was achieved by the technique described above (**Figures 1-5**). The surgical treatment required open reduction and rigid fixation of the facial fractures, in addition to access to the nose, and a period of intraoperative intermaxillary fixation was necessary. The operation, as well as, the postoperative course was uneventful, and the patient could be discharged home in ambulatory follow-up after 7 days. The latero-submental scar was very satisfactory esthetically.



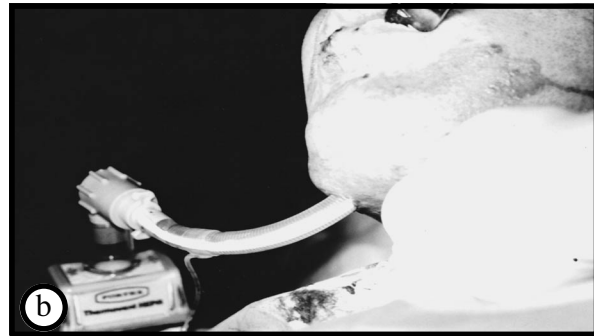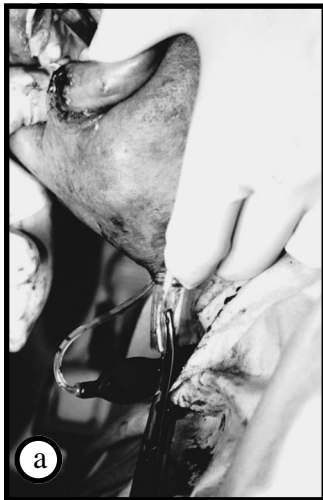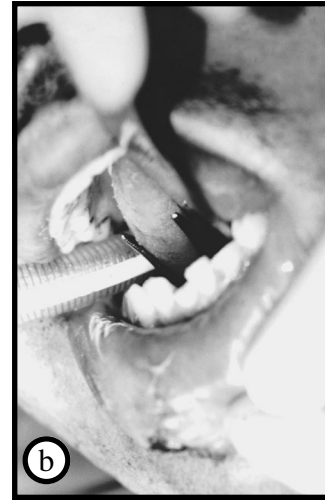**Figure 1** - Intraoperative photograph showing patient with oroendotracheal intubation in place.



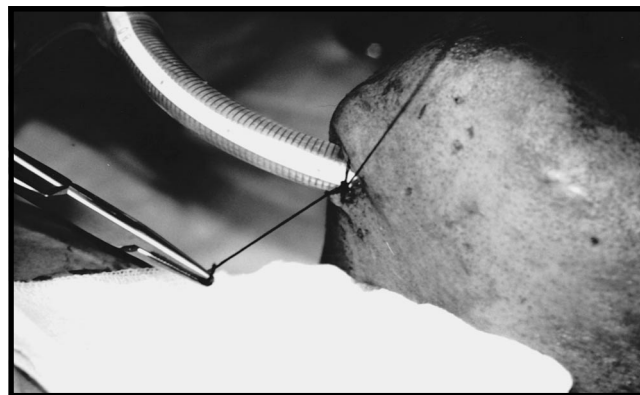
**Figure 2** - Photograph showing a size 7 mm re-inforced endotracheal tube, the type normally employed in these cases.



**Figure 3** - Intraoperative photographs showing stage-by-stage approach of the laterosubmental incision **a)** blunt dissection with large curved artery forceps. **b)** Incision and introduction into the mouth.



**Figure 4** - The deflated cuff and tube have been fed into the hemostat **a)** successfully withdrawn submentally **b)** reconnection to anesthetic machine.



**Figure 5** - Securement of the tube with 2-0 silk suture. Sometimes a tape may be applied.

**Discussion.** This modified technique of laterosubmental approach to the management of airway was used by us in 10 patients over the past 2 years at the Military Hospital Riyadh (RKH). Of these, 8 had severe multiple fractures of the facial skeleton and of the naso-ethmoid complex. The 2 other cases were dentofacial deformities in which naso-endotracheal intubation failed after several attempts. In all 10 patients, the laterosubmental approach for airway management allowed for an unimpeded manipulation of the midfacial fractures, manipulation of the jaws after bimaxillary osteotomies, and establishment of proper occlusion and intermaxillary fixation. The anesthetist had easy access to the endotracheal tube, which he was able to manipulate as required. An alternative to this technique would have been tracheostomy with all its attendant complications and morbidity. The tracheostomy wounds sometimes heal with an unsightly scar, which may be unacceptable to many patients. Green and Moore<sup>6</sup> suggested a reverse approach in which oral intubation in the usual manner is carried out, another tube is then passed from a submental incision into the mouth. The original tube is withdrawn and the 2nd tube substituted. In this way, endotracheal intubation is carried out twice. And recently, the submental route has further been described using laryngeal mask airway.<sup>7</sup> The modification described here allows the safe use of oro-tracheal intubation in cases of severe maxillomandibular fractures, where oral intubation would normally interfere with the surgical management of the facial injuries. In addition, it is also possible in patients undergoing elective orthognathic surgery in the presence of nasal obstruction as demonstrated in our 2 cases. The procedure is technically straight forward, safe and efficacious, and there has been no report of associated marked bleeding or complications either in our hands or with other authors. This intubation technique can also be used in esthetic plastic surgery of the face, where assessment of facial asymmetry is important,

as well as in simultaneous rhytidectomy, lip correction and rhinoplasty. The laterosubmental intubation offers several advantages, including wide access to the face, nose, occlusion and assessment of facial asymmetry. The complications encountered with naso-endotracheal intubation and tracheostomy for airway management in patients with severe maxillomandibular fractures are obviated. There was no case of postoperative infection of the submental incision which leaves an esthetically pleasing scar.

In conclusion, therefore, we would like to recommend that this approach to the management of airway should be widely propagated among surgical specialists involved in head and neck surgery, especially in consideration of its versatility and numerous advantages without hazard to surgical anesthesia.

**Acknowledgment.** The authors would like to extend their grateful thanks to the Department of Anesthesia, specifically Drs. Shahid Iqbal, Nader Hanjöl, Jamil Anwari and Farouq Brohi who managed the airway in these patients.

## References

1. Schulz RC. Nasotracheal intubation in the presence of facial fractures. *Plast Reconstr Surg* 1990; 86: 1046.
2. Fonseca R, Walker R. Oral and Maxillofacial Trauma. Philadelphia: WB Saunders 1991. p. 124-135.
3. Gordon NC, Tolstunov L. Submental approach to oroendotracheal intubation in patients with midfacial fractures. *Oral Surg Oral Med Oral Pathol* 1995; 79 : 269-272.
4. Bartkowski SB, Zapala J, Szuta M, Podziorny H, Kuchta K. General Anaesthesia via tracheosubmental Intubation from our own Experience. *Aesthetic Plast Surg* 1999; 23: 292-295.
5. Altemir HF. The submental route for endotracheal intubation. A new technique. *J Maxillofac Surg* 1986; 14: 64-65.
6. Green JD, Moore UJ. A modification of submental intubation. *Br J Anaesth* 1996; 77; 789-791.
7. Altemir HF, Montero SH. The submental route revisited using the laryngeal mask airway: a technical note. *J Craniomaxillofac Surg* 2000; 28: 343-344.