Case Report

Psoas abscess presenting with femoro-popliteal vein thrombosis

Oludare A. Demuren, MD, FRCR, Mohammed Abomelha, MD, AFUrol.

ABSTRACT

Psoas abscess is an uncommon condition with vague clinical presentation. It generally has an insidious onset and before the advent of computed tomography, few cases were reported in the medical literature. We report the case of a middle aged diabetic woman who presented with left leg swelling. Doppler ultrasound revealed thrombosis of the popliteal vein and a collection in the left groin. Computed tomography confirmed the presence of a large left iliopsoas abscess extending to the anterior compartment of the thigh complicated with thrombosis of the superficial femoral and popliteal veins. We suggest that an iliopsoas abscess should be excluded when an immunocompromised patient presents with deep vein thrombosis.

Keywords: Abscess, deep vein thrombosis, computed tomography.

Saudi Med J 2002; Vol. 23 (1): 96-98

The psoas muscle is a retroperitoneal structure arising from the lateral aspect of the 12th thoracic to 5th lumbar vertebrae. Seventy percent of people have a single structure, the psoas major, but 30% also have a smaller psoas minor muscle, which lies anterior to the psoas major. The iliacus muscle is fan-shaped and arises from the inner aspect of the iliac bone exiting inferiorly where it blends with the psoas muscle to insert on the lesser trochanter of femur. Their major function is to flex the hip. The psoas muscle is in close proximity with many organs, including the pancreas, renal pelvis, ureters, aorta, jejunum, appendix, sigmoid colon and iliac lymph nodes. Thus infections may easily spread to the muscle from these organs. Psoas abscesses are described as primary when there is no obvious focus of infection and route of infection is presumed to be hematogenous. The most common pathogen in primary psoas abscess is *Staphylococcus aureus* (at least 80% of cases). Other pathogens include *Serratia marcescens*, *Pseudomonas aeruginosa, Haemophilus aphrophilus* and *Proteus mirabilis*.[1,2] Secondary psoas abscess is defined as occurring from direct spread from contiguous structures. They are usually caused by enteric bacteria (up to 78% of cases), most commonly from Crohn's disease or from the renal tract and the pancreas.[1,3] These include *Escherichia coli*, *Streptococcus* species, *Enterobacter* species and *Salmonella enteritidis*. Mycobacterium tuberculosis of the spine continues to be an important cause of secondary psoas abscess in developing areas of the world where tuberculosis is still rife. In a recent series of 18 patients, 57% of primary psoas abscess had human immunodeficiency virus (HIV). It is possible that the incidence of primary psoas abscess will increase with the HIV pandemic.[1]

Case Report. A 60-year-old diabetic Saudi woman, on oral hypoglycemic agents presented with fever, excessive sweating and bouts of melena and hematemesis over the last one month. She had developed progressive left leg swelling one week

From the Department of Radiology and Imaging (Demuren), and the Department of Urology (Abomelha), Riyadh Armed Forces Hospital, Kingdom of Saudi Arabia.

Received 15th May 2001. Accepted for publication in final form 19th August 2001.

Address correspondence and reprint request to: Dr. Oludare A. Demuren, N-636, Riyadh Armed Forces Hospital, PO Box 7897, Riyadh 11159, Kingdom of Saudi Arabia. Tel/Fax +966 (1) 4503504.

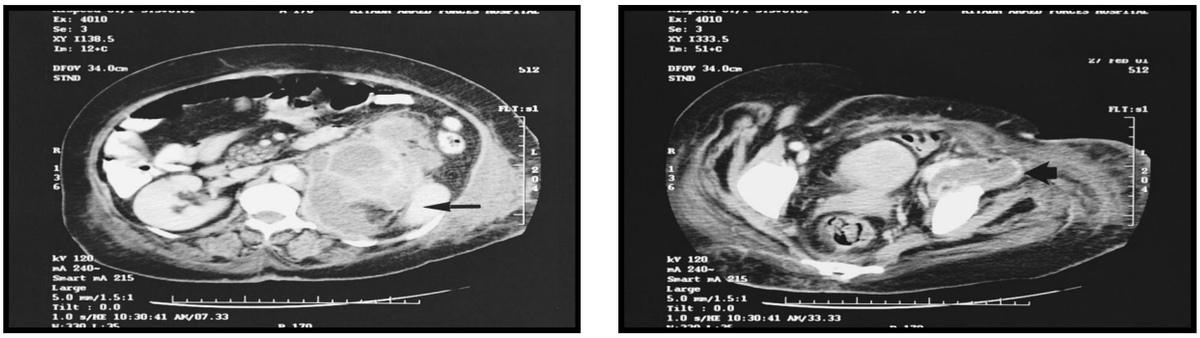

Figure 1 - Computed tomography scan showing (a) a huge multiloculated left retroperitoneal abscess obscuring the atrophied kidney. Solid tissue on the lateral aspect (black arrow) is the spleen and (b) demonstrates extension of the iliopsoas abscess (black arrow) into the anterior compartment of the left thigh.

before presentation. She was new to our hospital and her past medical report was not available. Relevant findings on examination were a right sided weakness probably from old cerebrovascular accident, a palpable mass in left side of the abdomen, and a left lower limb swelling. Laboratory tests revealed anemia (hemoglobin concentration = 5.3 g/dl), leucocytosis (white cell count = 14.1 x 10^9/L), thrombocytosis (platelet count = 602 x 10^9/L), prothrombin time (PT) 17.6 seconds (control 10-15 seconds), activated partial thromboplastin time (APTT) > 180 seconds (control 27-40 seconds), international normalized ratio (INR) = 1.5 (control = 0.8 – 1.2), serum creatinine, urea and electrolytes were normal. Serum glucose level was only slightly below normal. Doppler ultrasound revealed left popliteal vein thrombosis and a collection in the anterior thigh, the nature of which was uncertain. Computed tomography (CT) of the abdomen and pelvis revealed a huge left retroperitoneal abscess involving the psoas muscle from first lumbar (L1) vertebral level down to the left iliacus muscle and inferiorly into the anterior compartment of the left thigh (**Figures 1a & b**). The upper quadriceps muscles were inflamed and edematous with abscess collections within them. There was increase in girth of the upper left thigh compared with the right, with thrombosis of the left superficial femoral vein (**Figure 2**). The right kidney and pancreas were morphologically normal but the left kidney was not visualized. The lumbar spine and sacroiliac joints were normal. The patient was treated with CT guided percutaneous drainage inserting 12 French pigtail catheter in the left pararenal space and 10 French pigtail catheter into the left iliacus collection. Culture of the purulent aspirate grew *Escherichia coli* sensitive to Gentamycin and Tazocin. Microscopy and culture for Mycobacterium tuberculosis were negative. Double contrast barium enema was normal. Follow up CT after 18 days catheter drainage and therapy with appropriate drugs showed complete resolution of the left iliacus and anterior thigh collection, with minimal residual left perinephric collection (**Figure 3**). A shrunken left

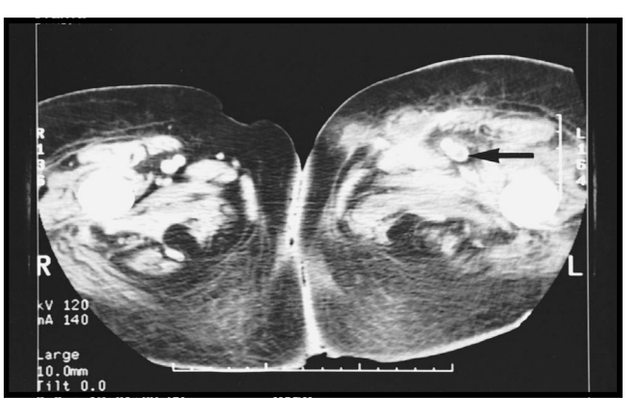

Figure 2 - Reveals a thrombosed left superficial femoral vein (long black arrow) associated with edema and soft tissue swelling.

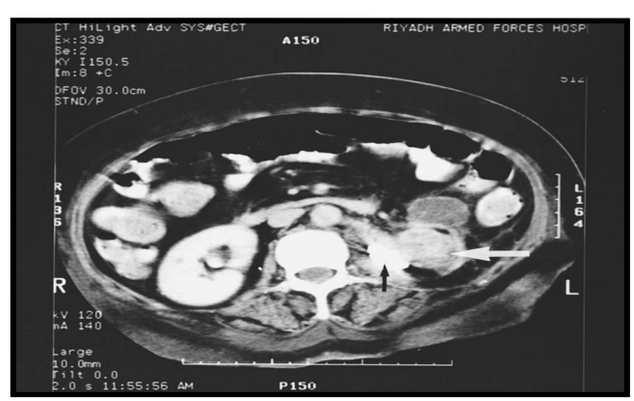

Figure 3 - Follow up computed tomography revealing a small non-functioning left kidney (white arrow) with almost complete drainage of the abscess. Coiled tip of the drainage catheter is identified by the black arrow.

kidney was revealed, confirmed to be non-functioning on isotope dimercapto succinic acid (DMSA) scan. The iliacus catheter was removed on day 24, and the perinephric catheter was removed on day 28 post insertion. The femoropopliteal vein thrombosis persisted as the patient could not be angicoagulated because endoscopy revealed multiple esophageal ulcers.

Discussion. Retroperitoneal collections are rare in the absence of pancreatitis.[3] Psoas abscesses are potentially life threatening because of their insidious nature and prompt diagnosis and treatment are essential. Isolation of *Escherichia coli* is found in up to 78% of secondary psoas abscesses, which in our case is presumed to arise from renal or perirenal infection. In a review of 27 cases of psoas abscess, diabetes mellitus was the leading underlying disease. *Escherichia coli* was the most common organism in the secondary abscess category, followed by *Staphylococcus aureus*, *Klebsiella pneumoniae*, *Streptococcus viridans* and *Candida albicans*.[4]

Whenever psoas abscess is suspected, CT should be carried out for definitive diagnosis. Computed tomography has superseded ultrasonography, and is diagnostic in 80 to 100% of cases compared with 60% for ultrasonography.[5,6] There is virtually no role for magnetic resonance imaging in the diagnosis of psoas abscess because sensitivity and specificity is not improved, and there is greater cost and patient discomfort. Computed tomography guided percutaneous drainage of iliopsoas collections coupled with therapy with sensitive antimicrobial agents usually results in prompt dramatic response.[1,2,7,8] There was remarkable improvement in our case even though the abscess was multiloculated. It is important to note that regression of inflammatory reaction after a successful clinical response to drainage may be prolonged for several weeks.[9] If follow-up imaging reveals residual focus of infection, elective surgical removal should be considered, in order to prevent future flare up of infection. This is relevant in our case where the patient is diabetic and an atrophic, non-functioning kidney was the focus of infection.

In the majority of patients, fever, flank and hip pain or limp are the usual manifestations.[1,2] A tender mass may be felt in the lower abdomen or iliac fossa. Anemia, leucocytosis and elevated sedimentation rate may be present. In our case, the anemia was quite severe due to the blood loss from the upper gastro intestinal tract, and the high platelet count presumably represents reactive thrombocytosis. The thrombocytosis does not explain the development of left superficial femoral and popliteal vein thrombosis. The thrombosis is believed to have resulted mainly from increased pressure within the restricted anterior upper thigh compartment from the abscess collections and muscle edema. The effect of the increased pressure is stagnation of blood within the superficial femoral vein in the adductor canal and consequent thrombus formation. Thus iliopsoas abscess should be suspected when a patient with fever and abdominal or back pain presents with femoral or popliteal vein thrombosis. To our knowledge, this association of psoas abscess and femoro-popliteal vein thrombosis has not been previously reported.

References

1. Babafemi T. Psoas Abscess: A Primer for the Internist. *South Med J* 2001; 94: 78-80.
2. Gruenwald I, Abrahamson J, Cohen O. Psoas Abscess: Case Report and Review of the Literature: *J Urol* 1992; 147: 1624-1626.
3. Negus S, Sidhu PS. MRI of Retroperitoneal Collections: A Comparison with CT: *Brit J Radiol* 2000; 71: 907-912.
4. Lin MF, Lau YJ, Hu BS, Shi ZY, Lin YH. Pyogenic Psoas Abscess: Analysis of 27 cases. *Chung Hua Min Kuo Wei Sheng Wu Chi Mien I Hsueh Tsa Chih* 1999; 32: 261-268.
5. Desandre A, Cottone F, Evers M. Iliopsoas Abscess: Etiology, Diagnosis and Treatment: *Am Surg* 1995; 61: 1087-1091.
6. Breese JS, Edwards M. Psoas Abscess in Children: *Pediatr Infect Dis J* 1990; 9: 201-206.
7. Hickey NAJ, White PC. Septic Arthritis of a Lumbar Facet Joint Causing Multiple Abscesses. *Clin Radiol* 2000; 55: 481-483.
8. Dahniya MH, Hanna RM, Grexa E, Cherian MH, Niazy MN, Badr S. Percutaneous Drainage of Tuberculous Iliopsoas Abscesses under image guidance. *Australian Radiology* 1999; 43: 444-447.
9. Mueller PR, Ferrucci JT, Wittenberg J, Simeone JF, Butch RJ. Iliopsoas Abscess: Treatment by CT guided percutaneous catheter drainage: *AJR Am J Roentgenol* 1984; 142: 359-362.