

## Case Report

# Obstetric performance of a patient with multiple uterine and cervical fibroids and expectant management of retained placenta

*Mahfuza H. Begum, MD, MRCOG, Mohamed S. Mustafa, MD, MRCOG.*

## ABSTRACT

The aim of this case report is to describe the obstetric performance of a patient with multiple uterine and supravaginal cervical fibroids. A 36-year-old, gravida 3 para 0+2 with multiple uterine and cervical fibroids presented with inevitable abortion at 17 weeks gestation. She had a spontaneous rupture of membranes followed by expulsion of fetus as breech with entrapment of aftercoming head by a cervical fibroid. Oxytocin infusion and digital traction were able to deliver the fetus. The placenta, however, was trapped in the fundal area and could not be delivered under general anesthesia because of mechanical obstruction by the fibroid. Expectant management was successful in expulsion of the placenta within 7 days without complication.

Saudi Med J 2002; Vol. 23 (11): 1405-1407

Uterine leiomyomas (fibroids) are the most common pelvic tumors in women with a clinical incidence of 20-25%.<sup>1</sup> They mostly occur during the late child bearing age beyond 30-35 years. Most of the fibroids are situated in the body of the uterus. The paucity of smooth muscle elements in the cervical struma makes leiomyomas arising primarily in the cervix uncommon.<sup>2</sup> Cervical fibroids are usually confined to the supra-vaginal portion and are either interstitial or subserous. They pose particular difficulties during pregnancy, labor, cesarean section, myomectomy and hysterectomy.

Pregnancy can take place with a fibroid uterus and can continue successfully without any adverse affect. However, when the fibroids are multiple, large and located in the lower uterine segment and cervix, they can adversely affect the obstetric outcome as described in our case. In this case, there was a unique clinical combination of multiple uterine and cervical fibroids, infertility, abortions, premature

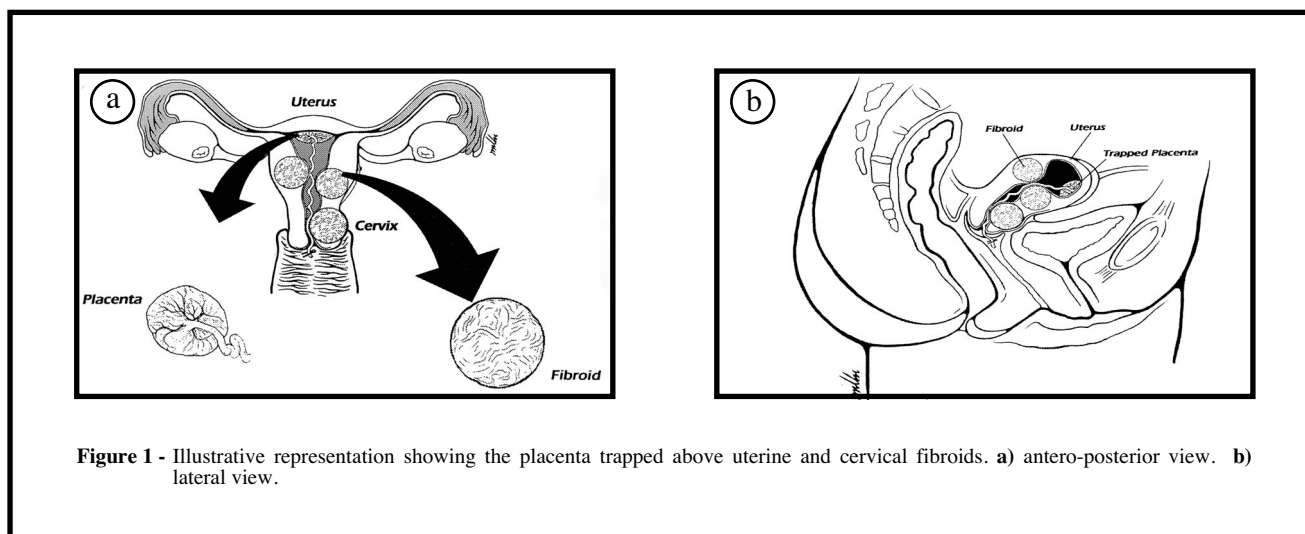
rupture of membranes, breech presentation, arrest of aftercoming head and retained placenta which, was successfully managed conservatively. One similar case has been previously reported in the literature in which retained placenta was treated by Prostaglandin E2 infusion but required prolonged hospital stay. She was also readmitted due to infection of the fibroid, which needed to be removed through the vagina.<sup>3</sup>

**Case Report.** A 36-year-old woman, gravida 3 para 0+2 was admitted to King Fahad National Guard Hospital (KFNGH), Riyadh, Kingdom of Saudi Arabia, with inevitable abortion at 17 weeks gestation after 10 years of secondary infertility. Her 2 previous pregnancies ended in complete miscarriages at 8 and 10 weeks gestation. She had multiple uterine and cervical fibroids. She had hysteroscopic removal of a submucous fibroid in

From the Department of Obstetrics & Gynecology, King Fahad National Guard Hospital, Riyadh, Kingdom of Saudi Arabia.

Received 22nd April 2002. Accepted for publication in final form 14th July 2002.

Address correspondence and reprint request to: Dr. Mahfuza H. Begum, Consultant, Department of Obstetrics & Gynecology (#1216), King Fahad National Guard Hospital, PO Box 22490, Riyadh 11426, Kingdom of Saudi Arabia.



**Figure 1** - Illustrative representation showing the placenta trapped above uterine and cervical fibroids. a) antero-posterior view. b) lateral view.

June 2000 at KFNGH in the assisted conception unit, following which she had a failed in vitro fertilization (IVF) cycle. She was then advised to have myomectomy before further attempts at IVF. However, she became pregnant spontaneously before myomectomy. She had no antenatal care during the current pregnancy.

On admission, the uterine size corresponded to 22 weeks gestation. An abdominal ultrasound scan showed a 17-week single live fetus presenting as breech with both feet protruding through the dilated cervix and a fundal anterior placenta and 3 large fibroids, one posterior and 2 on the anterior aspects of the uterus. The largest one was a supra-vaginal cervical fibroid measuring 9 x 8 x 9 cm. One day later, she had spontaneous rupture of membranes (SROM). In view of her obstetric history, the patient opted for conservative management. However, after 48 hours of SROM, she complained of severe abdominal pain and started to abort. She expelled the fetus down to the level of neck with the head entrapped by the cervical fibroid. With the help of intravenous oxytocin infusion and digital traction, it was possible to deliver the head of the fetus. However, the placenta was retained for 2 hours. As there were no signs of placental separation, she was taken for manual removal under general anaesthesia (GA). Examination revealed the cervix was 3 cm dilated, but the presence of the fibroid in the supravaginal cervix and anterior uterine fibroid prevented the digital exploration of the cavity. The placenta was trapped in the fundal area. The uterine cavity was felt to be squashed by the anterior lower uterine and cervical fibroids. Digital and instrumental manipulation failed to remove the placenta. As the patient was not actively bleeding, the procedure was abandoned. It was decided to manage her expectantly. The estimated total blood loss was approximately 800ml. The situation was

explained to the couple, and they were counseled for the possibility of hysterotomy, hysterectomy or both in case of life threatening hemorrhage. Two units of cross-matched packed red blood cells were transfused as her hemoglobin was 8.9g/dl and another 2 units were kept on standby. She was kept in the high-risk area for close observation and prophylactic broad-spectrum antibiotics were commenced.

The following day the patient developed low-grade fever, but there were no other signs of infection. Septic work-up was all within normal limits. Ultrasound scan was repeated which showed the placenta trapped above the uterine and cervical fibroids (**Figure 1a and 1b**). On the 3rd postoperative day, she experienced crampy abdominal pain and started expelling placental tissues in pieces. The expulsion of placental tissues continued on and off for 4 days. On day 9, a transvaginal ultrasound scan showed an empty uterus. She was discharged home on day 9 with minimal vaginal bleeding and a one-week appointment to the outpatient clinic. She was advised to continue with oral ferrous sulphate twice a day as her hemoglobin was 9.8 g/dl.

She was followed-up 3 times in the clinic, and remained completely asymptomatic. The uterine size reduced to an 18-week size. She was fully counseled regarding her chances of successful pregnancy after myomectomy and intra-operative technical difficulties of myomectomy particularly for cervical fibroids. She opted for myomectomy with all its potential complications.

**Discussion.** Uterine fibroids are extremely common during the child-bearing period. They occur in 20-40% of women beyond 30-35 years of age.<sup>4</sup> With the increasing age of the obstetric population and wide spread use of sonography, uterine fibroids are more frequently detected during pregnancy.<sup>5</sup>

Most of the fibroids are situated in the body of the uterus but in 1-2% of cases they are confined to the cervix and usually to its supra-vaginal portion.<sup>6</sup> Cervical fibroids pose particular difficulties in pregnancy, labor, cesarean section, myomectomy and hysterectomy.

The effect of myomas on fertility remains controversial. The mechanism by which myomas are thought to cause infertility include occlusion of the fallopian tubes by large myomas and alteration in the normal relation between the cervix and the vaginal pool of semen. Submucosal fibroids can affect implantation and growth of the embryo because of a thin, poorly vascularized endometrium.<sup>7</sup> This could be the explanation for the 10 years of secondary infertility in our case who became pregnant spontaneously after hysteroscopic resection of the submucous fibroid.

Uterine fibroids are also associated with an increased risk of abortion by several possible mechanisms, such as increased irritability and contractility due to rapid growth and consequent degeneration<sup>8,9</sup> and poor placentation associated with uterine corpus fibroids.<sup>5</sup> The latter could be the causative factor of the 2 early miscarriages in this patient. Large multiple fibroids can cause late abortions due to accommodation problems which may be responsible for 2nd trimester abortion in our patient.

Other obstetric complications associated with uterine fibroids include pain and discomfort, premature rupture of membranes,<sup>10</sup> malpresentation and premature contractions when the fibroids are multiple.<sup>5</sup> In this case, breech presentation and entrapment of aftercoming head of the fetus can be explained by the multiple fibroids and presence of a big fibroid at the supra vaginal part of the cervix. Although the uterus responds poorly to oxytocin at this stage of pregnancy, in this case intravenous oxytocin infusion and digital traction were able to deliver the fetal head. Retained placenta is another known complication associated with multiple uterine and cervical fibroids.<sup>5</sup> It is more frequent when fibroids are present in the lower uterine segment and cervix representing some degree of mechanical obstruction as in our case and another reported case in the literature.<sup>3</sup> The conservative expectant management of retained placenta is usually associated with increased risk of infection, hemorrhage, anemia and pain. Fortunately, in this case conservative management was successful in expulsion of the whole placenta in pieces without any hemorrhagic or infectious complications.

Other problems of uterine fibroids in pregnancy are increased frequency of cesarean delivery due to obstructed labor, particularly when the fibroids are multiple and located in the lower uterine segment and cervix.<sup>5</sup> Cesarean section can be complicated by

cesarean hysterectomy due to intra-operative and postpartum hemorrhage. The outcome of pregnancy with multiple uterine fibroid depends mainly on the location of fibroids in relation to placental site. However, in spite of all these problems, pregnancy can continue successfully without any adverse effect, even with a large myomatous uterus by some compensatory adaptive mechanism directed towards the preservation of pregnancy.<sup>11-13</sup>

In this case, there was a unique clinical combination of multiple uterine and cervical fibroids, infertility, abortions both early and mid-trimester, premature rupture of membranes, breech presentation, mechanical obstruction of aftercoming head and retained placenta. In the case of mechanically retained placenta, conservative expectant management with close monitoring of the clinical condition, prophylactic antibiotic and blood transfusion when required may have a better outcome in the stable not bleeding patient, instead of hazardous operative intervention or medical treatment by methotrexate.

**Acknowledgment.** We would like to acknowledge Miss Linda Hannig and Mr. Christopher G. Miller, Media Service, King Fahad National Guard Hospital, Riyadh, KSA for their help with illustrations.

## References

1. Elizabeth AS, Adriana F. The future of fibroid therapy. *Contemporary Ob/Gyn* 2000; July: 26-32.
2. Edward CH, Martin LP. Benign disorders of the uterine cervix. In: Alan HD, Martin LP, editors. *Current Obstetric & Gynecologic Diagnosis & Treatment*. New Jersey (USA): Appleton & Lange; 1994. p. 713-730.
3. Gleeson NC, Onwede JL. Uterine Leiomyoma causing retained placenta. *Br J Clin Pract* 1990; 44: 689-690.
4. Gompel C, Silverberg SG. *Pathology in Gynaecology and Obstetrics*. 2nd ed. Philadelphia (PA): Lippincott; 1977. p. 184-190.
5. Lev-Toaff AS, Coleman BG, Arger PH, Mintz MC, Arenson RL, Toaff ME. Leiomyomas in pregnancy: Sonographic study. *Radiology* 1987; 164: 375-380.
6. Tindall VR. Tumours of the corpus uteri. In: Jeffcoate's *Principles of Gynaecology*. London (UK): Butterworth & Co Ltd; 1987. p. 417-432.
7. Michael MG, Mitchell SR. Traditional Surgical Approaches to Uterine Fibroids. *Clin Obstet Gynecol* 2001; 44: 385-400.
8. Stevenson CS. Myomectomy for improved fertility. *Fertil Steril* 1964; 15: 367-384.
9. Ingersoll FM. Fertility following myomectomy. *Fertil Steril* 1963; 14: 596-602.
10. Winer-Muram HT, Muram D, Gillieson MS. Uterine myomas in pregnancy. *J Can Assoc Radiol* 1984; 35: 168-170.
11. Sidorova IS, Zykin BI, Ametov AS. State of the fetoplacental system and the characteristics of fetal intrauterine development in uterine myoma patients. *Akush Ginekol (Mosk)* 1980; 5: 31-33.
12. Shmakov GS. Fetoplacental interrelationship in uterine myoma. *Sov Med* 1980; 2: 48-51.
13. Zheleznov BI, Sidorova IS, Men-shikova GP. Structural and morphofunctional characteristics of the placenta in patients with uterine myoma. *Akush Ginekol (Mosk)* 1982; 1: 44-47.