

Case Report

Treatment of tuberculous spondylitis at the cervicothoracic junction

Clinical impact of surgery by means of a sternotomy

Stefan M. Knoeller, Dr. med, MD, Ludwig F. Brethner, PD, Dr. med.

ABSTRACT

The operative treatment of tuberculous spondylitis remains a challenge with regard to the surgical approach to the cervicothoracic junction. In addition, it is difficult to restore the resected vertebral bodies. Two cases of tuberculous spondylitis in this area are presented. The first case concerns a 25-year-old African patient suffering from the effects of tuberculous spondylitis: Destruction of vertebral bodies dorsal (D)1, D2, and D3, kyphosis coupled with compression of the spinal cord, as well as incomplete motor and sensory paraplegia (Frankel grade C). The operative treatment of tuberculous spondylitis that is described, approached the cervicothoracic junction by means of a sternotomy. Corpectomy of vertebral bodies D1 through D3 were followed by their restoration with the help of a titanium cage. As a result, the paraplegia disappeared. Ventral decompression was followed by dorsal instrumentation. The results of the operation are decompression of the spinal cord, correction of the kyphosis, and stable fusion followed by restitution of the paraplegia. Primary stability was provided by the use of a titanium cage and dorsal instrumentation. There was no need for an external brace. There was no loss of correction 3 years after the operation. The 2nd case concerns a 49-year-old European patient suffering from thoracic pain radiating around the chest. A partial destruction of D2 and D3 with kyphosis and compression of the spinal cord because of a tuberculous spondylitis were detected, neurological deficits were not found. The corpectomy of D2 and D3 were proceeded by means of a sternotomy, the defect was restored with the help of a titanium cage. Due to the use of a ventral Morscher plate an additional dorsal instrumentation was not necessary. The patient was fixed in a minerva plaster for 3 months. There was no loss of correction 2 years after the operation. Both patients are manual workers and postoperatively adapted to their former work.

Saudi Med J 2002; Vol. 23 (11): 1414-1418

Tuberculous spondylitis occupies a special place among the different types of spondylitis. The causative organism is *Mycobacterium tuberculosis*, but sometimes *Mycobacterium bovis* or atypical types are found. Tuberculosis affects the skeletal system in 1%¹ of patients in Western countries and 10%² of patients in endemic regions. Up to 50% of

these affected people have tuberculosis of the spine.³ It is often found in undeveloped countries with problems of overcrowding and malnutrition.⁴⁻⁶ Adults and children of all age groups are affected there. In Western countries, it primarily affects the old, alcoholics and heroin addicts.^{7,4} Tuberculosis of the spine remains the most common cause of

From the Department of Orthopedic Surgery (Knoeller), Orthopädische Universitätsklinik and the Department of Thoracic Surgery (Brethner), Chirurgische Universitätsklinik, Freiburg Germany.

Received 25th March 2002. Accepted for publication in final form 15th June 2002.

Address correspondence and reprint request to: Dr. Stefan M. Knoeller, Department of Orthopedic Surgery Freiburg, Hugstetter Str. 55, D 79106 Freiburg, Germany. Tel. +49 761 2610. Fax. +49 761 270 2894. E-mail: knoeller@ch11.uni-freiburg.de

nontraumatic paraplegia.⁸ Up to 40% of cases with skeletal tuberculosis will develop a neurologic deficit.⁹⁻¹¹ Surgery is indicated in case of neurologic deficit, paraspinal abscess, severe bone destruction or deformity. The procedure includes drainage of the paravertebral abscess, debridement of infected bone and the sequestered disc, decompression of the spinal cord, and stabilization of the spine.^{12,13} The procedure was first described by Ito et al.¹⁴ The literature describes constructs of autogenous bone graft coming from the ileac crest or from the rib and allograft. Using this procedure, the extent of bony fusion is 95%.^{11,15} Nevertheless, surgery at the cervicothoracic junction is a challenge with respect to the approach and stabilization.

Case Report. Patient One. A 25-year-old African man with destruction of vertebral bodies dorsal (D)1, D2 and D3 combined with incomplete

motor and sensory paraplegia was admitted to our clinic (Frankel grade C). Gait disturbance had appeared several days previously. In the blood the cyclic adenosine monophosphate receptor protein (CRP) was found 7.7mg/dl, erythrocyte sedimentation rate (ESR) 68/115 and white blood cell count (WBC) 6600/nl. Mantoux test was positive. The neurological examination showed the following: A sensory level at C7/D1 with unsteady gait, signs of a thoracic myelopathy, and progressive paralysis of the legs with a strength of 3/5. Plain radiographs showed bone rarefaction and destruction of the vertebral bodies D1, D2 and D3 accompanied by kyphosis. The magnetic resonance (MR) imaging not only confirmed bone destruction but also showed ventral compression of the spinal cord. The spinal canal was narrowed to 50% (**Figures 1a & b**). Because of the paraplegia, we decided to perform a sternotomy immediately to approach the

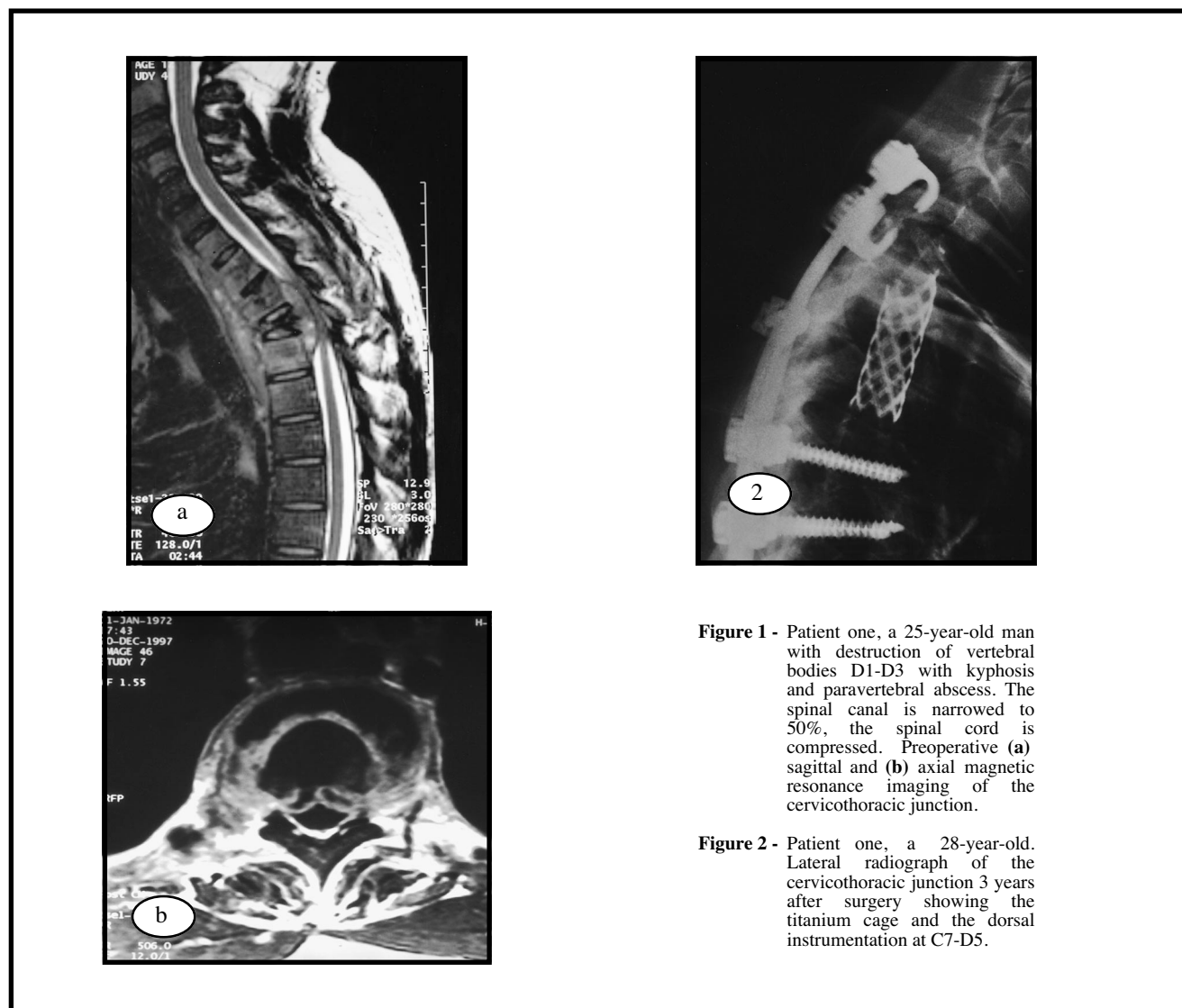


Figure 1 - Patient one, a 25-year-old man with destruction of vertebral bodies D1-D3 with kyphosis and paravertebral abscess. The spinal canal is narrowed to 50%, the spinal cord is compressed. Preoperative (a) sagittal and (b) axial magnetic resonance imaging of the cervicothoracic junction.

Figure 2 - Patient one, a 28-year-old. Lateral radiograph of the cervicothoracic junction 3 years after surgery showing the titanium cage and the dorsal instrumentation at C7-D5.

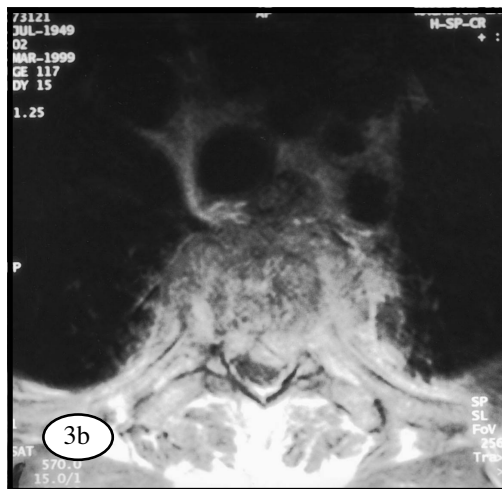
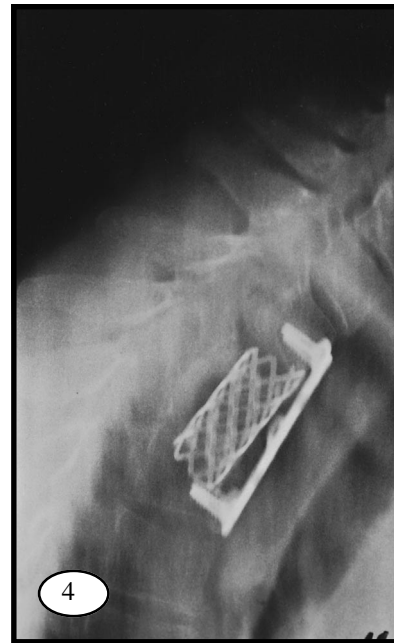
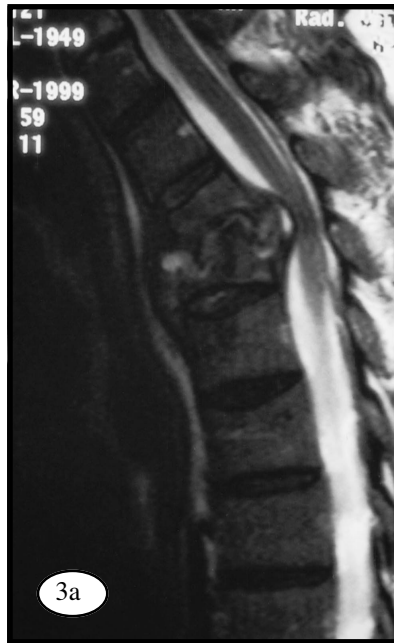

Figure 3 - Patient 2, a 49-year-old. Destruction of vertebral bodies D2 and D3 with kyphosis and paravertebral abscess. The spinal cord is narrowed to 50%, the spinal cord is compressed. Preoperative (a) sagittal and (b) axial magnetic resonance imaging of the cervicothoracic junction.

Figure 4 - Patient 2, a 51-year-old. Lateral tomography of the cervicothoracic junction 2 years after surgery showing the titanium cage and the ventral instrumentation at D1-D4.

cervicothoracic junction and effect decompression of the spinal cord by corpectomy of D1, D2 and D3. The defect was restored with a titanium cage (DePuy Corp, Warsaw, Indiana (IN), United States of America (USA) described by Harms¹⁶ and filled with autogenous bone graft taken from the dorsal iliac crest. Due to a high aortic arch, it was not possible to fix a ventral instrumentation. No intraoperative complications occurred, and the wound healing was inconspicuous. Acid-resistant rods were isolated in the secretion. The neurologic findings disappeared postoperatively. Motor strength returned first, followed 2 weeks later by sensation. The patient was

confined to bed for reasons of instability. After complete neurological restitution, we inserted dorsal instrumentation with Moss-Miami titanium (DePuy Corp, Warsaw, IN, USA) from Cervical (C)7 to D6 and continued with dorsal spinal fusion using autogenous bone graft from the dorsal iliac crest. Lamina hooks were used in C7, and pedicle screws were inserted in D5 and D6. The instrumentation was connected using a 5 mm rod. Titanium was used that still allowed for MR imaging. Postoperative x-rays showed a complete correction of the kyphosis. Because of high primary stability, we decided upon a postoperative treatment without external support.

Chemotherapy was initiated with isoniazid, rifampicin and pyrazinamide.⁸ After circulatory training and mobilization, the patient left the hospital on the 14th day after the 2nd operation. After 6 months he has returned to work. Three years after surgery the x-rays show a stable fusion of the spinal fusion without loss of correction (**Figure 2**).

Patient 2. A 49-year-old European man with almost complete destruction of vertebral bodies D2 and D3 combined with thoracic pain radiating around the chest was admitted to our clinic. In the blood the CRP was found 7.5mg/dl, ESR 27/57 and WBC 7400/nl. Mantoux test was also positive. The roentgenographic findings showed bone rarefaction and destruction of the vertebral bodies D2 and D3 accompanied by kyphosis. The MR imaging not only confirmed bone destruction but also showed ventral compression of the spinal cord. Although the spinal channel was narrowed to nearly 50% the neurological examination showed no deficits (**Figures 3a & b**). Because of the findings we performed a sternotomy to approach the cervicothoracic junction and effect decompression of the spinal cord by corpectomy of D2 and D3. The defect was restored by the above mentioned titanium cage and filled with autogenous bone graft taken from the dorsal iliac crest combined with a ventral Morscher plate (Stratec Medical, Oberdorf, Switzerland). No intraoperative complications occurred, and the wound healing was inconspicuous. Acid-resistant rods were isolated in the secretion. Because of the use of the ventral plate an additional dorsal instrumentation was not applied. The patient was fixed in a minerva cast for 3 months as he refused a Halo-body-jacket. Chemotherapy was initiated with isoniazid, Rifampicin and Pyrazinamide.¹⁷ After 8 months he has returned to work. There was no loss of correction 2 years after the operation (**Figure 4**).

The anterior approach to the cervicothoracic junction is a particularly difficult region of the spine to approach. It offers the distinct advantage of good exposure and working room from C4-T4. The patient is placed supine on the operating table, and general endotracheal anesthesia and a stomach tube to identify the esophagus is included. The neck is hyperextended and rotated to the right, and a rolled towel is placed between the scapulae. Intravenous antibiotics are given, and all areas are prepared and draped in sterile fashion. A skin incision is made over the anterior aspect of the sternum. The cranial limb is placed along the anterior end of the sternocleidomastoid muscle. After the platysma muscle is incised, the strap muscles (sternohyoid, sternothyroid and omohyoid muscle) must be sectioned. The sternocleidomastoid muscle can be retracted easily after this, and then the inferior thyroid vein must be ligated. Attention is turned to the proximal portion of the wound, where dissection is carried out in a plane lateral to the esophagus and

trachea, but medial to the carotic sheath. The recurrent laryngeal nerve is found consistently between the trachea and the esophagus on the left side of the neck. It is often large but nonetheless must be retracted safely. Now the presternal fascia is cut to the periost, the processus xiphoideus is delivered from the abdominal muscles, and the mediastinum is detached from the sternum. A Gigli saw is now used to cut the sternum. The hemostasis along the sternotomy should not be carried out using bonewax to avoid sternal pseudarthrosis. Retractors are placed, and then the pericard and the brachiocephalic vein and the aortic arch are exposed. After ligation of the left brachiocephalic vein and the prevertebral fascia the ventral aspect of T1-T4, T5 vertebral bodies sometimes come to view. An intraoperative radiograph should then be performed for precise anatomic location. Next, the corpectomies with a spinal cord decompression are performed. The defect is restored by a titanium cage, filled with autogenous bone graft. If possible we use a ventral cervical plate. Closure of the wound follows thorough irrigation and hemostasis and placement of 2 deep drains. The sternotomy is closed by non-resorbable suture, and the strap muscles are reapproximated. Closure of the subcutaneous tissue and skin is routine.

Discussion. The described technique is controversial as of usage of metal implants in the inflammation site. There is no doubt regarding the necessity of ventral exploration and decompression in these cases as of the presence of a paraspinal abscess, the presence of severe bony destruction and deformity, neurologic deficit with spinal cord compression.¹⁸ Instead of using metal implants, a construct of autogenous graft, iliac crest or rib, and allograft especially fibula would have been possible. After corpectomy of 2 or 3 vertebral bodies at the cervicothoracic junction the danger of dislocation of the bony construct with further kyphosis is obvious as of difficulties to fix and there would be need for an external fixation for several months. Kemp et al¹⁹ noted poor results with autogenous rib grafting, particularly in adults, reporting a 62% fusion rate, 32% incidence of graft fracture, and mean kyphotic increase of 20° in a series of 63 patients. Partial collapse occurred in some cases due to ribcraft penetrating of the vertebral endplate. Better results are reported by using vascularized rib crafts for stabilization. In a series of 25 patients with a mean grafting of 4 vertebral level no graft fracture occurred, but the mean loss of correction after 2-years was 5° or more in 28% of patients.²⁰ The use of titanium cages in cases of tuberculous spondylitis to the authors knowledge is not reported until today, although the usages of metal implants in tuberculous cases were studied both by laboratory and clinical trail. Mironski in 1968²¹ and Wolkow in 1969

reported of arthroplasty with metal joint prosthesis, Iukhno in 1968 reported the usage of metal screws in reconstructive resection of the coxofemoral joint in patients with tuberculosis of the hip joint.²²⁻²⁴ Fibular allograft allows for good structural support over a large defect, but a large amount of cortical bone slow rates of incorporation, sometimes over a period of years are reported.²⁴ The reported technique shows the advantage of high primary stability with a cage filled with autogenous iliac crest graft, that provides a bony fusion rate of 95% at 10-years follow-up according to the literature.^{11,19,25} Regarding the literature there are 4 surgical approaches to the anterior aspect of the cervicothoracic junction. The main difference between the techniques is found in the variable degree of exposure between cervical and thoracic spine and the association with its own morbidity. The low anterior Smith-Robinson approach affords access from C2 to T1 or T2 in most patients. With this approach alone a further extension to the upper thoracic spine can not be achieved. The parascapular approach to the cervicothoracic junction differs from thoracotomies below T4 as the scapula must be freed from its posterior muscular and tendinous attachments to allow forward retraction which means extensive preparation during surgery and aggravate postoperative mobilization of the shoulder. Efforts to widen the anterior exposure have led to the development of transsternoclavicular approaches. Proceeding an osteotomy at the medial end of the clavicle and manubrium the clavicle can be used as a strut graft. The major disadvantage of this approach is the instability of the clavicle and function of the shoulder girdle. The midline sternal splitting approach to the cervicothoracic junction follows Cauchoux's 1957. Because of the reported disadvantage of the narrow and deep operation wound the approach was used modified by Knoeller et al.^{3,26} By using a titanium cage described by Harms et al¹⁶ filled with autologous bone graft and combining it with dorsal titanium instrumentation and spinal fusion or a ventral plate, primary stability is achieved in a way that renders the use of an external brace unnecessary and still allows for MRI. The 2 and 3-years follow-up showed no loss of correction.

References

- Davidson PT, Horowitz I. Skeletal tuberculosis. A review with patient presentation and discussion. *Am J Med* 1970; 48: 77-84.
- Govender S, Charles RW, Naidoo KS, Goga IE. Results of surgical decompression in chronic tuberculous paraplegia. *S Afr Med J* 1988; 74: 58-59.
- Cauchoux J, Binet JP, Evrard J. Les voies d'abord inhabituelles dans l'abord des corps vertebraux, cervicaux et dorsaux. *Ann Chir* 1957; 74: 1463-1472.
- Friedman B. Chemotherapy of tuberculosis of the spine. *J Bone Joint Surg (Am)* 1966; 48: 451-474.
- Lifeso RM, Weaver P, Harder EH. Tuberculous spondylitis in adults. *J Bone Joint Surg (Am)* 1985; 67: 1405-1413.
- Martin NS. Tuberculosis of the spine: A study of the results of treatment during the last 25 years. *J Bone Joint Surg (Br)* 1970; 52: 613-628.
- Forlenza SW, Axelrod JL, Grieco MH. Pott's disease in heroin addicts. *JAMA* 1979; 241: 379-380.
- Scrimgeour EM, Kaven J, Gajdusek DC. Spinal tuberculosis the commonest cause of non-traumatic paraplegia in Papua New Guinea. *Trop Geogr Med* 1987; 39: 218-221.
- Bosworth DM, Pietra AD, Rahilly G. Paraplegia resulting from tuberculosis of the spine. *J Bone Joint Surg (Am)* 1953; 35: 735-739.
- Cleveland M. Tuberculosis of the spine. A clinical study of 203 patients from Sea View and St. Luke's Hospital. *Tuberculosis* 1940; 41: 215-218.
- Hodgson AR, Stock FE. Anterior fusion for the treatment of tuberculosis of the spine. The operative findings and results of treatment in the first onehundred cases. *J Bone Joint Surg (Am)* 1960; 42: 295-298.
- Girdlestone GR. The operative treatment of Pott's paraplegia. *Br J Surg* 1931; 19: 121-123.
- Moon MS. Tuberculosis of the spine. Controversies and a new challenge. *Spine* 1997; 22: 1791-1797.
- Ito H, Tsuchiya J, Asami G. A new radical operation for Pott's disease: Report of ten cases. *J Bone Joint Surg* 1934; 16: 499-504.
- Slucky AV, Eismont FJ. Spinal infections. In: Bridwell KH, DeWald RL, editors. The textbook of spinal surgery. 2nd ed. Philadelphia (PA): Lippincott-Raven Publishers; 1997. p. 2160-2165.
- Harms J, Stoltze D, Biedermann L, editors. Wirbelkörperersatz-, platzhalter. Oral Presentation. Proceedings of the Workshop on correction and stabilisation of spinal diseases with the Moss system; 1990 June 29; Nauheim, Germany.
- Upadhyay SS, Saji MJ, Yau AC. Duration of antituberculosis chemotherapy in conjunction with radical surgery in the management of spinal tuberculosis. *Spine* 1996; 21: 1898-1903.
- Kirkaldy-Willis WH, Thomas G. Anterior approaches in the diagnosis and treatment of infections of the vertebral bodies. *J Bone Joint Surg (Am)* 1965; 47: 87-92.
- Kemp HBS, Jackson JW, Jeremiah JD, Cook J. Anterior fusion of the spine for infective lesions in adults. *J Bone Joint Surg (Br)* 1973; 55: 715-734.
- Bradford DS, Daher YH. Vascular rib grafts for stabilisation of kyphosis. *J Bone Joint Surg (Br)* 1986; 68: 357-361.
- Mironski E. Arthroplasty using metal cups in tuberculosis of the hip in growing subjects. *Chirurgia Narzadow Ruchu i Ortopedia Polska* 1894; 33: 637-643.
- Wolkow MW. Alloplastik von Metallgelenken. *Acta Orthop Scand* 1969; 40: 571-576.
- Iukhno AI, Fedoruk FF. Reconstructive resection of the coxofemoral joint with fixation of the resected ends with a metal screw. *Probl Tuberk* 1968; 46: 88-89.
- Enneking WF, Burchardt H, Puhl JJ, Pitrowski G. Physical and biological aspects of repair in dog cortical-bone transplants. *J Bone Joint Surg (Am)* 1975; 57: 237-252.
- Medical Research Council Working Party on Tuberculosis of the Spine. A 10 year assesment of controlled trail comparing debridement and anterior spinal fusion in the management of tuberculosis of the spine in patients in standard chemotherapy in Hong Kong. *J Bone Joint Surg (Br)* 1982; 64: 393-398.
- Knoeller SM, Brethner L. Surgical treatment of the spine at the cervicothoracic junction: An illustrated review of a modified sternotomy approach with the description of tricks and pitfalls. *Arch Orthop Traumatol Surg* 2002; 365-368.