

Spinal brace in tuberculosis of spine

AbdulNasser A. Alwali, MBChB, FICMS (Ortho).

ABSTRACT

Objective: To present our experience in the management of 22 patients with thoracolumbar spine tuberculosis (TB) using a chemotherapy regimen and locally custom-made spinal brace.

Methods: Twenty-two patients with thoracolumbar spine TB had been treated conservatively by chemotherapy and locally custom-made spinal brace and followed for 36-48 months from June 1996 to June 2000 in the Department of Orthopedics and Trauma, Algamhoria Teaching Hospital, Aden, Republic of Yemen. In 14 cases, 2 vertebrae were involved, whereas in 8 cases involvement was only of one vertebra. All had persistent back pain: 2 had neurological deficit, Frankel grade A and B (9%), and 12 (54%) had gibbus deformity.

Results: At the end of the observation period, all patients had no pain (based on the adjective rating scale). Fourteen thoracic and 3 psoas abscesses resolved by 18 months. Four cases (18%) had deterioration of the angle of kyphosis. Five cases (22.5%) had progressive vertebral loss. Twelve cases (84%) had bony fusion at 36 months.

Conclusion: Chemotherapy regimen and locally custom-made spinal brace is not costly, needs neither admission nor surgical intervention that demands skills and experience and can be recommended for uncomplicated thoracolumbar spinal TB.

Saudi Med J 2002; Vol. 23 (12): 1483-1488

A series of collaborative controlled clinical trials with interrelated experimental designs have been undertaken by the Medical Research Council Working Party on Tuberculosis (TB) (Fulham Road, London, England) of the spine to investigate several different methods of treating spinal TB. The studies were carried out in Mason and Pusan in Korea, Bulawayo, in Zimbabwe, Johannesburg and Pretoria in South Africa, and in Hong Kong. The methods of treatment for comparison in each country alone were chosen on the basis of the locally available resources.¹ Ambulant outpatient chemotherapy for 18 months with para-aminosalicylic acid (PAS) plus isoniazid (INH) was successful in the treatment of the great majority of patients in Mason, Pusan and Bulawayo.² The addition of streptomycin daily for the first 3 months did not improve the results, whereas the application of a plaster of paris jacket

for 9 months, as studied in Pusan, conferred no extra benefit, neither did a debridement operation in Bulawayo.² In Hong Kong, the radical operation of resection of the tuberculous focus and repair of the resultant gap by bone-grafting were produced better results.³ The purpose of this study was to present our experience in the conservative treatment of spinal TB using a chemotherapy regimen and locally custom-made spinal brace.

Methods. Twenty-two cases of TB of spine were treated between June 1996 to June 2000. There were 15 females and 7 males with mean age of 33 years (5-60 years) (**Table 1**), and the mean follow-up period was 42 months (36-48 months). The criteria for inclusion in the study was: 1) Patients of any age who had no any other systemic spinal disorders,

From the Department of Orthopedics & Trauma, Faculty of Medicine, University of Aden, Aden, *Republic of Yemen*.

Received 29th January 2002. Accepted for publication in final form 12th August 2002.

Address correspondence and reprint request to: Dr. AbdulNasser A. Alwali, PO Box 14005, Aden, *Republic of Yemen*. Tel. +967 (2) 232259. Fax. +967 (2) 341391. E-mail: alnasser@y.net.ye

namely, ankylosing spondylitis or rheumatoid arthritis. 2) Patient not treated before for the same problem. 3) Patient who had thoracic or thoracolumbar spine TB.

Treatment protocol. When spinal TB was clinically and radiographically diagnosed, 3 anti-TB agents (streptomycin, INH, rifampicin)^{2,4} were given immediately for 2 months, followed by rifampicin and INH for 16 months. Complete bed rest at home was advised until the following criteria were achieved (usually 2 months):⁵ 1) The patient had no pain (based on the adjective rating scale [ARS]). 2) General condition good (good sleep, good appetite). 3) Kyphosis not increasing. 4) Night temperature remains normal. 5) Weight increasing 6) No radiographic evidence of further progression of the process.² Locally custom-made spinal brace worn from the start for 12 months (the brace is designed individually for each patient from leather, canvas and 2 iron bars posteriorly at the paraspinal lines bilaterally, 2 iron bars at the mid-axillary lines bilaterally and 2 curved iron bars passing transversally joining posteriorly the paraspinal and axillary bars, and fixed anteriorly by belts) (**Figure 1**). Patients were assessed clinically – pain (based on the ARS), tenderness, appetite and weight improvement and radiologically once per month for the first 3 months and then at 3 months intervals thereafter. We used the following system of assessment of the radiographic findings: On anteroposterior and lateral radiographs of the whole spine the following records were included:⁶ a) The number of vertebrae involved. b) The total vertebral body loss obtained by adding together the losses including fractional losses in all affected vertebrae. c) The angle of spinal deformity as described by Konstam and Blesovsky.⁷ d) The activity of the disease according to the following classification of radiographic activity:⁶ (i) Active disease – a) loss of thin cortical outline and b) rarefaction of the affected vertebral bodies. (ii) Inactive (quiescent) disease – a) Bony fusion of the affected vertebral bodies that is continuity of trabeculae between the vertebral bodies and stout bony bridges, usually best seen in the anteroposterior view, projecting up to 2 cm wide of the vertebral bodies and showing evidence of trabecular continuity even though they are separated by small space, often no more than a hairline. b) Sclerosis of the contiguous surfaces of the affected vertebrae with reduction or disappearance of the intervening disc space. (iii) Disease of doubtful activity – the appearance of marginal sclerosis where there had been so much reduction of the vertebral bodies that there was no close apposition of the vertebrae above and below the focus of disease. Cavitation of the vertebral body or sequestrum formation was not regarded as evidence of activity. Erosion of the anterior-surface of the vertebrae by bodies coexisting with a mediastinal abscess (aneurysmal erosion) was

not regarded as vertebral involvement⁶ (**Table 2**). Twelve patients had gibbus deformity ranging from mild to severe according to Kaplan's classification.⁸ Mild angulation up to 30 degrees in 8 cases, moderate between 30-60 degrees in 2 cases, and severe was more than 60 degrees in 2 cases. For measuring the gibbus deformity a Konstam and Blesovsky method was used: Angle A was used as a measurement of gibbus deformity by the Medical Research Council Working Party in all of its reports on the subject. In this study, angle A was made by drawing a line through the superior surface of the first normal vertebra cephalad to the lesion and a line through the inferior surface of the first normal vertebra caudal to the lesion. Perpendiculars were then drawn from these lines and the angle A was measured at their intersection (**Figure 2**).⁵ One patient with complete paraplegia, and Frankel grade A had severe kyphosis and did not respond to our conservative course of treatment, the patient underwent surgical decompression and was excluded from the study. One case with incomplete paraplegia, and Frankel grade B had improved completely by the end of 18 months therapy. All cases were affected in the thoracolumbar spine (9 thoracic cases and 13 lumbar cases). The most common site affected was between D11 – L2 vertebrae (11 cases). Assessment of the loss of the vertebral body as recommended by Rajasekaran and Shanmugasundaram⁹ was carried out as follows: each vertebra was divided into 10 equal parts, based on the vertical height as measured on a lateral radiograph. The initial loss of vertebral body was assessed by measuring the loss of height in 10th, in each of the involved vertebra⁹ (**Figure 3 & 4**). Twelve patients with gibbus deformity had initial loss of the vertebral body range between 0.3-0.8. Fourteen cases with visible thoracic paravertebral abscesses on initial roentgenogram and computerized tomography (CT) scan, 3 cases with psoas abscesses seen roentgenographically as soft tissue shadows of increased density in the region of one of the psoas muscles (2 left and one right). No abscess drainage was carried out under CT scan.

Results. All cases by the end of the 3rd month had no pain (based on ARS), and slight tenderness on moderate pressure. All cases had improvement in their appetite at the end of the 2nd month and only 3 cases had no gain in weight by the end of 6 months (poor economic level), while the others started gaining weight from the 2nd month. Two cases had neurological deficit: one case was a 55-year-old female with complete paraplegia, Frankel grade A and the other case was a 46-year-old female with incomplete paraplegia, Frankel grade B. The first case did not respond to our treatment regimen and the CT scan showed severe bony cord compression; for this reason she was excluded from the study and sent for surgical intervention. The 2nd case with

Table 1 - Pre-treatment clinical findings.

Factor	n of cases (%)
Patients in the study	22 (100)
Age (years)	
1 - 5	1 (4.5)
6 - 10	1 (4.5)
11 - 15	0 (0)
16 - 20	4 (18.2)
21 - 30	5 (22.7)
31 - 40	4 (18.2)
41 - 50	5 (22.7)
>50	2 (9.1)
Sex	
Male	7 (31.8)
Female	15 (68.2)
CNS abnormality	2 (9.1)
Clinically evident abscess	3 (13.6)
n - number, CNS - central nervous system	

Table 2 - Pre-treatment radiographic findings (n=22).

Factor	n of cases (%)
Mediastinal or psoas abscess shadows	17 (77.3)
n of vertebrae involved	
1	8 (36.4)
2	14 (63.6)
Total vertebral body loss	
<1	4 (18.2)
1	4 (18.2)
2	2 (9.1)
>3	12 (54.5)
Angle of kyphosis (degrees)	
0	10 (45.4)
1 - 30	8 (36.4)
>30 - 60	2 (9.1)
>60	2 (9.1)
Radiographic activity	
Active	22 (100)
Doubtfully active	0
Quiescent	0
n - number	

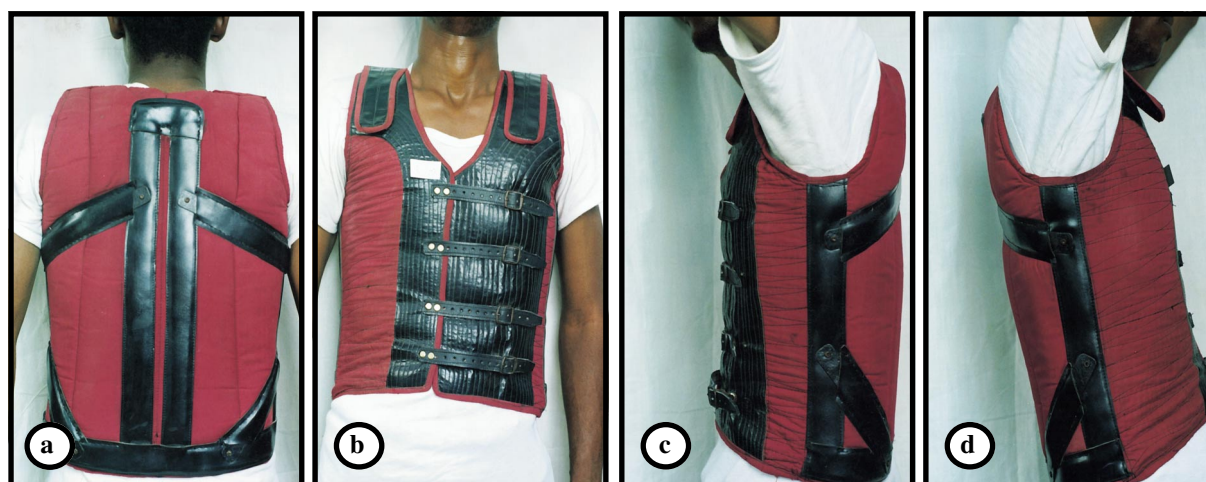


Figure 1 - Tuberculosis spinal brace showing the a) posterior b) anterior c) left lateral view d) right lateral view.

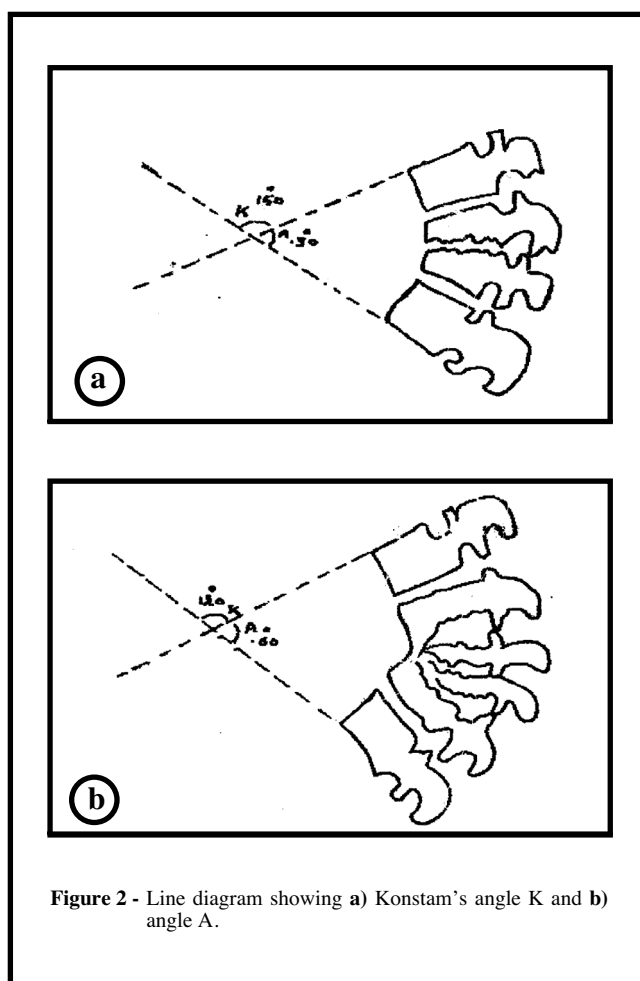


Figure 2 - Line diagram showing a) Konstam's angle K and b) angle A.

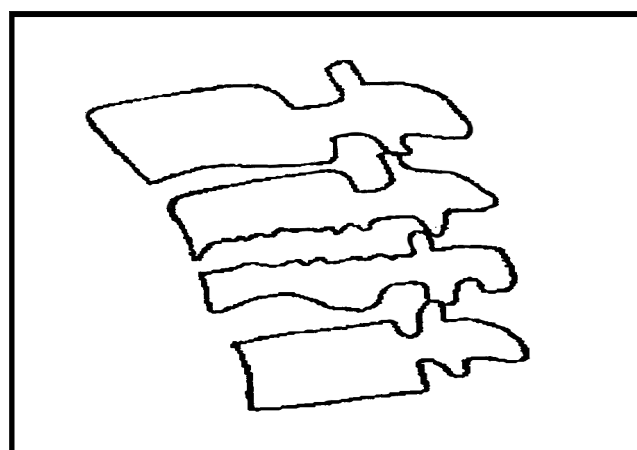


Figure 4 - The index of the vertebral body is the sum of the proportion of height loss for each of the vertebrae that the lesion involves.

Table 3 - Resolution of clinically and radiologically present abscess from admission to 36 months.

Abscess of localization	Thoracic abscess n (%)	Psoas abscess n (%)
Present on admission	14 (63)	3 (13)
Resolved by		
6 months	- (0)	1* (4.5)
12 months	10 (45)	2 (9)
18 months	4 (18)	- (0)
36 months	- (0)	- (0)
>36 months	- (0)	- (0)
*abscess drained surgically. n - number		

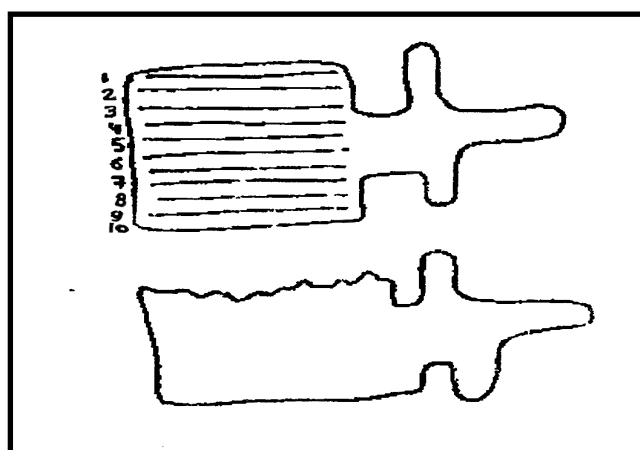


Figure 3 - Shows the method of assessment of loss of vertebral body. The body of the vertebra, as seen on a lateral radiograph, is divided into 10 parts for this assessment.

Table 4 - Change in the angle of kyphosis over a 3-year period.

Angle of kyphosis (thoracic and thoracolumbar)	n
At the start	10
No kyphosis	8
1-30	2
>30-60	2
>60	
After 3 years	10
No kyphosis	4
1-30	5
>30-60	3
>60	
n - number	

Table 5 - Change in total vertebral body loss in degrees over a 3 year period.

Degree of body loss	n
At the start	
No change <1	4
1	4
2	2
>3	12
At 3 years	
No change <1	2
1	1
2	4
>3	15
n - number	

incomplete paraplegia improved completely by the end of 9th month, and started walking by 18 months (CT scan showed that mild cord soft-tissue compression resolved by 18 months). Ten thoracic abscesses resolved at 12 months, 3 abscesses at 14 months and one at 18 months. Two psoas abscesses resolved at 12 months, whereas one was drained surgically after 15 days of treatment due to super-imposed infection – it became acutely hot and severely tender (**Table 3**). Four cases (18%) had deterioration of the angle of kyphosis – 3 from mild to moderate and one from mild to severe; all of them were in the thoracic region and above 30 years of age (**Table 4**). Five cases had progression of the body loss (22.5%); all of them were above 22 years of age – 3 of them were with initial loss of less than 0.5 and 2 without. All cases that had progress in the gibbus curve had an initial body loss of less than 0.5 (**Table 5**). Three patients (13%) received additional chemotherapy (INH + rifampicin) for 6 months for clinical and radiological evidence of incomplete healing process (2 vertebral bodies were affected). One patient with complete paraplegia did not respond well to the chemotherapy plus immobilization and bed rest. By the end of 2 months the clinical and radiological status deteriorated, for which she underwent surgery (debridement and bone graft with posterior fixation by harrington rods). Fourteen cases had 2 vertebrae involved. By 12 months, 3 cases (21%) had bony fusion of the affected vertebrae, by 18 months – 6 cases (42%) and by 36 months – 3 cases (21%); the other 2 cases had no complete fusion – one by the end of observation at 38 months and the other at 48 months.

Discussion. There are many different opinions for the best method of treatment of TB of the spine. Some recommend radical excision of the affected vertebral bodies and bridging of the resultant gap with autologous bone grafts plus anti-TB

chemotherapy (Hodgson and Stock,¹⁰ Hodgson et al¹¹). Others recommend chemotherapy alone or with plaster of paris (Konstam and Konstam in 1958¹² and Konstam and Blesovsky in 1962,⁷); or chemotherapy and debridement of tuberculous focus as reported from Bulawayo in Zimbabwe,¹³ or anterior fusion with or without posterior stabilization as reported by Chen et al¹⁴ from Taiwan; or short course regimen of chemotherapy alone as reported from Korea.¹⁵ Based on our available resources with our limited experience in the treatment of TB of the spine, we found that our recommended regimen of chemotherapy with streptomycin, INH and rifampicin plus 2-3 months bed rest at home and 12 months of spinal locally custom-made brace is effective enough to reduce the pain and protect the spine from further deterioration of the angle of kyphosis (18%), whereas in Masan and Pusan series with inpatient and outpatient treatment with usage of plaster of paris jacket deterioration of the angle was seen in 56%,¹ while radical excision in Hong Kong showed no increase in Kyphosis.¹ In our patients prevention of serious bone loss was seen in 22% of cases, while in Masan and Pusan series in 61% of cases, and in Hong Kong group with radical resection in 20% of cases, (18% with 0.25 degrees of bone loss and 2% with one or more degrees of bone loss), whereas in the debridement group bone loss was 34% of cases (27% with 0.25 degrees of bone loss and 7% with or more degrees of bone loss). Prevention of deterioration of the disease activity was 13% in our patients, 5% in Masan and Pusan series, 2% in the radical group, and zero in the debridement group in Hong Kong. Good condition for bony fusion at 36 months was provided in 12 (84%) of our patients, 73% showed complete fusion in Masan and Pusan group, 86% at 3 years in the radical group, and 69% in the debridement group in Hong Kong.

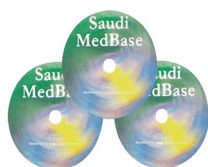In conclusion, our method of treatment is not costly both for the patient and the society. It needs no admission, no surgical intervention that demands skills and experience and special equipment. The brace itself is cheap, removable for easy hygiene purposes and massage. It is not heavy, induces no skin irritation and is tolerable in hot climates in comparison with the plaster of Paris jacket which is heavy and intolerable in countries with a hot climate, producing allergic and skin irritation reactions. The results of Masan and Pusan studies demonstrate no benefit from immobilization by plaster of paris for more than 9 months, for this reason we thought that there will be no benefit from prolonged immobilization by the brace for more than 12 months. This regimen can be recommended by any orthopedic surgeon for the treatment of uncomplicated thoracolumbar spinal TB.

References

1. 8th Report of the Medical Research Council Working Party on Tuberculosis of the Spine: 10 year assessment of a controlled trial comparing debridement and anterior spinal fusion in the management of tuberculosis of the spine in patients on standard chemotherapy in Hong Kong. *J Bone Joint Surg* 1982; 64: 393-398.
2. 9th Report of the Medical Research Council Working Party on Tuberculosis of the Spine. A 10 years assessment of controlled trials of inpatient and outpatient treatment of plaster of paris jackets for tuberculosis of the spine in children on standard chemotherapy. *J Bone Joint Surg* 1985; 67: 103-110.
3. Braunwald E. *Harrisons Principles of Internal Medicine*. 15th ed. USA: McGraw Hill International; 1998. p. 997-1014.
4. Bailey HL, Gabriel SM, Hongson NAR, Shen JS. Tuberculosis of the spine in children. *J Bone Joint Surg* 1972; 54: 1633-1657.
5. Duthie RB, Bentley G. *Mercer's Orthopedic Surgery*. 8th ed. London (UK): Mcgraw-Hill; 1983. p. 528-548.
6. 5th Report of the Medical Research Council Working Party on Tuberculosis of the Spine: A five-year assessment of controlled trials of inpatients and outpatient treatment and of plaster-of-paris jackets for tuberculosis of the spine in children on standard chemotherapy. *J Bone Joint Surg (Br)* 1976; 58: 399-411.
7. Konstam PG, Blesovsky A. The ambulant treatment of spinal tuberculosis. *Br J Surg* 1962; 50: 26-38.
8. Kaplan CJ. Pott's disease in South African Bantu children. An analysis of results and comparison with Lancashire figures. *British Journal of Tuberculosis* 1952; 46: 209-213.
9. Rajasekaran S, Shanmugasundaram TK. Prediction of the angle of gibbus deformity in tuberculosis of the spine. *J Bone Joint Surg* 1987; 69: 503-509.
10. Hodgson AR, Stock FE. Anterior spinal fusion. A preliminary communication on the radical treatment of Pott's disease and Pott's paraplegia. *Br J Surg* 1956; 44: 266-275.
11. Hodgson AR, Stock FE, Fang HSY, Ong GB. Anterior spinal fusions the operative approach and pathological findings in 412 patients with Pott's disease of the spine. *Br J Surg* 1960; 48: 172-178.
12. Konstam PG, Konstam ST. Spinal tuberculosis in Southern Nigeria with spinal references to ambulant treatment of thoracolumbar disease. *J Bone Joint Surg* 1958; 40: 26-32.
13. Leong JCY. Editorials. Tuberculosis of the spine. *J Bone Joint Surg (Br)* 1993; 75: 173-175.
14. Chen WJ, Chen CH, Shih CH. Surgical treatment of tuberculous spondylitis. *Acta Orthop Scand* 1995; 2: 137-142.
15. 12th report of the Medical Research Council Working Party on Tuberculosis of the Spine: controlled trial of short-course regimens of chemotherapy in the ambulatory treatment of spinal tuberculosis. *J Bone Joint Surg* 1993; 75: 240-280.

Related Abstract

Source: Saudi MedBase



Saudi MedBase CD-ROM contains all medical literature published in all medical journals in the Kingdom of Saudi Arabia. This is an electronic format with a massive database file containing useful medical facts that can be used for reference. Saudi Medbase is a prime selection of Abstracts that are useful in clinical practice and in writing papers for publication.

Search Word: spinal tuberculosis

Authors: Nigel J. Shanks, Ibrahim Khalifa, Darwisha Al-Kalai

Institute: Riyadh Military Hospital, Kingdom of Saudi Arabia and Welsh National School of Medicine, Cardiff, United Kingdom

Title: Saudi Topics

Source: Saudi Med J 1983 April, 2: 151-155

Abstract

A retrospective survey of 47 tuberculous Saudi Arabian patients attending the Riyadh Military Hospital was conducted: 53.2% were male and 46.8% female. Fourteen patients (29.8%) had a history of previously treated disease and only 34% were suspected of suffering from tuberculosis on clinical grounds. The most common means of diagnosis were by chest x-ray (38.3%) and histology (36.2%). Pulmonary disease accounted for 57.4% of all cases reviewed, lymphadenitis for 19.1% and bone and spinal tuberculosis for 10.6%. There was poor response to chemotherapy in 10.6% of cases and 6.4% suffered from adverse drug reactions.