

Case Report

# Diabetes mellitus and cystic fibrosis in 2 Saudi siblings

Hanaa H. Banjar, MD, FRCPC, Nadia A. Sakati, FACMG.

---

## ABSTRACT

Diabetes mellitus and cystic fibrosis (CF) have been reported before in the literature, but they have never been reported in the same patient in the Middle East. We present the first reported case of insulin dependent diabetes mellitus (IDDM) and CF in 2 siblings of the same family. Both siblings were diagnosed early in life with IDDM, and their diabetes was well controlled on insulin. Cystic fibrosis was diagnosed in the first case one year after IDDM was diagnosed due to history of chronic cough and in the 2nd case by family screening. Both had severe failure to thrive, recurrent chest infections and gastro-esophageal reflux. With treatment both showed clinical improvement, but continued to have moderate lung disease radiologically and by pulmonary function test.

Saudi Med J 2002; Vol. 23 (12): 1541-1545

---

**D**iabetes mellitus (DM) in cystic fibrosis (CF) is predominantly a disease of adolescents and young adults, although onset as early as 2 years and 4 years<sup>1</sup> has been reported. The mean age of patients at the time of diagnosis is remarkably consistent in several studies, namely, 18-20 years.<sup>1-4</sup> There is no significant difference in age of onset between the sexes, although diabetes as a complication of CF appears to be more prevalent among females. The prevalence of overt DM in CF patients has been reported as between 2.5% and 12%.<sup>1-3</sup> It increases with advancing age<sup>4</sup> and it has been predicted that DM will affect 15% of adult CF patients<sup>4</sup> (**Table 1**). The prevalence of DM in CF (CF/DM) is at least 40-200 fold higher than that of DM in the child and young adult population, which vary between 0.06% and 0.3% of people in the United States of America (USA) below the age of 30 years.<sup>4</sup> The prevalence of glucose intolerance, which according to some estimates affects 26-75% of CF patients<sup>1-4</sup> with documented increase in glucose intolerance of 5% per year of young CF adults.<sup>3</sup>

Cystic fibrosis has been reported before in the Kingdom of Saudi Arabia (KSA).<sup>5</sup> The incidence of

CF has been estimated to be 1:4243 live births.<sup>6</sup> The prevalence of insulin dependent diabetes mellitus (IDDM) in KSA was estimated to be in the range of 2.5% in males and 5.3% in females.<sup>7</sup> Both IDDM and CF have never been reported before in KSA or the Gulf area. In this report, we present the first case report of 2 siblings from the same family with both IDDM and CF.

**Case Report.** *Patient One (Table 2).* This female patient presented at 13 years of age with a history of repeated chest infections from the age of 2 months, requiring admissions 2-4 times per year. She was diagnosed with IDDM at 12 years of age and has been on insulin treatment since then. On physical examination, she looked in mild respiratory distress, with respiratory rate (RR) of 50/minute. Oxygen saturation in room air of 77%. She had severe clubbing of fingers and toes. Weight (Wt.) of 20.4 kg, 5% for age. Height (Ht.) 120 cm, 5% for age. Chest examination showed pigeon chest with bilateral diffuse crepitation and rhonchi. The rest of the physical examination was normal. Eye fundal

---

From the Department of Pediatrics, King Faisal Specialist Hospital and Research Center, Riyadh, Kingdom of Saudi Arabia.

Received 29th May 2002. Accepted for publication in final form 14th August 2002.

Address correspondence and reprint request to: Dr. Hanaa H. Banjar, Consultant Pediatric Pulmonologist, Department of Pediatrics, MBC-58, King Faisal Specialist Hospital and Research Center, PO Box 3354, Riyadh 11211, Kingdom of Saudi Arabia. Tel. +966 (1) 4427761. Fax. +966 (1) 4427784. E-mail: hanaa@kfsfsrc.edu.sa

**Table 1**

Characteristics	IDDM	Non-IDDM	CFRDM
Age of onset	Child	Adult	Juvenile-adult
Insulin secretion	Low	Normal/ high	Low
Glucagon secretion	High	High	Normal/ low
Islet cell antibodies	Strong +ve	Not associated	+/-
Insulin requirement	Strong +ve	Not associated	+ve association
Ketosis	Strong +ve	Not associated	Not associated
HLA association	DR3/DR4	Not associated	Not associated
n of insulin receptors	Increased	Decreased	Increased

+ve - positive association, +/- = variable association,  
 HLA - human leukocyte antigen, n - number,  
 IDDM -insulin dependent diabetes mellitus,  
 Non-IDDM - non insulin dependent diabetes mellitus,  
 CFRDM - cystic fibrosis related diabetes mellitus.

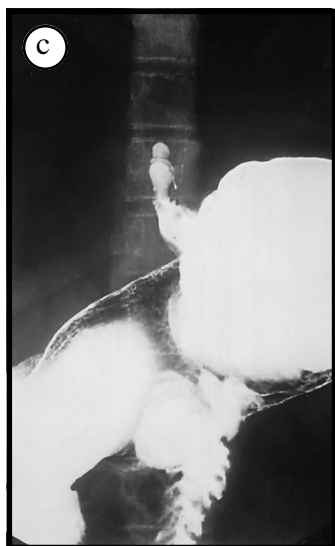
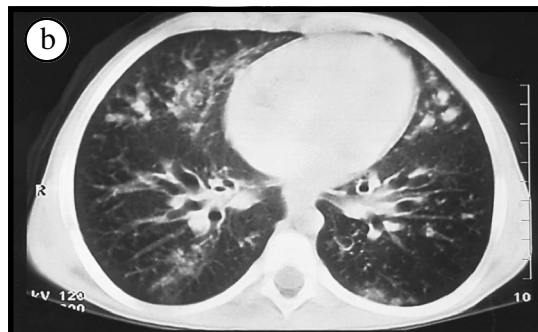
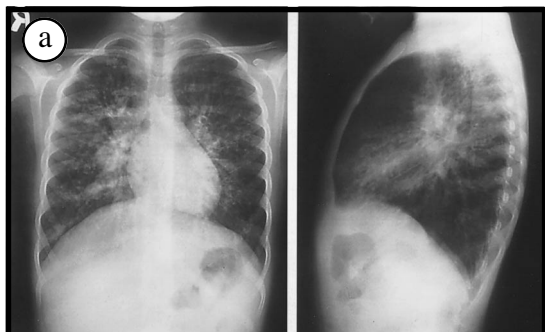
**Table 1** - Comparison of insulin dependent diabetes mellitus, non insulin dependent diabetes mellitus, and cystic fibrosis related diabetes mellitus.

**Table 2** - Comparisons of characteristics of both siblings with IDDM and CF.

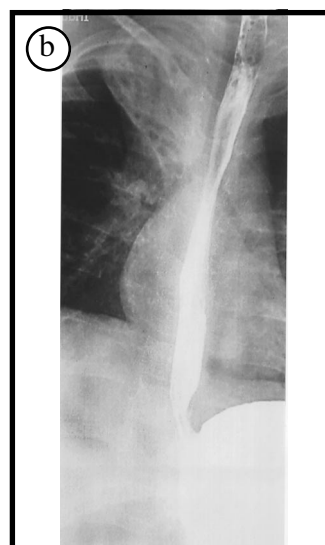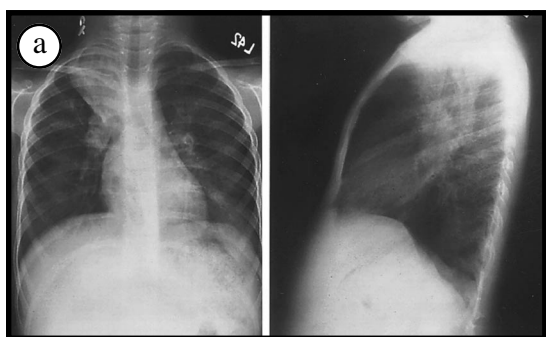
**Table 2**

Characteristic	Patient One	Patient 2
Age at diagnosis	13 years	5.5 years
Diagnosis of IDDM	12 years	2 years
Type of diagnosis	History/Sweat test	Family screening
HbA1C	0.0119 (H)	0.172 (H)
Sweat test	68, 72 mmol/L	83, 90 mmol/L
C-xray	Bronchiectasis RUL, LUL, RML, hyperinflation, hilar lymph nodes enlarged	Bronchiectasis RUL, LUL, RML, hyperinflation, peribronchial wall thickness
GER	Mild	Severe
IgG/IgE	22.9 (H)/57 (N)	19.9 (H)/51 (N)
25 OH vit. D	22 (N)	18 (N)
Home O <sub>2</sub>	Yes	No
Islet Cell Abs	< 1:10	< 1:10
Insulin Human Abs	90 (H)	22 (H)
HLA Typing	A28, A32; B8 (BW6), B41 (BW6); CW7 DRB1*0301 DRB3*0202 DQB1 0201 DRB1*0301 DRB1 0405 DRB4*01 DQB1 0302 / 0308	A28, A32; B8 (BW6), B41 (BW6); CW7 DRB1*0301 DRB3 0202 DQB1 0201 DRB1*0301 DRB1 0405 DRB4*01 DQB1 0302/0308
Anti TPO AB	<10 (N)	26 (N)
TSH	1.8 (N)	2.2 (N)
Anti gliadin Abs IgA	5 (H)	2 (N)
Anti gliadin IgG	18 (N)	7 (N)
Anti-reticulin antibodies	-ve	-ve
Endomysium Abs - IgA	Weak +ve	Weak +ve
ANA screen 1:40 dilution	+ve	+ve
ANA equalization speckled 1:80	+ve	+ve
DNA analysis	Homozygous (I1234V)	Homozygous (I1234V)
Immunity for hepatitis A and B	Not immune	Not immune

\*HLA typing was carried out by molecular technique not by serological technique. IDDM - insulin dependent diabetes mellitus, HbA1C - hemoglobin A1C, C-xray - chest x-ray, GER - gastro-esophageal reflux, IgG/IgE - immunoglobulin G/E, 25 OH vit D - 25 hydroxy vitamin D, O<sub>2</sub> - oxygen, Abs - antibodies, HLA - human leukocyte antigen, TPO AB - thyroid peroxidase antibody, TSH - thyroid stimulating hormone, ANA - antinuclear antibodies, DNA - deoxyribonucleic acid, RUL - right upper lobe, LUL - left upper lobe, RML - right middle lobe, -ve = negative, +ve = positive, (H) - high, (N) - normal



**Figure 1** - Clinical images of patient one **a)** Chest x-ray showing peribronchial wall thickening, cylindrical bronchiectasis involving right middle lobe, right upper lobe, lingual, and left upper lobe and hyperinflation of both lungs and diffuse nodular pattern due to mucous plugs. **b)** Computerized tomography scan showing peribronchial wall thickening, cylindrical bronchiectasis involving the same lobes as in Figure 1a and hilar lymphadenopathy. **c)** Barium swallow showing mild gastro-esophageal reflux.



**Figure 2** - Clinical images of patient 2 **a)** Chest x-ray showing peribronchial infiltrate in the central parts of both lungs, peribronchial wall thickening, collapsed right upper lobe and generalized tubular bronchial dilatation involving right upper lobe, left upper lobe and right middle lobe. **b)** Barium swallow showing severe gastro-esophageal reflux up to the thoracic inlet.

examination was normal. The family history was positive for a 5-year-old brother with CF, and an aunt with IDDM. There are 3 sisters and 5 brothers who are healthy and well. The family refused genetic screening for CF for all family members.

Investigations revealed: Sweat chloride test was high on 2 occasions by the quantitative method (Wescor, USA) 68, and 72 mmol/L (normal, <40 mmol/L) and the diagnosis was confirmed for CF. Total blood count and differential was normal. Renal and hepatic profile were normal. Immunoglobulin G level (IgG) was elevated at 22.9 (normal 6.9-16.2 g/L). Hemoglobin A1C (HbA1C) was elevated at 0.127 (normal 0.048-0.078 Frc). Sputum for acid-fast bacilli (AFB) stain and culture was negative. Chest x-ray (C-xray) and computerized tomography scan (CT) showed peribronchial wall thickening, cylindrical bronchiectasis involving right middle lobe (RML), right upper lobe (RUL), lingual, and left upper lobe (LUL). Hilar lymphadenopathy, hyperinflation of both lungs and diffuse nodular pattern due to mucous plugs (**Figure 1a & 1b**). Barium swallow showed mild gastro-esophageal reflux (**Figure 1c**). Ultrasound (US) of abdomen was normal. Arterial blood gas showed Ph 7.4, PCO<sub>2</sub> 5.6 kpa, PaO<sub>2</sub> 5.8 kpa, bicarbonate (HCO<sub>3</sub>) 26 mmol/L, and base excess 1.9 mmol/L. Vitamin D and E levels were normal. Islet cell antibodies <1:10, within normal limits. Insulin human antibodies were elevated 90u/ml (normal <1.0). Human leukocyte antibodies (HLA) were positive for DR3, and DR4. Antibodies thyroid peroxidase level (TPO) was negative, thyroid stimulating hormone (TSH) was normal (**Table 2**). Anti gliadin antibodies (IGA) were high at 5 (normal 0-3 mg/L), but IgG was normal at 18 (0-18 mg/L). Anti-retuculin antibodies were negative. Antinuclear antibodies (ANA) screen was positive at 1:40 dilution. Antinuclear antibodies quantitation, speckled 1:80. Hepatitis screen showed no immunity for hepatitis A and B. Pulmonary function test (PFT) showed severe combined obstructive and restrictive lung disease with severe air trapping (**Table 2**). Cystic fibrosis transmembrane regulator gene mutational screening (CFTR) showed (I1234V) mutation in a homozygous state.<sup>5</sup>

The patient was admitted and given oxygen (O<sub>2</sub>) supplement and intravenous antibiotics (I.V.) for 10 days, after which she showed marked improvement. She was sent on home O<sub>2</sub> as needed and humulin insulin to be monitored in a local hospital as they lived 600 km from our hospital. Oral Ciprofloxacin 250 mg, 2-times/day. Inhaled Gentamycin, 80 mg 3-times/day. Inhaled Salbutamol and steroid 3-times/day. On follow-up 6 weeks later, she showed marked clinical improvement and had gained 2kg in Wt. She was immunized for hepatitis A and B.

**Patient 2.** A 5-year-old male, brother of patient one, was diagnosed with CF based on high sweat

chloride test of 83 and 90 mmol/L through family screening. He had a history of cough, failure to thrive and loose stool from birth. He was diagnosed with IDDM at 2 years of age and had been on regular insulin to control his diabetes in a local hospital. On physical examination, he was in no respiratory distress. Height 108 cm, 25% for age. Weight 14 kg, <5% for age. Chest examination showed bilateral rhonchi and crepitation. The rest of the physical examination was normal. Eye fundal examination was normal.

Investigations revealed (**Table 2**): Glucose level was elevated at 17.8 mmol/L (normal 3-8 mmol/L). Normal chloride 98, hyponatremia 129 mmol/L (normal 135-147), normal calcium, phosphate and magnesium levels. Elevated alkaline phosphatase 363 (normal 100-240 u/L), alanine aminotransferase was elevated at 47 (normal 10-45 u/L), and normal aspartate transaminase. Hepatitis screen showed no immunity to both A and B. Normal total blood count level and differential. A picture of hypochromic microcytic anemia: Hemoglobin (Hb) low at 106, Hematocrit (Hct) 0.32 (normal 0.38-0.5 Rati), mean corpuscular volume was low at 61 (normal 80-94 fl), mean corpuscular hemoglobin 20 (normal 27-32 pg), elevated platelet 531 (normal 140-350x 10<sup>9</sup>/L), 25-hydroxy-vit-D 18.9 (normal 22-16 nmol/L). Hemoglobin electrophoresis showed a picture of beta thalassemia minor: Low A1 93.4% (normal 96-98%), F RID 1.1% (normal 0.0-1.0%), A2 column 5.5% (normal 2.2-3.7%). Arterial blood gas was normal. Immunoglobulin E level was normal. Immunoglobulin G level was elevated at 19.9 g/l. Hemoglobin A1C was elevated at 0.172 Frc. Normal anti TPO antibodies and TSH, anti gliadin antibodies IgA and IgG. Antinuclear antibody screen was positive in 1:40 dilution and ANA quantitation was 1:80. Deoxyribonucleic acid quantitation was normal. Islet cell antibodies were normal, but elevated human insulin antibodies at 22 u/ml. Human leukocyte antigen typing was positive for DR3 and DR4. Respiratory culture grew mucoid *Pseudomonas aeruginosa* and *Hemophilus influenza* resistant to Ampicillin and *Streptococcus pneumonia*. Chest x-ray showed peribronchial infiltrate in the central parts of both lungs, peribronchial wall thickening, collapse RUL and generalized tubular bronchial dilatation involving RUL, LUL and RML (**Figure 2a**). Barium swallow showed severe gastro-esophageal reflux up to the thoracic inlet (**Figure 2b**). Pulmonary function test showed a picture of moderate obstructive lung disease. Cystic fibrosis transmembrane regulator gene mutational screening showed the same mutation as the sister (I1234V) in a homozygous pattern.<sup>5</sup> The patient was admitted to hospital and was treated with I.V. antibiotics (Gentamycin and Ceftazidime) for 10 days. Blood glucose was controlled with insulin. The patient showed marked clinical improvement and

was sent home on Ciprofloxacin orally and Gentamycin inhalation 80 mg 2-times/day for 6 weeks with inhaled Salbutamol and inhaled steroid 2-times/day. On follow-up 6 weeks later, the patient showed good weight gain and clear chest.

**Discussion.** Due to better knowledge and recognition of IDDM as a common disease in KSA, both patients were diagnosed initially with IDDM at an early age. Cystic fibrosis was diagnosed later, despite early CF symptoms at a few months of age. Unfortunately, by the time both patients were diagnosed with CF they had already developed bilateral bronchiectasis, due to the lack of awareness of this disease in this part of the world.

It has been concluded that diabetes in itself does not appear to alter the course of CF, and that microangiopathic complications are rare because most CF/DM patients do not survive long enough for them to develop.<sup>8,9</sup> However, CF/DM patients have the same life expectancy as non-diabetic CF patients until the age of 20 years, after which survival of the CF/DM patients declines rapidly with fewer than 25% reaching 30 years compared with 60% of non-diabetic CF patients.<sup>8</sup> As the symptoms may be mild, it is important to screen CF patients regularly for the onset of diabetes, at intervals of not greater than one year in the younger age group and more frequently in adults. Sullivan et al<sup>9</sup> recommended screening by HbA1C estimation, 2-hour postprandial serum glucose concentrations and urinalysis.

Islet cell antibodies (ICA) were found in about 0.5% of control populations, but were present in 15% of a series of 46 CF patients rising to 25% with glucose intolerance. The presence of ICA in some patients with CF appears to be a manifestation of an immune response.<sup>4</sup> Both of our patients were negative for ICA.

Poorer lung function has been found in CF diabetics<sup>3,4</sup> and decreases in forced expiratory volume in the first second (FEV1) and forced vital capacity (FVC) have been reported to coincide with decreasing glucose tolerance.<sup>10</sup> A weak inverse relationship has been noted between HbA1c values and pulmonary function in CF/DM patients.<sup>4</sup> This is consistent with the observations of Reisman, who followed 2 groups of CF patients, with and without

DM and found no significant difference in FEV1 diagnosis values attained by each group 5 years prior to diagnosis, at the time of diagnosis and 5 years post-diagnosis.<sup>8</sup>

Both of our patients had moderate to severe obstructive lung disease that persisted even with clinical improvement, this finding confirms permanent lung damage. Both were negative for microangiopathy even after 2 years follow-up, both had severe lung disease, mucoid *Pseudomonas aeruginosa* colonization and failure to thrive. All factors contribute to their poor prognosis and possibly progressive disease, which may affect their long-term survival.<sup>8,9</sup>

In conclusion, CF is increasingly recognized in KSA. Patients with CF should be screened for DM, as it is a common disease in KSA, especially in patients with a positive family history of DM.

## References

1. Yung B, Hodson ME. Diabetes in cystic fibrosis. *J R Soc Med* 1999; 92 Suppl 37; 35-40.
2. Moran A, Hardin D, Rodman D, Allen HF, Beal RJ, Borowitz D et al. Diagnosis, screening and management of CFRD: a consensus conference report. *Diabetes Res Clin Pract* 2000; 49: 199-200.
3. Hardin DS, Moran A. Diabetes mellitus in cystic fibrosis. *Endocrinol Metabol Clin North Am* 1999; 28: 787-800.
4. Dodge JA, Morrison G. Diabetes mellitus in cystic fibrosis: a review. *J R Soc Med* 1992; 85 Suppl 19: 25-28.
5. Kambouris M, Banjar H, Mogarri I, Nazer H, Al-Hamed M, Meyer BF. Identification of Novel Cystic Fibrosis Mutations in Arabs with CF: Their impact on the CFTR mutation detection rate in Arab population. *Eur J Pediatr* 2000; 159: 303-309.
6. Nazer H, Riff E, Sakati N, Mathew R, Majeed MA, Harfi H. Cystic fibrosis in Saudi Arabia. *Eur J Pediatr* 1989; 148: 330-332.
7. Karim A, Ogbeide DO, Siddiqui S, Al-Khalifa IM. Prevalence of diabetes mellitus in a Saudi community. *Saudi Med J* 2000; 21: 438-442.
8. Reisman J, Corey M, Canny G, Levison H. Diabetes mellitus in patients with cystic fibrosis: effect on survival. *Pediatrics* 1990; 86: 374-377.
9. Sullivan MM, Denning CR. Diabetic microangiopathy in patients with cystic fibrosis. *Pediatrics* 1989; 84: 642-646.
10. Primhak RA, Whincup G, Tsanakas JN, Milner RD. Reduced vital capacity in insulin dependent diabetes. *Diabetes* 1987; 36: 324-326.