

# Variations in the subclavian-axillary arterial system

Muhammad Saeed, MBBS, MPhil, Amin A. Rufai, MBBS, PhD, Salah E. Elsayed, FRCS, PhD,  
Muhammad S. Sadiq, MBBS, MPhil.

---

## ABSTRACT

**Objective:** The objective of this study is to report on the subclavian axillary arterial system variations observed in the dissecting room.

**Methods:** The morphological study of 106 formalin fixed upper limbs of adult human cadavers of both sexes was carried out at human anatomy laboratory of College of Medicine, King Saud University, Riyadh, Kingdom of Saudi Arabia over a 5 year period, to observe the distribution pattern of the subclavian axillary arterial system.

**Results:** The arterial variations in the upper extremities are quite common and may occur at the level of the thoracic outlet, axilla, arm, cubital fossa and the hand. In the present study, the anomalous topographic pattern of the subclavian axillary arterial system was revealed in 7.5% of the cadavers, whereas 92.5% exhibited classical pattern of the regional arterial anatomy. The study showed: 1. An aberrant right subclavian artery arising from the arch of aorta, distal to the left subclavian artery. 2. A bilateral common subscapular-circumflex humeral

trunk (3.8%) emerging from the 3rd part of the axillary artery (branching into the circumflex humeral and thoracodorsal arteries. 3. A bilateral thoracohumeral trunk arising from the 2nd part of the axillary artery (1.9%) and branching into the lateral thoracic, circumflex humeral, subscapular and thoracodorsal arteries. These anomalies were accompanied by anomalous insertion of flexor digitorum superficialis muscle, a bilateral digastric muscle formed by the abductor pollicis longus and brevis, and an anomalous formation of median nerve by 3 roots.

**Conclusion:** The aberrant right subclavian artery associated with right non-recurrent laryngeal nerve and variant branching pattern of the axillary artery are of interest to anatomists, surgeons and radiologists and suggested that these anomalies must be evaluated pre-operatively.

**Keywords:** Subscapular artery, median nerve, upper limb, circumflex humeral arteries.

Saudi Med J 2002; Vol. 23 (2): 206-212

---

Variations in the arterial anatomy of the upper extremities are quite common.<sup>1-4</sup> An incidence of 20% has been reported in major arteries.<sup>5-6</sup> Primary anomalies of the subclavian artery are more frequent than those of the axillary artery.<sup>7-8</sup> There may be agenesis of the axillary artery, duplication or variations in its branching pattern.<sup>3,9-14</sup> The 3rd part of the axillary artery is more prone to anomalous branching, namely, superficial brachial artery,<sup>9,15</sup> profunda brachii artery and superior ulnar collateral artery.<sup>16</sup> Earlier work in our department has reported the novelistic bilateral superficial ulnar artery in the Kingdom of Saudi Arabia.<sup>17</sup> There after, other

investigators reported variations of the superficial ulnar artery in Turkey<sup>18</sup> and Japan.<sup>19</sup> The course and branching pattern of the axillary artery vary with race and sex.<sup>10,12,20</sup> Secondary occlusion or stenosis of the subclavian or axillary artery is a relatively uncommon manifestation of peripheral vascular disease. It may be the result of post-radiation injury, thoracic outlet syndrome, and compression by the anomalous course of nerves and muscles or following blunt trauma.<sup>21-23</sup> Regardless of the cause, it results in a variety of problems including arm impairment, subclavian steal, ischemic fingers due to embolization or even gangrene of the affected limb.<sup>21</sup>

---

From the Department of Anatomy, College of Medicine & King Khalid University Hospital, King Saud University, Riyadh, Kingdom of Saudi Arabia.

Received 16th July 2001. Accepted for publication in final form 29th September 2001.

Address correspondence and reprint request to: Dr. Muhammad Saeed, Department of Anatomy, College of Medicine & KCUH, King Saud University, PO Box 2925, Riyadh 11461, Kingdom of Saudi Arabia. Tel. +966 (1) 4825922/4672545. Fax. +966 (1) 4671300. E-mail: shafi@ksu.edu.sa/ msaeedshafi@hotmail.com

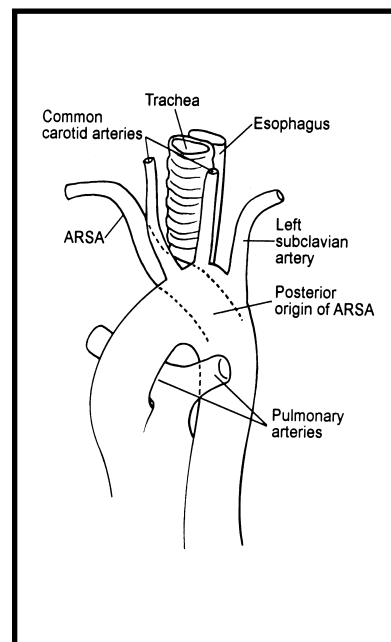
Compression of the axillary artery and its circumflex branches by the humeral head is a surprisingly common pathological mechanism, producing neurovascular symptoms in thoracic outlet syndrome.<sup>24</sup> Classically the right and left subclavian arteries arise from the brachiocephalic trunk and arch of aorta. Irrespective of the origin, each subclavian artery has 3 parts (medial, posterior and lateral), by its relation to the scalenus anterior muscle. Though the first (medial) part of right and left subclavian arteries differ, the 2nd (posterior) and 3rd (lateral) parts follow identical courses. At the outer border of the first rib, the subclavian artery becomes the axillary, which terminates as brachial at the inferior border of the teres major muscle.<sup>25</sup> Like subclavian, the passage of the axillary artery behind the pectoralis minor provides a convenient basis for dividing it into 3 parts. The first (proximal) part of the axillary artery is enclosed with the axillary vein and brachial plexus in a fibrous axillary sheath, continuous with the prevertebral layer of the deep cervical fascia.<sup>26</sup> The superior thoracic artery arises from the proximal part, the thoraco-acromial and lateral thoracic arteries from the 2nd part (posterior) and the subscapular, anterior and posterior circumflex humeral arteries usually originate from the 3rd (distal) part of the axillary artery.<sup>27</sup> The subscapular artery, the largest and the most variable branch of the axillary artery, arises at the distal border of the subscapularis muscle.<sup>8</sup> It descends on the subscapularis and soon divides into the circumflex scapular and thoracodorsal branches. The thoracodorsal artery follows the subscapularis to the inferior angle of the scapula, where it anastomoses with the branches of the subclavian and axillary arteries and those of the thoracic aorta.<sup>28</sup> Thus the scapular anastomosis is an important collateral channel for arterial circulation in patients, having coarctation of aorta, thoracic outlet syndrome and post-radiation occlusion of the axillary or subclavian arteries. The subscapular artery is the main supply to the serratus anterior and subscapularis muscles. The serratus anterior muscle free flap is very popular among the plastic surgeons for lower limb reconstruction, as this provides a moderate quantity of muscle, with a long vascular pedicle.<sup>29</sup> Variant vascular supply to the serratus anterior free flap may come from thoraco-acromial axis, directly from the subscapular and axillary arteries. Hence it is imperative to evaluate the regional arterial anatomy pre-operatively by duplex ultrasonography and contrast arteriography with positional maneuvers. Accurate knowledge to normal and variant arterial anatomy of the axillary region is important for vascular radiologists, anatomists and surgeons (cardiovascular, general, plastic and orthopedic). Therefore, for correct diagnosis of underlying pathology and the clinical procedures employed for its remedy, the vascular variations of the region

should be well known. The present study was carried out to evaluate the frequency of arterial aberrations of the subclavian-axillary arterial system in dissecting room cadavers.

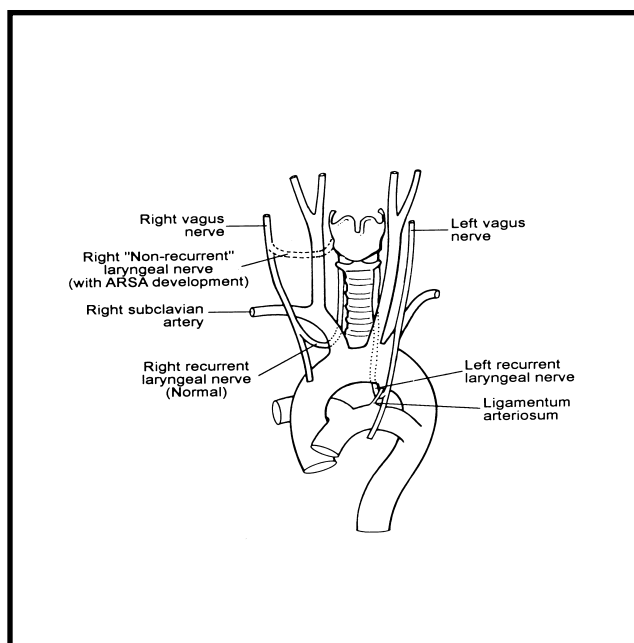
**Methods.** One hundred and 6 randomly selected formaline fixed upper limbs (of adult human cadavers of both sexes), assigned to medical students for dissection over a 5-year period, were studied at human laboratory of College of Medicine, King Saud University, Riyadh, Kingdom of Saudi Arabia. The topographic detail of arteries was examined by dissection and anomalies were recorded and described. The samples were selected carefully to include those cadavers only, where arteries were fairly well injected. The sketches were completed before the students disturbed the topographical relationships. Sliding vernier calipers were used for the measurements of the arteries.

**Results.** Out of 106 upper limbs, anomalous branching pattern of the subclavian-axillary arterial system, were found in 4 cases.

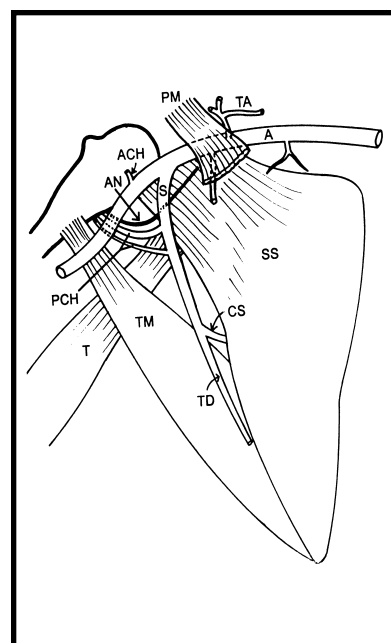
**An aberrant right subclavian artery.** An aberrant right subclavian artery was found in one white male cadaver aged 60 years. It emanated directly from the arch of aorta distal to the origin of the left subclavian artery and followed a retro-esophageal course (between vertebral column and the esophagus) in the posterior mediastinum (**Figure 1**). The right common carotid artery was the first branch of the arch of aorta, followed successively by the left



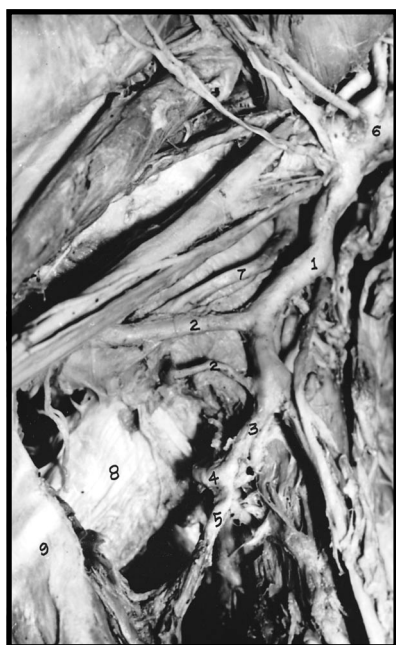
**Figure 1** - Schematic representation of an aberrant right subclavian artery (ARSA).



**Figure 2** - Schematic representation of the anatomy of the vagus and recurrent laryngeal nerves. Normally, the right recurrent laryngeal nerve is carried under the right subclavian artery. With the development of an aberrant right subclavian artery the right recurrent laryngeal nerve takes a direct course to the larynx due to the involution of the proximal part of the right 4th vascular arch.



**Figure 4** - Schematic representation of a common subscapular-circumflex humeral trunk emanating from 3rd part of the axillary artery. A-axillary artery; S-Common subscapular-circumflex humeral trunk; CS-circumflex scapular artery; TD-thoraco dorsal artery; PCH-posterior circumflex humeral arteries; ACH-anterior circumflex humeral artery; TA-thoracoacromial artery; T-long head of triceps brachii; TM-teres major; SS-subscapularis muscle; PM-pectoralis minor muscle.



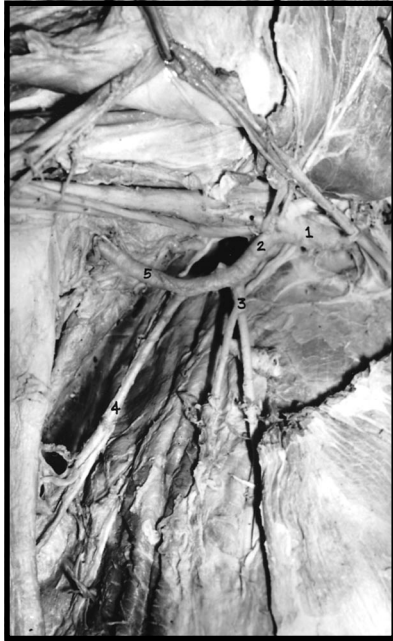**Figure 3** - Photograph showing a common subscapular-circumflex humeral trunk, emanating from the 3rd of the axillary artery. (1) Common subscapular-circumflex humeral trunk; (2) posterior circumflex humeral arteries; (3) subscapular artery; (4) circumflex scapular artery; (5) thoracodorsal artery; (6) axillary artery; (7) axillary nerve; (8) long head of triceps muscles; and (9) teres major muscle.

common carotid, the left subclavian and the right subclavian arteries (**Figure 1**). The right recurrent laryngeal nerve was non-recurrent and leaving the vagus nerve at a level higher than usual (**Figure 2**).

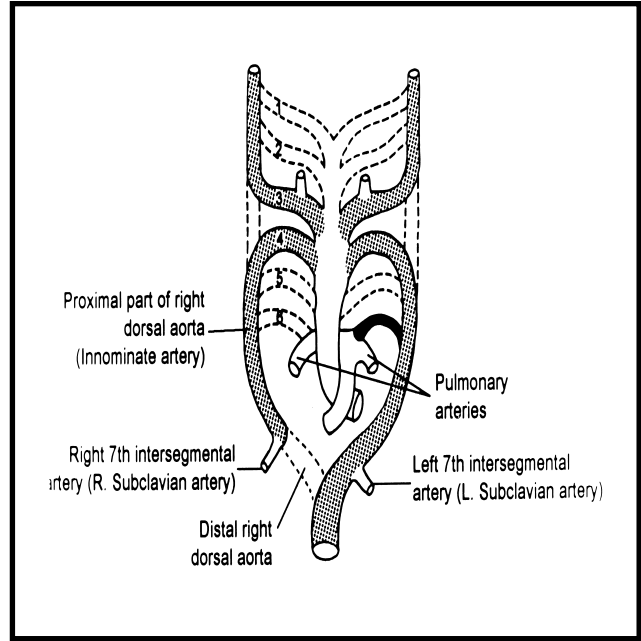
**Common subscapular-circumflex humeral trunk.**

Two black, male cadavers (60 and 65 years) showed anomalous branching pattern exclusively in the 3rd part of both axillary arteries, whereas the first and 2nd parts of the axillary artery followed all norms bilaterally. The subscapular and the circumflex humeral branches of the axillary artery were sharing a common stem of origin from the axillary artery (**Figures 3 & 4**). Two cm distal to its origin, it gave 2 posterior circumflex humeral branches and the parent trunk continued as thoracodorsal branch of subscapular artery towards the inferior angle of the scapula. The 2 posterior circumflex humeral arteries were unequal in size and followed the axillary nerve; to reach the surgical neck of the humerus, by passing through the quadrangular space (bounded by the long head of triceps, surgical neck of the humerus, teres major and subscapularis muscles). The anterior circumflex humeral artery was very small, having 3mm external diameter and coming directly from the 3rd part of the axillary artery (**Figure 4**).

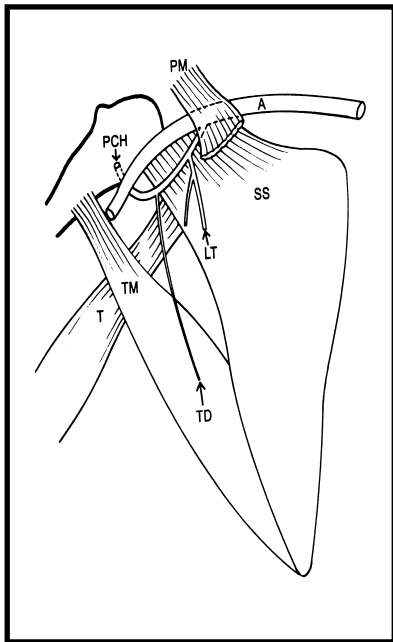
**Common thoraco-humeral trunk.** One white female cadaver (45 years old) showed an anomalous common thoraco-humeral trunk that arose bilaterally



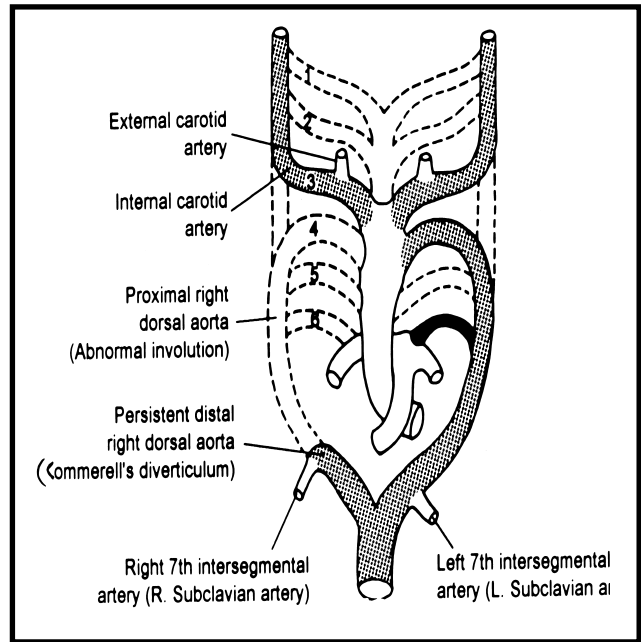
**Figure 5** - Photograph showing common thoraco-humeral trunk emanating from the 2nd part of the axillary artery. (1) Axillary artery; (2) common thoraco-humeral trunk; (3) lateral thoracic artery; (4) thoraco dorsal artery; (5) posterior circumflex humeral artery.



**Figure 7** - Schematic representation of normal embryological development of the great vessels. Numbers identify the aortic arch components and dotted lines represent the vessel involution. Note the persistence of the proximal right dorsal aorta, with involution of its distal segment.



**Figure 6** - Schematic representation of a common thoraco-humeral trunk emanating from the 2nd part of the axillary artery. A-axillary artery; LT-lateral thoracic artery; TD-thoraco dorsal artery; PCH-posterior circumflex humeral artery; T-long head of triceps brachii; TM-teres major; SS-subscapularis muscle; PM-pectoralis minor muscle.



**Figure 8** - Schematic representation of abnormal embryological development of the great vessels leading to the development of an aberrant right subclavian artery. Note the persistence of the distal part of the right aorta and the 7th intersegmental artery forming an (ARSA).

from the 2nd part of the axillary artery (deep to the tendon of pectoralis minor), which crossed the medial cord of brachial plexus, branched into lateral thoracic, subscapular and posterior circumflex humeral arteries (**Figures 5 & 6**). It gave the lateral thoracic branch 1.5cm distal to its origin and then followed an arched course in the deep region of axilla, with convexity directed infero-laterally. Surprisingly, the posterior circumflex humeral artery was its largest terminal branch, with an external diameter of 9mm (**Figure 5**). The subscapular artery was smallest branch with an external diameter of 4mm only. This case showed no anterior circumflex humeral artery.

**Associated anomalies of upper extremities.** The anomaly, common subscapular-circumflex humeral trunk was associated with unilateral anomalous insertion of right flexor digitorum superficialis tendon, with maximum contribution to the index finger. Moreover the abductor pollicis longus and brevis formed a digastric muscle bilaterally. No variation in the palmar arterial arches occurred concurrently with the axillary aberrations, but anomalous formation of median nerve by 3 routes co-existed with anomaly common subscapular-circumflex humeral trunk. One (medial) root emanated from the medial cord and 2 lateral roots arose from the lateral cord of the brachial plexus. The anomaly, common thoraco-humeral trunk was accompanied by anomalous insertion of abductor pollicis longus, which was forming a digastric muscle with abductor pollicis brevis.

**Discussion.** The complex embryological development of the vascular system often results in a myriad of clinically relevant anomalies. Variations in the origin, course and distribution of the principal arteries of the upper limbs have received the keen attention of anatomists, vascular radiologists and cardiovascular surgeons.<sup>7</sup> An aberrant right subclavian artery (ARSA), the most common congenital anomaly of the aortic arch, rarely produces symptoms.<sup>30-31</sup> Dysphagia lusoria is the most common symptom, presenting in 37.5% of symptomatic patients.<sup>32</sup> Surgical correction of symptomatic ARSA is essential. Division of the ARSA at its origin from the aorta and restoration of flow by end to side subclavian to carotid anastomosis is the most popular procedure used to avoid subclavian steal and eliminate the need for a prosthetic graft.<sup>33</sup> The subclavian arteries are the embryological product of 7th intersegmental arteries (**Figure 7**). During normal embryogenesis, the distal segment of right dorsal aorta involutes, allowing the 4th vascular arch and 7th intersegmental artery on the right side to become the brachiocephalic and the subclavian arteries.<sup>34</sup> However, in 0.5% of

population, the right 4th vascular arch and proximal right dorsal aorta involute, leaving the right 7th intersegmental artery attached to the left descending aorta via the distal part of right dorsal aorta, forming Kommerell's diverticulum<sup>35-36</sup> (**Figure 8**). As the right 6th vascular arch involutes, the right recurrent laryngeal nerve is carried under the 4th arch (**Figure 2**). With the development of an ARSA, the 4th vascular arch no longer catches the right, now non-recurrent laryngeal nerve. Hence it takes a direct course to the larynx<sup>37</sup> (**Figure 2**) and therefore it raises concern during any surgery on the right side of the neck. Developmentally, the lateral branch of 7th intersegmental artery enlarges to form the main artery (axis artery) of the developing upper limb bud (**Figure 7**). The proximal part of this axial artery is recognized as axillary artery, followed by the brachial and interosseus arteries. Other arteries of the upper extremities develop as sprouts.<sup>34</sup> Due to their multiple and plexiform sources, the temporal succession of emergence of the principal arteries, anastomoses and periarticular networks, the anomalies of subclavian-axillary arterial system are fairly common.<sup>37</sup> Anomalies in their morphogenesis may result from persistence of channels that normally obliterate (**Figure 8**) or from a choice of unusual paths in the primitive vascular plexuses.<sup>38-39</sup> Although the subscapular artery (Sbs) is considered to represent a common trunk of the circumflex scapular (CS) and thoracodorsal (TD) arteries, these arteries do not always arise from the Sbs artery. The posterior circumflex humeral artery (PCH) is often associated with CS or CS+TD common trunk. Moreover the subscapularis branch (SSb) frequently arises from CS or CS+TD common trunk. Therefore the studies on subscapular artery must include SSb and PCH. However, many anatomical studies on Sbs variations have not included them and the mechanism causing the variations of the Sbs has not been explored except in a few papers. Yamada, classified Sbs arteries into 2 groups.<sup>40,41</sup> The first group arising from the axillary (Ax) artery proximal to the point where it passed between medial and lateral cords of brachial plexus (penetrated the ventral stratum of the brachial plexus) and the 2nd group arising distal to it. Aizawa et al in a series of 202 dissections, labeled the subscapular and related arteries in the deep region of the axilla, as subscapular artery system (Sbs system) and classified them into 3 groups; S-type, I-type and P-type Sbs systems.<sup>8</sup> In the S-type Sbs system, the Sbs artery branches off the lateral thoracic, which itself emerges from the 2nd part of the axillary artery. In the I-type and P-type Sbs systems, the Sbs artery branches off the proximal and distal segments of the 3rd part of the Ax artery. The anomaly common subscapular-circumflex humeral trunk observed in 2 cadavers in the present study resembles Aizawa's I-type Sbs system but contrarily,

its PCH branch followed a posterior course distal to the axillary nerve. The anomaly common thoraco-humeral trunk observed in one female cadaver was in close resemblance to the Yamada's arteria subscapularis superficialis and Aizawa's S-type Sbs system.<sup>8,40</sup> However, the variations of the Ax artery encountered in the present cases, co-existing with muscular anomalies of flexor digitorum superficialis (common subscapular-circumflex humeral trunk) and abductor pollicis longus and brevis (common subscapular-circumflex humeral trunk and common thoraco-humeral trunk); and anomalous formation of median nerve by 3 roots (common subscapular-circumflex humeral trunk), differ from the previously reported anomalies of the upper extremities. The axilla is frequently the site of growth, abscess, trauma and other pathological lesions, demanding an accurate anatomical knowledge, especially of regional blood vessels and lymphatics, as well as their possible variations. Axillary vessels must be preserved in radical mastectomy, drainage of axillary abscess, surgical decompression of subclavian/axillary artery in thoracic outlet syndrome, management of fracture dislocation of the surgical neck of humerus and axillary lymph node biopsy. Anomalous origin and distribution of subscapular and circumflex humeral arteries make them more vulnerable to trauma. Such aberrations may cause difficulty for invasive cardiologists in cannulation of right subscapular artery, performed for balloon aortic valvoplasty in infants and for plastic surgeons in raising free flap of the serratus anterior muscle for reconstruction. Therefore, both the normal and variant anatomy of the region should be well known for accurate diagnosis and treatment.

**Acknowledgments.** We wish to thank Professor Amonoo-Kuofi and Dr. Khalid Rida Murshid for their generous and critical advice, Mr. Veer for drawing illustrations, Dr. Muhammad Ali Prince and Mr. Hanif Shahid for technical contributions and Mr. M. Moazam for secretarial assistance.

## References

- Poynter CWM. Congenital anomalies of the arteries and veins of the human body with bibliography. University Studies, University of Nebraska 1920; 22: 1-106.
- McCormack LJ, Cauldwell EW, Anson BJ. Brachial and antebrachial arterial patterns: A study of 750 extremities. *Surg Gynecol Obstet* 1953; 96: 43-54.
- Huelke DF. Variation in the origins of the branches of the axillary artery. *Anat Rec* 1959; 35: 33-41.
- Ozan H, Simsek C, Onderoglu S, Kirici Y, Basar R. High division of the axillary artery: A rare case of superficial ulnar artery. *Acta Anat (Basel)* 1994; 151: 68-70.
- Uglietta JP, Kadir S. Arteriographic study of variant arterial anatomy of the upper extremities. *Cardiovasc Intervent Radiol* 1989; 12: 145-148.
- Ciervo A, Kahn M, Pangilinan AJ, Dardik H. Absence of the brachial artery: report of a rare human variation and review of upper extremity arterial anomalies. *J Vasc Surg* 2001; 33: 191-194.
- Jurjus AR, De-Aruaujo RC, Bohn RC. Bilateral double axillary artery: embryological basis and clinical implications. *Clin Anat* 1999; 12: 135-140.
- Aizawa Y, Ohtsuka K, Kumaki K. Examination on the courses of the arteries in the axillary region. I. The course of the subscapular artery system, especially the relationships between the arteries and the posterior cord of the brachial plexus. *Kaibogaku Zasshi* 1995; 70: 554-568.
- Cavdar S, Zeybek A, Bayramicli M. Rare variation of the axillary artery. *Clin Anat* 2000; 13: 66-68.
- Trotter M, Henderson SL, Gass H, Brua RS, Weisman S, Agress H. The origins of branches of the axillary artery in whites and American Negroes. *Anat Rec* 1930; 46: 133-137.
- Sato Y, Takeuchi R, Kawashima T, Takafugi T. On the arterial supply in the human pectoralis major muscle. *Kaibogaku Zasshi* 1976; 51: 311.
- Karlsson S, Niechajev IA. Arterial anatomy of the upper extremity. *Acta Radiol Diagn (Stockh)* 1982; 23: 115-121.
- Sato Y, Takafugi T. Abdominal part of axillary artery: Proposed term for the artery supplying the abdominal part of the musculus pectoralis major. *Acta Anat (Basel)* 1992; 145: 220-228.
- Kogan I, Lewinson D. Variation in the branching of the axillary artery: A description of a rare case. *Acta Anat (Basel)* 1998; 162: 238-240.
- Nakatani T, Tanaka S, Mizukami S. Superficial brachial arteries observed in bilateral arms. *Kaibogaku Zasshi* 1996; 71: 308-312.
- Yucel AH. Unilateral variation of the arterial pattern of the human upper extremity with a muscle variation of the hand. *Acta Med Okayama* 1999; 53: 61-65.
- Fadel RA, Amonoo-Kuofi HS. The superficial ulner artery: development and surgical significance. *Clin Anat* 1996; 9: 128-132.
- Yazar F, Kirici Y, Ozan H, Aldur MM. An unusual variation of the superficial ulnar artery. *Surg Radiol Anat* 1999; 21: 155-157.
- Yildirim M, Kopuz C, Yildiz Z. Report of a rare human variation: the superficial ulner artery arising from the axillary artery. *Okajimas Folia Anat Jpn* 1999; 76: 187-191.
- DeGaris CF, Swartley WB. The axillary artery in White and Negro stocks. *Am J Anat* 1928; 41: 353-397.
- Romanowski CAJ, Fairlie NC, Procter AE, Cumberland DC. Percutaneous transluminal angioplasty of the subclavian and axillary arteries: Initial results and long term follow up. *Clin Radiol* 1992; 46: 104-107.
- McBirde KD, Beard JD, Gaines PA. Percutaneous intervention for radiation damage to axillary arteries. *Clin Radiol* 1994; 49: 630-633.
- Makhoul RG, Machleder HI. Developmental anomalies at the thoracic outlet: an analysis of 200 consecutive cases. *J Vasc Surg* 1992; 16: 534-545.
- Durham JR, Yao JS, Pearce WH, Nuber GM, McCarthy WJ. Arterial injuries in the thoracic outlet syndrome. *J Vasc Surg* 1995; 21: 57-70.
- Cunningham DJ. The blood vascular and lymphatic system. In: Romanes GJ, editor. *Cunningham's textbook of anatomy*. 12th ed. Toronto (Canada): Oxford University press; 1981. p. 915-917.
- Gray H. Axillary artery. In: Bannister LH, Berry MM, Collins P, Dyson M, Dussek JE, Ferguson MWJ, editors. *Gray's Anatomy*. 38th ed. London (UK): Churchill Livingstone; 1995. p. 1537-1538.
- Last RJ. Upper limb. In: Sinnatamby CS, editor. *Last's anatomy: Regional & applied*. 10th ed. Edinburgh: Churchill Livingstone; 1999. p. 48-50, 337.
- Hollinshead WH. Pectoral region, axilla and shoulder. In: Rosse C, Gaddum-Rosse P, editors. *Hollinshead's textbook of Anatomy*. 5th ed. Philadelphia (USA): Lippincott-Raven; 1997. p. 212-216.

29. De-Fontaine S, Decker G, Goldschmidt D. Anomalous blood supply to the serratus anterior muscle flap. *Br J Plast Surg* 1994; 47: 505-506.
30. Nakatani T, Tanaka S, Mizukami S. Anomalous triad of a left sided inferior vena cava, a retroesophageal right subclavian artery, and bilateral superficial brachial arteries in one individual. *Clin Anat* 1998; 11: 112-117.
31. Brown DL, Chapman WC, Edwards WH, Coltharp WH, Stoney WS. Dysphagia lusoria: Aberrant right subclavian artery with a Kommerell's diverticulum. *Am Surg* 1993; 59: 582-586.
32. Austin EH, Wolfe WG. Aneurysm of aberrant subclavian artery with a review of the literature. *J Vasc Surg* 1985; 2: 571-577.
33. Bailey CP, Hirose T, Alba J. Reestablishment of the continuity of the anomalous right subclavian artery after operation for dysphagia lusoria. *Angiology* 1965; 16: 509-513.
34. Moore KL, Persaud TVN. The cardiovascular system. In: *The developing human, clinically oriented embryology*. 6th ed. Philadelphia (PA): WB Saunders; 1998. p. 335-341.
35. Stewart JR, Kincaid OW, Edwards JE. An atlas of vascular rings and related malformations of the aortic arch system. Springfield, (IL): Charles C. Thomas; 1964. p. 53.
36. Kommerell B. Verlagerung des oesophagus durch eine abnorm verlaufende arteria subclavia dextra (arteria lusoria). *Fortschr Geb Roentgenstr Nuklearmed* 1936; 54: 590-595.
37. Hamilton WJ, Mossman HW. Cardiovascular system. In: *Human embryology*. 4th Ed. Baltimore: Williams & Wilkins; 1972. p. 271-290.
38. Collins P. Embryonic circulation. In: Bannister LH, Berry MM, Collins P, Dyson M, Dussek JE, Ferguson MWJ, editors. *Gray's Anatomy*. 38th ed. Edinburgh (UK): Churchill Livingstone; 1995. p. 318-319.
39. Arey LB. Development of the arteries. In: *Developmental anatomy*. 7th ed. Philadelphia (USA) and London (UK): WB Saunders; 1966. p. 371-374.
40. Aizawa Y, Ohtsuka K, Kumaki K. Examination on the courses of the arteries in the axillary region. II. The course of the axillary artery in the case of Adachi's C-type brachial