

## Case Reports

# Iatrogenic perforation of the esophagus

Husain A. Al-Khawahur, MD, Ahmed H. Al-Salem, FRCS, FACS.

---

### ABSTRACT

Iatrogenic perforation of the esophagus occurs rarely, and is most frequently seen in preterm and low birth weight infants. This is a report of 2 cases of iatrogenic perforation of the esophagus, outlining aspects of diagnosis and management.

**Keywords:** Preterm infants, esophageal perforation, iatrogenic.

Saudi Med J 2002; Vol. 23 (6): 732-734

---

Iatrogenic perforation of the esophagus (IPE) is a rare, but well-known complication in the neonatal intensive care unit (NICU). It is seen most commonly in preterm and low birth weight infants following vigorous oropharyngeal suctioning, difficult endotracheal intubation or forceful insertion of nasogastric tube.<sup>1,2</sup> Not uncommonly it is confused with other conditions namely esophageal atresia and esophageal duplication.<sup>1</sup> To obviate this, physicians caring for these patients should be aware of such a complication as early diagnosis and conservative non-operative management can be successful in the majority of these patients. This is a report of 2 cases of IPE outlining aspects of diagnosis and management.

**Case Report. Patient one.** A pre-term, male infant, a product of 25 weeks gestation, normal spontaneous vaginal delivery with a birth weight of 700 grams and apgar score of 2 and 6 at one and 5 minutes. He was intubated immediately after birth and needed ventilatory support due to respiratory distress syndrome. His physical examination was unremarkable. He was kept, nil by mouth (NPO) and started on intravenous fluids and antibiotics. His chest x-ray was carried out after nasogastric tube (NGT) insertion and showed the NGT deviated to the

right side of the chest (**Figure 1**). The site of the NGT was confirmed to be in the right pleural cavity by contrast study through the NGT (**Figure 2**). After aspirating the contrast from the pleural space, the NGT was pulled out, and another NGT was inserted, and this passed down to the stomach. The patient was kept, NPO and started on total parenteral nutrition (TPN). Later on, he died due to gram negative septicemia.

**Patient 2.** A preterm male infant, a product of 36 weeks gestation and normal spontaneous vaginal delivery. His birth weight was 2400 grams, and apgar score of 9 and 10 at 1 and 5 minutes. He was admitted to the NICU due to respiratory distress. Chest x-ray that was carried out after NGT insertion and before starting feeding revealed NGT in the right hemithorax. The NGT was pulled and reinserted and passed down to the stomach. The patient was kept NPO and started on TPN for 10 days. Feeding was started after that, which he tolerated well and was discharged home, in a good general condition.

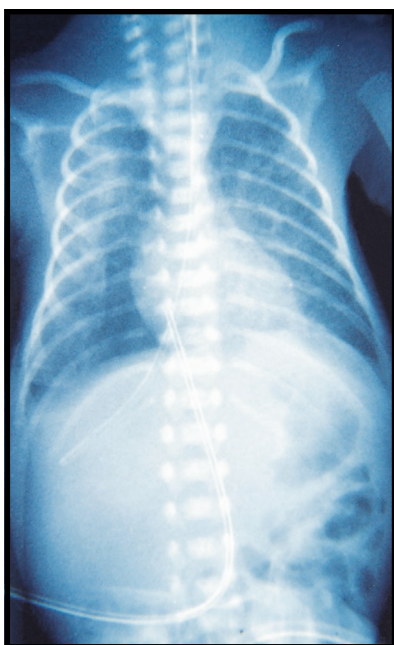
**Discussion.** Iatrogenic perforation of the esophagus is rare and occurs most frequently in preterm and low birth weight infants.<sup>1-4</sup> Both of our patients were preterm and one weighed only 700 grams. The causes of IPE include repeated and

---

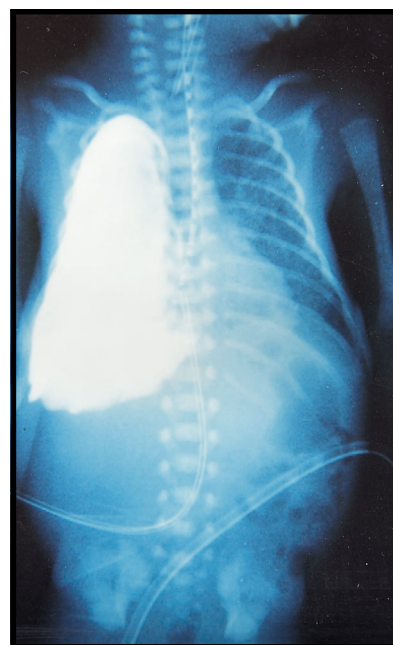
From the Department of Pediatrics and Pediatric Surgery, Qatif Central Hospital, Qatif, Kingdom of Saudi Arabia.

Received 14th July 2001. Accepted for publication in final form 28th October 2001.

Address correspondence and reprint request to: Dr. Husain A. Al-Khawahur, Eastern Province 31911, Jish PO Box 18003, Qatif, Kingdom of Saudi Arabia. E-mail: hakh\_1999@yahoo.com



**Figure 1** - Chest x-ray showing the nasogastric tube deviated to the right side.



**Figure 2** - Contrast study carried out through the nasogastric tube showing the contrast filled right pleural cavity.

difficult attempts of endotracheal intubation, vigorous oropharyngeal suctioning, and over-enthusiastic insertion of NGT.<sup>1,2</sup> It has also been reported following traumatic breech delivery.<sup>5</sup>

The diagnosis of IPE is often made from a routine chest x-ray that shows abnormal position of the NGT, with or without pneumothorax, pneumomediastinum or pleural effusion.<sup>6</sup> The diagnosis can be confirmed by contrast esophagography using water-soluble dye through an end hole catheter and under fluoroscopic control. Mollitt et al<sup>7</sup> described 3 types of esophageal perforation using contrast esophagography: a retropharyngeal pouch or pseudodiverticulum, a submucosal perforation represented by a narrow tract running parallel and posterior to the esophagus, and a free intraperitoneal perforation. The value of direct esophagoscopy in the diagnosis of IPE is still controversial. Esophagoscopy has several advantages including direct visualization of the orifice of the perforation and it enables us to distinguish an esophageal perforation from a true diverticulum as well as correctly placing the NGT under vision.<sup>8,9</sup> Direct esophagoscopy, however, is not without complications, as it is an invasive procedure with its own morbidity especially in premature and low birth weight infants, and it may worsen and enlarge the perforation.<sup>10</sup> In both our patients, the diagnoses were made on routine chest x-ray, and in one it was confirmed by contrast study. The facts that in both our patients, the inserted NGT passed into the stomach exclude esophageal atresia.

The management of IPE is controversial, and the 2 management options are surgery or conservative non-

operative approach.<sup>7</sup> This depends on the site and extent of perforation as well the presence of complications.

Non-operative conservative management is the treatment of choice, and surgery is reserved for perforation related complications such as mediastinal or cervical abscess, pneumomediastinum with clinical deterioration, persistent of esophageal leak despite conservative treatment, or wide esophageal perforation.<sup>7,8,11</sup> Chest tube drainage is indicated in cases complicated by pneumothorax or pleural effusion.<sup>1,7</sup> These infants should be started on antibiotics and nutritional support. It is debated whether an NGT should be inserted, as it will most often fail. The success in reinserting the NGT however will alleviate the need for total parenteral nutrition or gastrostomy, as nutritional support, can be provided through the NGT. In both our patients reinsertion of the NGT was attempted, and it was successful. Iatrogenic perforation esophagus has been associated with a high mortality, and the outcome is complicated by the fact that it occurs in premature and low birth weight infants. A 20%-23% mortality rate has been reported in the literature.<sup>1</sup> One of our patients died of gram negative septicemia, while the other was treated conservatively and survived.

## References

1. Sapin E, Gumpert L, Bonnrd A, Ecarricaburu E, Sava P, Contencin P et al. Iatrogenic Pharyngoesophageal Perforation in Premature Infants. *Eur J Pediatr Surg* 2000; 10: 83-87.

2. Grunebaum M, Horodniceanu C, Wilunsky E, Reisner S. Iatrogenic transmural perforation of the esophagus in pre-term infant. *Clin Radiol* 1980; 31: 257-261.
3. Bonnard A, Carricaburu E, Sapin E. Traumatic Pharyngoesophageal Perforation in newborn infants. *Arch Pediatr* 1997; 4: 737-743.
4. Flores-Nava G, Joachin-Roy H, Rodriguez-Cueto G. Esophageal Perforation in premature newborn infants. Presentation of 8 cases. *Bol Med Hosp Infant Mex* 1993; 50: 749-753.
5. Tekant G, Abbasoglu L, Sever N, Bulut M. Traumatic esophageal perforation in a premature infant. *Turk J Pediatr* 1990; 32: 123-126.
6. Clarke TA, Coen RW, Feldman B, Papile L. Esophageal perforations in premature infants and comments on the diagnosis. *Am J Dis Child* 1980; 134: 367-368 .
7. Mollitt DL, Schullinger JN, Santulli TV. Selective management of iatrogenic esophageal perforation in the newborn. *J Pediatr Surg* 1981; 16: 989-993.
8. Blair GK, Filler RM, Theodorescu D. Neonatal Pharyngoesophageal perforation mimicking esophageal atresia: Clues to diagnosis. *J Pediatr Surg* 1987; 22: 770-774.
9. Lynch FP, Coran AG, Cohen SR, Lee FA. Traumatic esophageal Pseudodiverticula in the newborn. *J Pediatr Surg* 1974; 9: 675-681.
10. Nagaraj HS, Mullen P, Groff DB, Shearer LT, Cock LN. Iatrogenic perforation of the esophagus in premature infants. *Surgery* 1979; 86: 583-589.
11. Merlini E, Odone M, Seymandi PL, Durante GF. Conservative treatment of esophageal perforation in the newborn infant. Description of a case. *Pediatr Med Chir* 1985; 7: 459-461.