Insulin enhances amylase and lipase activity in the pancreas of streptozotocin-diabetic rats

An in vivo study

Adib A. Aughsteen, *MBChB, PhD,* ***Faisal I. Mohammed,*** *MD, PhD.*

ABSTRACT

Objectives: To analyze the biochemical effect of in vivo insulin therapy on the amylase and lipase activities in the pancreatic acinar cells of streptozotocin-diabetic rats, and to detect any possible regeneration in the beta cells of the islets of Langerhans using transmission electron microscopy.

Methods: Adult male albino Fischer-344 rats were divided into 3 groups, the first group received drug vehicle and served as controls, the 2nd group was made diabetic with a single intravenous dose of streptozotocin (75 mg/kg body weight), while the 3rd group was made diabetic as in its 2nd group but the rats were treated with Lente human insulin. Their body weight, blood glucose and glucosuria were regularly recorded, and blood samples for serum immunoreactive insulin assay were taken from each rat at sacrifice. The largest part of each excised pancreas was homogenized for biochemical assay of amylase, lipase and insulin, while only a small part of the gland was used for morphological survey. The study was conducted in the Faculty of Medicine, University of Jordan, Amman, Jordan.

Results: The serum immunoreactive and pancreatic-homogenate insulin levels of the untreated diabetic rats were reduced by 85% and 37% compared with those of the controls. Their pancreatic amylase and lipase levels were also reduced by 66% and 43%. Insulin treatment of diabetic rats resulted in a 65-fold increase in serum immunoreactive insulin, and approximately 61%, 47%, and 25% increase in the pancreatic-homogenate levels of amylase, lipase, and insulin. Electron microscopic examination of the pancreas of untreated and insulin-treated diabetic rats showed no evidence of beta cell regeneration.

Conclusion: Inspite of the controversies in an extensively studied field of in vivo and in vitro influence of insulin on pancreatic enzymes, our present biochemical data clearly indicates that in vivo insulin administration has a stimulant effect on both amylase and lipase activity in the pancreatic acinar cells of streptozotocin-diabetic rats. It also proposes that insulin might play an important role in beta cell regeneration although no morphological evidence of beta cell mitosis was demonstrable. We finally suggest that the biochemical assay of pancreatic enzymes might be of value in determining the severity and chronicity of human insulin-dependent diabetes, and can be used as a parameter in evaluating the response to treatment.

Keywords: Rats, pancreas, streptozotocin-diabetes, Lente insulin, amylase, lipase.

Saudi Med J 2002; Vol. 23 (7): 838-844

From the Faculty of Pharmacy and Medical Laboratories (Aughsteen), Al-Zaytoonah University, and the Department of Physiology and Biochemistry (Mohammed), Faculty of Medicine, University of Jordan, Amman, *Jordan.*

Received 1st December 2001. Accepted for publication in final form 11th March 2002.

Address correspondence and reprint request to: Dr. Adib A. Aughsteen, Assistant Professor of Anatomy, Faculty of Pharmacy and Medical Laboratories, Al-Zaytoonah University, PO Box 130, Amman 11733, *Jordan*. Tel. +962 (6) 4291511 Ext. 314. Fax. +962 (6) 4291432. E-mail: adib@go.com.jo

The pancreas, an integrated gastrointestinal gland, has been long known to consist of exocrine and endocrine parts.[1,2] Its endocrine part is represented by the islets of Langerhans and many discrete single cells scattered among the exocrine tissue, which together account for approximately 1-2% of the total glandular mass.[3] The coexistence of these 2 structurally and functionally different parts has postulated the direct influence of endocrine hormones on the physiology of exocrine acini. Among the earliest evidence on such interaction was the description of zymogen halo around the islet of Langerhans in several animal species.[4-7] This was further confirmed by the disappearance of zymogen halo in alloxan and streptozotocin-induced diabetes.[7,8] Subsequent scanning electron microscopic studies on the pancreatic circulation in different species have demonstrated the existence of an islet-acinar portal blood system responsible for delivery of high concentration of islet hormones into the adjacent acini.[9,10] A large body of literature has focused on the role of insulin on the regulation of enzyme synthesis in the pancreatic exocrine cells.[11-13] Streptozotocin-induced diabetes of experimental animals, a model similar to human insulin-dependent diabetes mellitus, has widely been used to elucidate the role of insulin on exocrine pancreatic function using morphometric, biochemical, and immunohistochemical methods.[14-20] Several in vivo and in vitro experiments have shown that insulin administration results in an increased incorporation of radiolabeled amino acids into the proteins of the pancreas of normal or streptozotocin-diabetes animals.[12,15,16] This effect has been attributed to direct influence of insulin on pancreatic enzyme synthesis and not due to normoglycemia achieved by insulin therapy. Reports concerning the effect of insulin on pancreatic enzymes synthesis are controversial. A number of researchers have demonstrated an increased synthesis of amylase with a decrease in lipase and chymotrypsin levels when insulin was administered in the streptozotocin-diabetic rats.[19,20] Decreased amylase-immunostaining with increased lipase and chymotrypsin immunolabeling has been illustrated in pancreatic sections from streptozotocin-diabetic rats, which was restored to normal after insulin treatment.[17,18] Others on the contrary, have recorded stimulant effect of insulin on almost all pancreatic enzymes.[12,21-23] In our previous morphometric study on streptozotocin-diabetic rats,[14] we have demonstrated a reduction in the number of zymogen granules, which corresponded well with the reduction in amylase content of pancreatic-tissue homogenate. No attempt at the time was made to analyze the effect of insulin administration on the morphology and amylase content of diabetic pancreatic tissue. Therefore, the present study aims at exploring the influence of in vivo insulin administration on amylase and lipase activity of acinar tissue in the streptozotocin-diabetic rats. It also examines the morphology of islets of Langerhans before and after insulin therapy for any evidence of possible beta cell regeneration.

Methods. Adult male albino Fischer-344 rats (250-290 g body weight) raised at Jordan University Animal House were used in the study following the principles of laboratory animal care. A group of normal rats received citrate buffer as a drug vehicle and maintained on normal food pellets were used as controls. Another group of 20 rats were starved of food overnight and injected with a single dose of streptozotocin (75 mg/kg body weight, Sigma Chemical Co, St. Louis, MO, United States of America [USA]) in 0.05 M citrate buffer (pH 4.5) via the tail vein. They were equally divided into 2 groups; one group was followed up for one week and the rats were killed together with those of the control group, while the other group of streptozotocin-diabetic rats were followed up for one week, and were then treated with Lente human insulin zinc suspension (Humulin L, Eli Lilly and Company, Indianapolis, IN, USA) in a single daily dose of one unit/each 50 mg rise in blood sugar for one week. All insulin-treated diabetic rats were killed 2 hours after the last injection. The body weight, blood glucose and glucosuria of each rat per each experimental condition were determined at the onset of experiment and every other day following streptozotocin injection. The glucosuria was determined with Glukotest (Boehringer, Mannheim, Germany), and the blood glucose was estimated from the fresh whole blood sample by glucose oxidase/peroxidase reaction[24,25] using Prestige Blood Glucose System (Home Diagnostic Inc, Fort Lauderdale, FL, USA). In each experimental condition, 4 rats were included in the study and were sacrificed under Nembutal anesthesia. Samples for blood glucose and serum immunoreactive insulin assay were taken from each rat, and the pancreas was rapidly excised, dissected from fat and connective tissue and divided into 2 parts. The larger part of each pancreas was used for biochemical assay of amylase, lipase, and insulin. Its wet weight was determined and homogenized in 5 ml of distilled water using MS-35 stirrer (Tokyo, Rikakikai Co, LTD, Japan). The tissue homogenate was slowly centrifuged to remove unbroken cells and was kept frozen at -20°C for biochemical assay. The smaller part of the pancreas was processed for electron microscopic examination.

Biochemical methods. The amylase content of pancreatic tissue was assayed according to the dinitrosalicylic acid method of Bernfeld.[26] The homogenized samples were thawed at room temperature, and 0.5 ml of the supernatant of tissue-homogenate was added to 0.5 ml of 1% starch solution in 0.02 M phosphate buffer (pH 6.8) in a

shaking water bath at 37°C. The reaction was stopped after 3 minutes with one ml of dinitrosalicylic acid reagent (one percent dinitrosalicylic acid and 30% potassium sodium tartrate in 0.5 M sodium hydroxide). Blank samples were prepared in the same way but 0.5 ml of distilled water was added instead of tissue homogenate. Standard samples of maltose were prepared by adding 0.5 ml of aqueous maltose solution (10 mg/ml) to 0.5 ml distilled water and one ml of dinitrosalicylic acid reagent. All samples were developed in boiling water for 5 minutes, cooled at room temperature and were adequately diluted with distilled water to keep the absorbance of the samples within the range of 0.01-1.00. The absorbance of the samples was measured using a Jenway Model-6100 spectrophotometer (Jenway LTD, Essex, England) set at 540 nm. Amylase activity was expressed as units/100 mg wet weight of pancreas, where each unit is equal to one mg maltose liberated during the 3 minutes reaction. The sample of pancreatic homogenate of each rat per each experimental condition was assayed in duplicate. The pancreatic lipase was determined from tissue homogenates by ultraviolet method using SYS 1 BM/ Hitachi 704 instrument (Boehringer, Mannheim, Germany), which uses triolein as a substrate.[27] According to this method, each unit of lipase activity is equal to the amount of lipase that catalyzes one µmol of triolein in one minute under standard conditions. The lipase activity in each animal was presented as units/100 mg wet weight of the pancreas. The serum immunoreactive insulin was measured by the Microparticle Enzyme Immunoassay (MEIA) technology using AxSYM insulin assay apparatus (Abbott Lab., Abbott Park, IL, USA). The pancreatic insulin was measured from the tissue homogenates using Immulite Automated Immunoassay Analyzer (Diagnostic Product Corporation, Los Angeles, CA, USA). This method is based on assay-specific antibody or antigen-coated plastic beads as a solid phase, alkaline phosphate-labeled reagent, and a chemiluminescent enzyme substrate. The estimates of serum immunoreactive insulin and pancreatic-homogenate insulin for each animal were presented as µU/ml, and µU/100 mg wet weight of the pancreas. Statistical analysis of all biochemical data was carried out using Student's T-test.

Electron microscopic preparation. The pancreatic tissue from each rat was minced into small pieces, fixed in 2.5% glutaraldehyde in 0.1 M sodium cacodylate buffer (pH 7.4) and left overnight at 4°C. They were rapidly washed with the buffer and postfixed in one percent osmium tetroxide in 0.1 M sodium cacodylate buffer (pH 7.4) for 2 hours at 4°C. The tissue samples were dehydrated in graded acetone and embedded in spurr's plastic media. One µm thick sections were cut using Sorvall Porter-Blum ultramicrotome (Ivan Sorvall Inc, Newtown, Connecticut, USA), stained with one percent toluidine blue and examined with a light microscope to ensure the presence of islets. Ultrathin sections of gray to silver interference color were cut and mounted on uncoated 200-mesh copper grids. They were doubly stained with uranyl acetate and lead citrate and examined with a Zeiss EM 10 CR electron microscope (Zeiss, Oberkochen, Germany).

Results.

Data of body weight, blood glucose and glucosuria. **Table 1** summarizes the mean data of body weight, blood glucose and glucosuria in the 3 groups of rats. For simplicity, the presented data include only those recorded at the onset of experiment and at the time of sacrifice. In the normal rats, there was a slight increase in the body weight, normoglycemia and no glucosuria. The untreated-diabetic rats showed significant reduction in body weight, remarkable hyperglycemia, and significant glucosuria. In the insulin-treated diabetic rats, there was an obvious gain in body weight during the period of insulin therapy following a significant reduction produced by streptozotocin injection. Their blood glucose returned to normoglycemic values after remarkable hyperglycemia induced by streptozotocin, and their urine became clear of sugar after streptozotocin-induced glucosuria.

Biochemical data of tissue amylase and lipase. **Table 2** records the levels of amylase and lipase in pancreatic-homogenates of the 3 experimental groups of rats. The amylase content of the pancreas of streptozotocin-diabetic rats was 66% lower than that of control rats. The amylase level of insulin-treated diabetic rats was increased by 61% compared with that of untreated diabetic rats. Streptozotocin-diabetes also significantly lowered the lipase content of pancreatic tissue by 43% compared with that of control rats. Similar to amylase data, treatment of diabetic rats with insulin increased lipase content of acinar tissue approximately by 47% compared with untreated diabetic rats.

Data of serum immunoreactive insulin and pancreatic-homogenate insulin. **Table 3** records the estimates of serum immunoreactive and tissue-homogenate insulin in the 3 experimental groups. The mean value of serum immunoreactive insulin in streptozotocin-diabetic rats was 85% lower than that of control rats. The serum insulin value of insulin-treated diabetic rats estimated 2 hours after the last insulin injection was 65-fold and 10-fold higher than those of untreated-diabetic and control rats. The estimated mean value of pancreatic-homogenate insulin of untreated diabetic rats was 37% lower than that of controls. In the insulin-treated diabetic rats, injection of Lente human insulin for 7 days increased the insulin level of tissue homogenate by 25% compared with untreated diabetic rats.

Morphological findings. Electron microscopic examination of the islets of normal rats revealed

Table 1 - The mean values of the body weight, blood glucose and glucosuria of the control, streptozotocin-diabetic and insulin-treated streptozotocin-diabetic rats (N=4).

Measured parameters	Control rats	Diabetic rats	Insulin-treated diabetic rats
B. wt. at onset of experiment (g)	293.3 ± 4.43	265.5 ± 7.73‡	242.8 ± 4.0* (227.0 ± 5.6*,†)
B. wt. at sacrifice (g)	302.0 ± 4.73	222.3 ± 9.03‡	262.5 ± 10.1†
Bd. Gl. at onset of experiment (mg/dL, fasting)	54.0 ± 1.0	55.8 ± 2.13§	51.5 ± 1.3§ (482.0 ± 37.2§)
Bd. Gl. at sacrifice (mg/dL, random)	81.0 ± 10.5	446.5 ± 13.46§	64.0 ± 7.3§
Glucosuria at onset of experiment (mg/dL)	-ve (<50)	-ve (<50)	-ve, <50 (++++, >1000)
Glucosuria at sacrifice (mg/dL)	-ve (<50)	++++, > 1000	-ve, <50

The data in each experimental group is mean ± standard error of mean pooled from a group of 4 rats.
The values in parenthesis in the insulin-treated diabetic rate are estimates obtained 7 days after streptozotocin treatment before insulin therapy.
N - number, B. wt. - body weight, Bd. Gl. - blood glucose, * statistically significant at p <0.1, † - statistically significant at p<0.005, ‡ - statistically significant at p<0.025 § - statistically significant at p<0.001, -ve - negative.

Table 2 - The amylase and lipase activity in the pancreatic-homogenate of normal, streptozotocin-diabetic and insulin-treated streptozotocin-diabetic rats (N=4).

Animals	Amylase activity (U/100mg wet weight of pancreas)	Lipase activity (U/100mg wet weight of pancreas)
Control rats		
1	29.3 ± 2.63	81.50
2	27.4 ± 2.96	67
3	31.4 ± 1.12	100.70
4	35.5 ± 4.02	114.70
Mean ± SEM	30.90 ± 1.50*	90.98 ± 9.09†
Diabetic rats		
1	8.3 ± 0.88	52.30
2	11.3 ± 0.58	51.50
3	11.2 ± 0.09	48.67
4	11.6 ± 1.38	55.20
Mean ± SEM	10.60 ± 0.67*,‡	51.92 + 1.16†,‡
Insulin-treated diabetic rats		
1	29.4 ± 0.88	92.65
2	25.5 ± 0.77	112
3	28.6 ± 0.77	88
4	25.8 ± 4.06	102
Mean ± SEM	27.33 ± 0.85‡	98.66 + 4.60‡

* - statistically significant at p<0.005, † - statistically significant at p<0.01, ‡ - statistically significant at p<0.001,
SEM - standard error of mean, N - number.

Table 3 - The estimates of serum immunoreactive and pancreatic-homogenate insulin of the control, streptozotocin-diabetic, and insulin-treated streptozotocin-diabetic rats (N=4).

Animals	Serum immunoreactive insulin (µU/ml)	Pancreatic-homogenate insulin (µU/100mg wet weight of pancreas)
Control rats		
1	21.4	15
2	38.1	15.8
3	17.6	14.02
4	19.0	10.26
Mean ± SEM	24.03 ± 4.12*†	13.80 ± 1.06‡
Diabetic rats		
1	4.1	8.68
2	0.9	10.31
3	3.9	7.36
4	5.5	8.37
Mean ± SEM	3.60 ± 0.84*,†	8.70 ± 0.53‡,§
Insulin-treated diabetic rats		
1	277	13.5
2	188.7	13.31
3	219	11.20
4	193	8.38
Mean ± SEM	232.9 ± 22.1†	11.60 ± 1.04§

* - statistically significant at p<0.005, † - statistically significant at p<0.001, ‡ - statistically significant at p<0.01,
§ - statistically significant at p<0.1, SEM - standard error of mean, N - number.

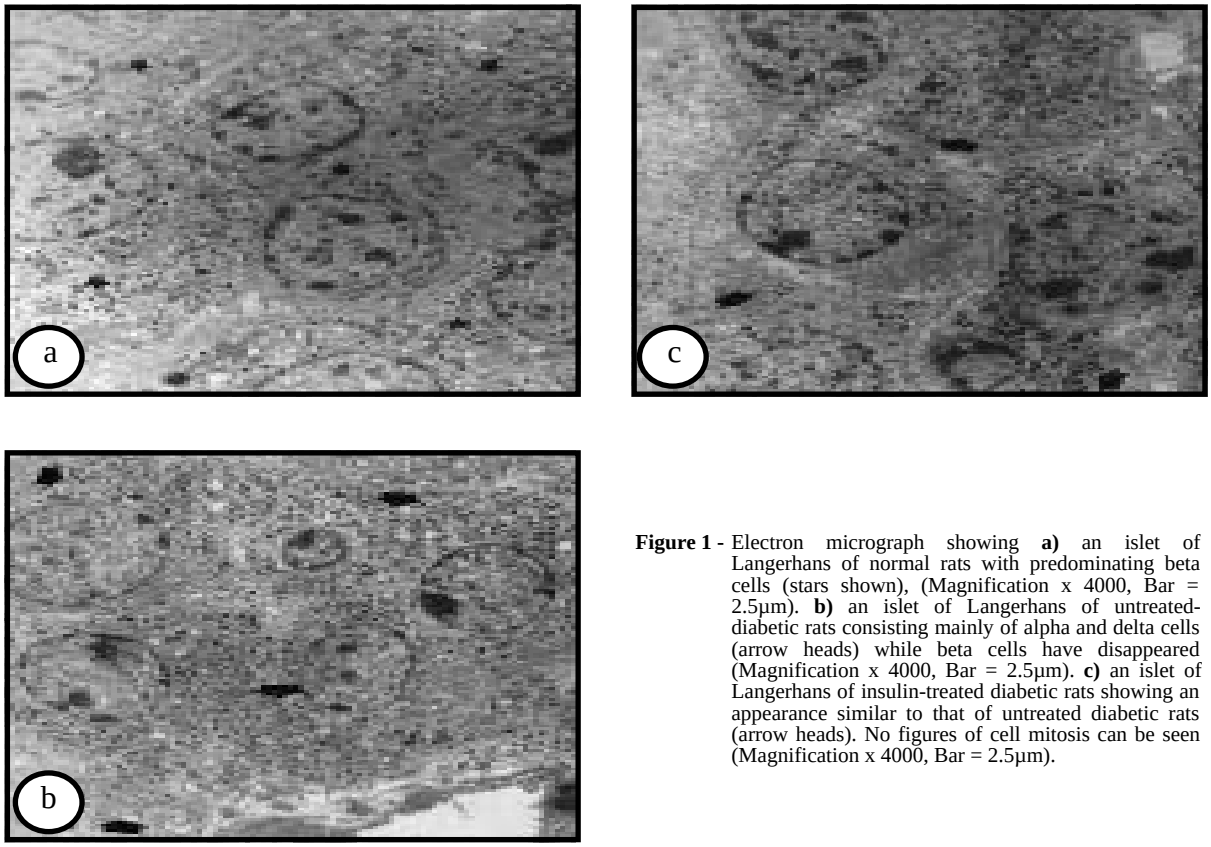

Figure 1 - Electron micrograph showing **a)** an islet of Langerhans of normal rats with predominating beta cells (stars shown), (Magnification x 4000, Bar = 2.5µm). **b)** an islet of Langerhans of untreated-diabetic rats consisting mainly of alpha and delta cells (arrow heads) while beta cells have disappeared (Magnification x 4000, Bar = 2.5µm). **c)** an islet of Langerhans of insulin-treated diabetic rats showing an appearance similar to that of untreated diabetic rats (arrow heads). No figures of cell mitosis can be seen (Magnification x 4000, Bar = 2.5µm).

many centrally located beta cells and few peripheral alpha and delta cells (**Figure 1a**). The islets of untreated diabetic rats were smaller in size, depleted of beta cells, and consisted mainly of alpha, delta and pancreatic polypeptide cells (**Figure 1b**). In the insulin-treated rats, the morphology of the islets was similar to that of untreated diabetic rats, and no figures of mitosis were ever seen in the islet or excretory duct cells (**Figure 1c**). The acinar cells of diabetic and insulin-treated diabetic pancreas contained many dense zymogen granules and their appearance looked similar to that of control rats. No attempt in the present study was made to quantify the zymogen granule content of acinar cells in the 3 experimental groups of rats.

Discussion. The present study is a biochemical analysis on the effect of in vivo insulin therapy on the pancreatic content of amylase and lipase in streptozotocin-diabetic rats. It also records changes in their body weight, blood glucose, urinary glucose, serum immunoreactive and pancreatic-homogenate insulin levels before and after insulin treatment. Ultrastructural survey was also conducted to analyze the associated morphological changes in islet cells, and to record any possible regeneration in beta cells. Similar to many previous reports,[28-30] streptozotocin in a single intravenous dose of 75 mg/kg body weight resulted in a state of diabetes which persisted through out the experiment. This dose of streptozotocin was chosen after a high mortality rate recorded in preliminary studies on rats injected with 100 mg/kg body weight. Also, in our previous studies we have successfully used similar doses to establish a state of diabetes in both rats and mice.[7,14,16] The present morphologic findings have further confirmed the specific toxic effect of streptozotocin on beta cells with unaltered, normal-looking alpha, delta and PP cells.[7,28,29] Our present biochemical data in the streptozotocin-diabetic rats showed an obvious reduction in pancreatic levels of both amylase and lipase. This reduction was nearly restored to normal values after subcutaneous insulin administration. Amylase and lipase were only assayed as no facilities for estimating other pancreatic enzymes were available. The results indicate that insulin has a stimulant effect on these 2 enzymes and probably exerts similar influence on other pancreatic hydrolases. Previous studies[11,12,22,31] have

demonstrated transcriptional and translational effect of insulin on pancreatic amylase synthesis. Korc et al.[11] from their in vitro study on insulin-treated pancreatic lobules of diabetic rats have clearly shown that insulin enhancement of pancreatic amylase synthesis was associated with a rise in amylase mRNA level. Reports on the role of insulin on lipase, trypsinogen, chymotrypsinogen, and other pancreatic enzyme synthesis are widely debated. Okabayashi et al.[12] in their study on isolated pancreatic acini from streptozotocin-diabetic rats have demonstrated a dose-dependent, nonparallel increase in the incorporation of radiolabeled methionine into amylase, trypsin, ribonuclease and lactic dehydrogenase. Similarly, Lahaie[21] has reported an increase in the amylase, lipase, trypsinogen and chymotrypsinogen content of pancreatic acini of streptozotocin- diabetic rats after in vitro exposure to insulin. Studies on human insulin-dependent diabetes have reported reduction in amylase, lipase, trypsin and bicarbonate content of pancreatic secretion in response to secretin-pancreozymin test.[32-35] In contrary to these findings, a reduction in pancreatic lipase and chymptrypsinogen levels in response to insulin therapy has been reported in streptozotocin-diabetic rats[17-20] Moreover, Duan et al[36] and Duan and Erlanson-Albertsson[37] from their in vivo studies on streptozotocin-diabetic rats have demonstrated that insulin dose-dependently lowers the lipase and colipase content of the pancreas and decreased incorporation of radiolabeled Cysteine into these enzymes. Dot-blot hybridization with complementary DNA (cDNA) probes revealed a reduction in both lipase and colipase messenger ribonucleic acid (mRNA), suggesting a transcriptional or pretranslational inhibitory action of insulin on lipase and colipase synthesis.[36,37] Among this controversy on the action of insulin on pancreatic exocrine function, our present data shows that insulin has a stimulant effect on both amylase and lipase synthesis, an effect being more evident on amylase. These results are supported by our previous morphologic, radioautographic, immunohistochemical, and biochemical studies on the pancreas of streptozotocin-diabetic rats and mice.[14,16] They have clearly demonstrated the significant role of insulin in morphological partition between pancreatic acinar cells in respect to their location from the islet of Langerhans. In our previous morphometric report on rats,[7] we have estimated a 36% and 46% reduction of zymogen granule number and volume in the pancreatic acinar cells 3 weeks after streptozotocin-induced diabetes. Corresponding to this data, the amylase content of diabetic pancreas was reduced by 37% compared with that of normal rats. In our present study, we could not observe any morphological evidence of islet-cell regeneration, especially beta cells, in the insulin-treated diabetic rats although an increase in pancreatic-homogenate insulin was biochemically recorded. The reason for this increment could be either due to probable regeneration of beta cells which was not detected morphologically, or due to the influence of administered insulin present in the capillaries of homogenized-pancreatic tissue. Ohashi[38] working on 92% surgically pancreatectomized dogs has concluded that insulin therapy enhances proliferation of the remnant pancreas, which maintains the endogenous insulin secretion necessary for prolonging survival and promoting pancreatic regeneration. Moreover, morphological evidence in form of ductal cell proliferation and alpha cell neogenesis have been illustrated in diabetic non-insulin dependent mice, which propose similar and probable beta cell neogenesis in the human insulin-dependent diabetes mellitus.[39]

In conclusion, our present data emphasizes that insulin has a stimulant effect on pancreatic amylase and lipase activity, but provides no information on the mechanisms by which it produces such effect. It also proposes a possible role of insulin in beta cell regeneration, and suggests that enzyme analysis of pancreatic juice could be of value in determining the severity and chronicity of human insulin-dependent diabetes.

Acknowledgment. The study was supported by a research grant No. 464 from the Deanship of Scientific Research during author service in the Department of Anatomy and Histology, Faculty of Medicine, University of Jordan, Amman, Jordan.

References

1. Williams JA, Goldfine ID. The insulo-pancreatic acinar axis. *Diabetes* 1985; 34: 980-986.
2. Ross MH, Reith EJ. Histology: A Text and Atlas. Harper International Edition. New York (NY): Harper and Row Publishers; 1985. p. 484-492.
3. Bolender RP. Stereological analysis of guinea-pig pancreas. 1-Analytic model and quantitative description of non-stimulated exocrine cells. *J Cell Biol* 1974; 61: 269-287.
4. Jarotsky AJ. Uber die veranderungen in der grosse und im bau der pankreaszellen bei einigen arten inanition. *Pathology and Anatomy* 1899; 156: 409-450.
5. Hellman B, Wallgren A, Petersson A. Cytological characteristics of the exocrine pancreatic cells with regards to their position in relation to the islets of Langerhans. *Acta Endocrinol* 1962; 39: 465-473.
6. Bendayan M, Ito S. Immunohistochemical localization of exocrine enzymes in normal rat pancreas. *Journal of Biochemistry and Cytochemistry* 1979; 27: 1029-1034.
7. Aughsteen AA, Kataoka K. Morphometric studies on the juxta-insular and tele-insular acinar cells of the pancreas in normal and streptozotocin-induced diabetic rats. *J Electron Microsc* 1993; 42: 79-87.
8. Kramer MF, Tan HT. The peri-insular acini of the pancreas of the rat. *Zeitschrift fur Zellforschung* 1968; 86: 163-170.
9. Murakami T, Fujita T. Microcirculation of the rat pancreas, with special reference to the insuloacinar portal and insulo-venous drainage systems. A further scanning electron microscope study of corrosion casts. *Arch Histol Cytol* 1992; 55: 453-476.

10. Murakami T, Fujita T, Miyake T, Ohtsuka A, Taguchi T, Kikuta A. The insulo-acini portal and insulo-venous drainage systems in the pancreas of the mouse, dog, monkey, and certain other animals: A scanning electron microscopic study of corrosion casts. *Arch Histol Cytol* 1993; 56: 127-147.
11. Korc M, Owerbach D, Quinto C, Rutter WJ. Pancreatic islet-acinar interaction: Amylase messenger RNA levels are determined by insulin. *Science* 1981; 213: 351-353.
12. Okabayashi Y, Moessner J, Logsdon CD, Goldfine ID, Williams JA. Insulin and other stimulants have nonparallel translational effects on protein synthesis. *Diabetes* 1987; 36: 1054-1060.
13. Alvarez C, Lopez MA. Effect of alloxan diabetes on exocrine pancreatic secretion in the anesthetized rabbit. *Int J Pancreatol* 1989; 5: 229-238.
14. Aughsteen AA, Kataoka K, Shair SA. Correlative morphometric and biochemical study on pancreatic amylase in normal and streptozotocin-diabetic rats. *Pancreas* 1996; 13: 295-303.
15. Kramer MF, Poort C. The effect of insulin on amino acid incorporation into exocrine pancreatic cells of the rats. *Horm Metab Res* 1975; 7: 389-393.
16. Aughsteen AA, Kataoka K. Quantitative radioautographic study on ^{3}H-leucine uptake of peri- and tele-insular acinar cells of the pancreas in normal and streptozotocin-diabetic mice. *Acta Cytochemica et Histochemica* 1994; 27: 67-74.
17. Gregoire S, Bendayan M. Immunocytochemical studies of pancreatic acinar cells in normal and streptozotocin-induced diabetic rats. *Diabetologia* 1986; 29: 655-660.
18. Bendayan M, Levy E. Immunocytochemical and biochemical evaluation of pancreatic lipase in acinar cells of control and streptozotocin-induced diabetic rats. *Pancreas* 1988; 3: 269-273.
19. Lee PC, Jordan M, Pieper GM, Roza AM. Normalization of pancreatic exocrine enzyme by islet transplantation in diabetic rats. *Biochem Cell Biol* 1995; 73: 269-273.
20. Duan RD, Sternby B. Decrease in contents of pancreatic carboxyl ester lipase, phospholipase A2, and lingual lipase in rats with streptozotocin-induced diabetes. *Scand J Gastroenterol* 1993; 28: 256-260.
21. Lahaie RG. Translational control of protein synthesis in isolated rat pancreatic acini. *J Gastroenterol* 1984; 86: 1149.
22. Tsai A, Cowan MR, Johnson DG, Brannon PM. Regulation of pancreatic amylase and lipase gene expression by diet and insulin in diabetic rats. *Am J Physiol* 1994; 26: G575-G583.
23. Hegyi P, Czako L, Takacs T, Szilvassy Z, Lonoics J. Pancreatic secretory responses in L-arginine induced pancreatitis: comparison of diabetic and nondiabetic rats. *Pancreas* 1999; 19: 167-174.
24. Keston A. Specific colorimetric enzymatic reagents for glucose. Abstracts of papers. Proceedings of the 129th Meeting; 1956 April; Dallas (TX), USA. Dalas (TX): American Chemical Society; 1956. p. 31C.
25. Smalley DL, Bradley ME. New test for urinary glucose (BM33071) evaluated. *Clin Chem* 1985; 31: 90-92.
26. Bernfeld P. Amylases, a and b, In: Colowick SP, Kaplan NO, editors. Methods in enzymology. Vol. 2. New York (NY), London (UK): Academic Press; 1955. p. 149-158.
27. Ziegenhorn J, Neumann U, Knitsch KW, Zwez W. Determination of serum lipase. *Clin Chem* 1979; 25: 1067.
28. Schlosser MJ, Kapeghian JC, Verlangieri AJ. Effects of streptozotocin in the male guinea pig: a potential animal model for studying diabetes. *Life Sci* 1984; 35: 649-655.
29. Ar'Rajab A, Ahren B. Long term diabetogenic effect of streptozotocin in rats. *Pancreas* 1993; 8: 50-57.
30. Saini KS, Thompson C, Winterford CM, Walker NI, Cameron DP. Streptozotocin at low doses induces apoptosis and at high doses causes necrosis in a murine pancreatic B cell line, INS-1. *Biochem Mol Biol Int* 1996; 39: 1229-1236.
31. Dranginis A, Morley M, Nesbitt M, Rosenblum BB, Meisler MH. Independent regulation of nonallelic pancreatic amylase genes in diabetic mice. *J Biol Chem* 1984; 259: 12216-12219.
32. Frier BM, Saunders JHP, Wormsley KG, Bouchier IAD. Exocrine pancreatic function in juvenile-onset diabetes mellitus. *Gut* 1976; 17: 685-691.
33. Lankisch PG, Manthey G, Otto J, Koop H, Talaulicar M, William B et al. Exocrine pancreatic function in insulin-dependent diabetes mellitus. *Digestion* 1982; 25: 211-216.
34. Yajnik CS, Sahasrabudhe RA, Naik SS, Katrak A, Shelgikar KM, Kanitkar SV et al. Exocrine pancreatic function (serum immunoreactive trypsin, fecal chymotrypsin, and pancreatic isoamylase) in Indian diabetics. *Pancreas* 1990; 6: 631-638.
35. Semakula C, Vandewalle CL, Van Schravendijk CF, Sodoyez JC, Schuit FC, Foriers A et al. Abnormal circulating pancreatic enzyme activities in more than twenty-five percent of recent-onset insulin-dependent diabetic patients: association of hyperlipasemia with high-titer islet cell antibodies. Belgian Diabetes Registry. *Pancreas* 1996; 12: 321-333.
36. Duan RD, Wicker C, Erlanson-Albertsson C. Effect of insulin on contents, secretion and synthesis of pancreatic lipase and colipase in rats. *Pancreas* 1991; 5: 595-602.
37. Duan RD, Erlanson-Albertsson C. The effect of pretranslational regulation on synthesis of pancreatic colipase in streptozotocin-induced diabetes in rats. *Pancreas* 1992; 7: 465-471.
38. Ohashi N. Pancreatic regeneration after major pancreatectomy and effect of insulin administration in dogs. *Nippon Geka Gakkai Zasshi* 1993; 94: 480-493.
39. O'Reilly LA, Gu D, Sarventnick N, Edlund H, Phillips JM, Fulford T et al. Alpha-cell neogenesis in an animal model of IDDM. *Diabetes* 1997; 46: 599-606.