

Successful pregnancy in a patient with Takayasu's arteritis

Aisha A. Al-Ghamdi, Arab/Saudi Board (IntMed), FACP.

ABSTRACT

This report describes a case of Takayasu's arteritis in a 19-year-old Palestinian female. She conceived after diagnosis. Her pregnancy was complicated by uncontrolled hypertension, which was not associated with other markers of disease activity. Despite aggressive medical treatment, cesarean section had to be carried out at 34 weeks of pregnancy because of uncontrolled hypertension. A live fetus was borne, and her blood pressure was subsequently controlled with a single antihypertensive agent.

Saudi Med J 2003; Vol. 24 (11): 1250-1253

Takayasu's arteritis (TA) is a rare chronic vasculitis of unknown etiology. Both human leukocyte antigen (HLA)-BW52 and HLA-B39.2 were found with increased frequency in patients with TA suggesting an immunogenetic association.¹ It has variable geographical distribution with the greatest prevalence in Asians. Women are affected in 80-90% of cases with age of onset usually between 10-40 years.² The aorta and its primary branches are affected in 50% of cases.³ The following is a case presentation of Takayasu's arteritis admitted to King Abdul-Aziz University Hospital (KAUH), Jeddah, Kingdom of Saudi Arabia with positive family history and uncontrolled blood pressure during pregnancy.

Case Report. A 19-year-old Palestinian female with a 3-month history of hypertension on atenolol (100mg/day), presented to KAUH emergency department in January 2000 complaining of headache, fatigability, dyspnea, palpitations and hematuria. She gave a history of myalgia and arthralgia. There was no history of fever, cough, hemoptysis, weight loss, jaw pain or claudication, skin rash, and limb claudication.

Her father was diagnosed to have TA 15 years before. Upon examination, she was afebrile, tachycardic with a heart rate of 100 beats per minute, and tachypneic with a respiratory rate of 20 breaths per minute. Her blood pressure (BP) was high measuring 160/90 mm Hg (left arm), 170/100 mm Hg (right arm), with weak radial and brachial pulses. She was pale in mild respiratory distress with bilateral basal crackles, gallop rhythm and mild lower limb edema. There were no audible murmurs. No bruits were detected over the entire length of the aorta, its major branches, and the renal arteries. There were no skin rashes, oral ulcers, alopecia, active arthritis, or eye redness. Abdominal and central nervous system examinations were normal. Investigations revealed microcytic hypochromic anemia, hemoglobin 7.5 mg/dl (normal 12-16g/dl), high erythrocyte sedimentation rate (ESR) 90 mm/hour, creatinine 213 mmol/l (normal 40-120 mmol/l) with normal electrolytes, high C-reactive proteins (CRP) 52 mg/l (normal 0-5 mg/l). Antinuclear antibodies (ANA), double-stranded DNA, anti-cardiolipin antibodies, and anti-neutrophil cytoplasmic antibodies (ANCA) were negative.

From the Department of Medicine, King Abdul-Aziz University Hospital, Jeddah, Kingdom of Saudi Arabia.

Received 18th May 2003. Accepted for publication in final form 10th August 2003.

Address correspondence and reprint request to: Dr. Aisha Al-Ghamdi, Department of Medicine, King Abdul-Aziz University Hospital, PO Box 30598, Jeddah 21487, Kingdom of Saudi Arabia. Fax: +966 (2) 6298807. E-mail: aalghamdius@yahoo.com

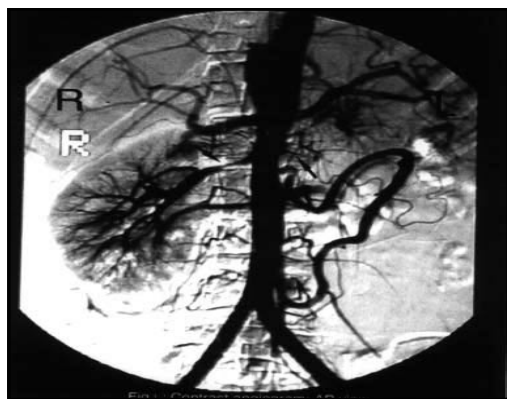


Figure 1 - Contrast angiogram confirming the presence of narrowing of the abdominal aorta and bilateral renal artery stenosis.

Complements were normal; C3 0.83g/l (normal 0.75-1.65g/l) and C4 0.2g/l (normal 0.20-0.60g/l), urinary protein was 0.28 g per 24 hours (normal 0.1-0.18 g/24 hours) with a normal creatinine clearance 90 ml/min (normal 80-140 ml/min). Urinary vanillylmandelic acid was normal. Chest x-ray showed pulmonary congestion. Echocardiogram revealed mild left ventricular hypertrophy, diastolic dysfunction with distended descending aorta. Abdominal ultrasound was normal. Renogram (^{99m}Tc diethylene-triaminepentaacetic acid) showed impairment in renal functions with calculated glomerular filtration rate 27ml/min with contribution of 15% by the left kidney and 85% by the right kidney. Radionuclide angiogram (^{99m}Tc dimercaptosuccinic acid) showed segmental narrowing of abdominal aorta with impaired perfusion of kidneys more prominent on the left side. Contrast angiogram confirmed the presence of narrowing of the abdominal aorta and bilateral renal artery stenosis (**Figure 1**). Diagnosis of TA was made. Amlodipine (5mg increased to 10 mg/day) was added to control her BP and she was also started on prednisone 50 mg/day. Her BP remained persistently high and 4 days later she developed generalized tonic clonic convulsions controlled with diazepam. Bilateral cerebellar infarctions were detected by computerized tomography of brain. Pulse steroid with methyl prednisone (250 mg once a day) was started for 3 days together with weekly methotrexate (7.5 mg) followed by the previous prednisone dose. She was discharged 2 weeks later on prednisone, methotrexate, atenolol and amlodipine with no residual neurological deficit. Her BP was 130/90 mm Hg and creatinine was 148 mmol/l. She was assessed by a vascular surgeon for possible angioplasty, who decided to avoid surgical intervention since she was responding to medical treatment. During her follow up immunosuppressive medications were discontinued and her BP was controlled on atenolol and amlodipine until she became pregnant in February 2002. She presented at

16 weeks gestation complaining of headache. Her blood pressure was found to be high 160-170/90-100 mm Hg in spite of 2 antihypertensive medications. There were no signs of heart failure, no hematuria, and no focal neurological deficit. Investigations did not show any significant proteinuria. Her ESR, CRP, complements and ANCA were normal. Since her disease was inactive during this presentation and throughout her pregnancy, immunosuppressive therapy was not required. Several antihypertensive medications were tried including hydralazine, methyldopa and labetalol with persistently high BP (160-170/90-110 mm Hg). Elective cesarean section was carried out for uncontrolled hypertension at 34 weeks of gestation. A live male infant was delivered. Her BP was subsequently controlled with atenolol 50 mg/day.

Discussion. Takayasu's arteritis (TA) was first described in 1908.⁴ It is an obliterative vasculitis affecting medium and large sized arteries. Affected arteries show a pan-arteritis, which may be active with intimal smooth muscle proliferation and cellular infiltrates, fibrotic or mixed changes.⁵ It has a genetic predisposition with a variable geographic distribution. The above patient was Palestinian and her father has the same disease suggesting familial aggregation. Unfortunately, they did not have HLA typing, and it has been reported that certain HLA types may be predominant among patients with TA in different countries. Only few cases have been reported from our hospital in keeping with the low incident rates. In 1993, 10 cases were reported from KAUH, 2 patients were also Palestinians and 7 patients were female favoring the reported international predominance of TA among females.⁶

Clinical manifestation may be systemic (prepulseless) or related to the underlying vascular involvement.⁷ Myalgia, fatigue and arthralgia were among the systemic manifestations of the above patient which may be present in 50-66% of cases. Other manifestations may include loss of weight, headache, low-grade fever and epistaxis. The vessels involved in the inflammatory process include the aorta, pulmonary, vertebral, carotid, subclavian, ulnar, radial, celiac, mesenteric, renal and common iliac arteries which may result in end-organ ischemia.⁸ Classification criteria were established by the American College of Rheumatology for TA that helps in the diagnosis.⁹ At least 3 of these 6 criteria should be present. Our had 4 criteria including age at onset <40 years (19 years), difference of at least 10 mm Hg in systolic BP between the arms (160/90 versus 170/100 mm Hg in left and right arm), decreased pulsation in the brachial arteries and narrowing of the aorta or its primary branches (renal arteries). This renders TA diagnosis in this patient most likely with a sensitivity of 90.5% and specificity 97.8%.⁹

Claudication of extremities and bruit over subclavian arteries or aorta were the 2 other criteria that were absent. Systemic hypertension was the most important finding in this patient (which has been found in 50-60% of patients with TA) which could be due to aortic narrowing and renal artery stenosis. Increased blood pressure can also occur in patients with TA even with the absence of renal artery stenosis probably due to loss of vascular compliance, dysfunctional baroreceptors and elevated renin levels.¹⁰ In patients with involvement of upper limb vessels, blood pressure readings may be low and leg blood pressure should be measured instead. Impaired renal function was attributed to renal ischemia, glomerulonephritis, or both. Hematuria is an uncommon feature in patients with TA. however, in this patient it could be related to glomerulonephritis where focal segmental mesangial proliferative glomerulonephritis has been reported as a cause in few patients with TA.^{11,12} Kidney biopsy was not carried out to confirm this, because her renal function improved and hematuria resolved following treatment.

Different systems could be involved including neurological, ocular, cardiopulmonary, gastrointestinal system and the skin, which are due to hypoperfusion of the affected organ. Our patient had symptoms of congestive heart failure and cerebrovascular accident. The frequency of heart failure is 35% and cerebrovascular accident is 7% in patients with TA.^{10,13} Takayasu's arteritis may also mimic idiopathic inflammatory diseases or infections such as tuberculosis.¹⁴ The association of TA and tuberculosis has been controversial.¹⁵⁻¹⁷ This patient neither had clinical symptoms of tuberculosis nor contact with other active tuberculosis patients.

Several biochemical laboratory tests indicating underlying active inflammatory pathology may be present during active disease which may disappear when the disease activity declines.¹⁸ This patient had anemia probably due to hematuria or chronic illness, together with increased ESR and CRP. These tests were normal after starting treatment and were persistently normal during her follow up and pregnancy, which may suggest a decrease in disease activity. Her ANA was negative in consistence with the absence of detectable autoantibodies in TA as compared to other vasculitides.¹⁹

Angiographic findings in patients with TA included areas of stenosis and aneurysm formation. The aortic arch is most commonly affected, however in this patient the descending aorta and bilateral renal arteries were involved which has been reported in >67% of patients with TA.⁸ Takayasu's arteritis commonly affects females in the child bearing period; several studies on fertility and outcome of pregnancy have been reported. Fertility is usually unaffected, and a few cases were first diagnosed during pregnancy. Increase of blood pressure, pre-eclampsia, congestive heart failure, aortic incompetence and low birth weight were among frequently observed complications,

though disease activity is unaffected by pregnancy.²⁰⁻²² Pregnancy should be considered only during periods of remission. The major problem encountered with our patient was uncontrolled blood pressure with no signs of pre-eclampsia. Elective cesarean section at 34 weeks was performed. Her blood pressure was controlled in the second-day post partum; her baby was 1.5 kg and nursed in the Neonatal Unit for 2 weeks. He was discharged one week later in a good condition.

Treatment available for patients with TA includes immunosuppression, angioplasty and by pass grafts. Corticosteroids are the corner stone of medical treatment.²³ Methotrexate in combination with corticosteroids improves remission and decreases relapse rates.^{24,25} Other immunosuppressive drugs that may be beneficial include cyclophosphamide, mycophenolate mofetil and cyclosporine.²⁶ The above patient was prescribed immunosuppressive medications which included corticosteroids and methotrexate. Prior to starting therapy she was informed of the drugs' side effects and advised to avoid pregnancy until her disease was under control. She had an adequate response to treatment. Methotrexate was stopped 4 months later and prednisone was gradually tapered off and discontinued after one year. Prednisone was not restarted during pregnancy since there was no evidence of active underlying process. Her disease remained in remission after delivery with adequate control of blood pressure. She was advised to avoid estrogen containing oral contraceptives and to use progesterone contraceptives,¹⁰ if she intends to control conception in the future.

In conclusion, TA in pregnancy can result in exacerbation of hypertension. It requires close and collaborative management between the internist, obstetrician and pediatrician to achieve good fetal and maternal outcome.

References

1. Ishohjisa I, Numano F, Maezawa H, Sasazuk P. HLA-BW52 in Takayasu's disease. *Tissue Antigens* 1979; 12: 246-248.
2. Lupi-Herrera E, Sanchez-Torres G, Marcushamer J, Misierta J, Horwitz S, Vela JE. Takayasu's arteritis. Clinical study of 107 cases. *Am Heart J* 1977; 93: 94-103.
3. Hata A, Noda M, Moriwaki R, Numano F. Angiographic Findings of Takayasu's Arteritis: New classification. *Int J Cardiol* 1997; 54 (Suppl): 155.
4. Roberts WC, MacGregor RR, DeBlanc HJ. The prepulseless phase of pulseless disease or pulseless disease with pulses. *Am J Med* 1969; 46: 313-324.
5. Sharma BK, Jain S, Radotra BD. An autopsy study of Takayasu's arteritis in India. *Int J Cardiol* 1998; 66: S85-S90.
6. Saleh TR, Al-Dabbagh A, Al-Prince H, Al-Zahrani HA. Takayasu's Arteritis: Angiographic and Duplex Finding. *Saudi Heart Journal* 1993; 4: 63-69.
7. Fraga A, Mintz G, Valle L, Flores-Izquierdo G. Takayasu's arteritis: frequency of systemic manifestations and favorable response to maintenance therapy with adreno-corticosteroids. *Arthritis Rheum* 1972; 15: 617-624.
8. Fraga A, Medina F. Takayasu's Arteritis. *Curr Rheumatol Rep* 2002; 4: 30-38.

9. Arend WP, Michel BA, Bloch DA, Hunder GG, Calabrese LH, Edworthy SM, et al. The American College of Rheumatology 1990 criteria for the classification of Takayasu's arteritis. *Arthritis Rheum* 1990; 33: 1129-1134.
10. Chugh KS, Sakhuja V. Takayasu's Arteritis as a cause of Renovascular Hypertension in Asian Countries. *Am J Nephrol* 1992; 12: 1-8.
11. Lai KN, Chan KW, Ho CP. Glomerulonephritis associated with Takayasu's arteritis. Report of 3 cases and review of the literature. *Am J Kidney Dis* 1986; 7: 197-204.
12. Yoshikawa Y, Truong LD, Matioli CA, Lederer E. Membranoproliferative glomerulonephritis in Takayasu's arteritis. *Am J Nephrol* 1988; 8: 240-244.
13. Rizzi R, Bruno S, Stellacci C, Dammacco R. Takayasu's arteritis: a cell mediated large-vessel vasculitis. *Int J Clin Lab Res* 1999; 29: 8-13.
14. Hoffman GS. Takayasu's arteritis: lessons from the American National Institutes of Health experience. *Int J Cardiol* 1996; 54: 99-102.
15. Pantell R, Coodman B. Takayasu's arteritis. The relationship with tuberculosis. *Pediatrics* 1981; 67: 84-88.
16. Hall S, Barr W, Lie JT, Stanson AW, Kasmier FJ, Hunder GG. Takayasu's arteritis. A study of 32 North American patients. *Medicine (Baltimore)* 1985; 64: 89.
17. Kinare S. Aortitis in early life in India and its association with tuberculosis. *J Pathol* 1970; 100: 69-76.
18. Hoffman GS, Ahmed AE. Surrogate markers of disease activity in patients with Takayasu's arteritis. A preliminary report from The International Network for the Study of the Systemic Vasculitides (INSSYS). *Int J Cardiol* 1998; 66: S191-S194.
19. Eichhorn J, Sima D, Thiele B, Lindschau C, Turowski A, Schmidt H et al. Anti-endothelial cell antibodies in Takayasu's arteritis. *Circulation* 1996; 94: 2396-2401.
20. Raliton A, Allen DG. Takayasu's arteritis in pregnancy. A report of 4 cases. *S Afr Med J* 1988; 73: 123.
21. Matsumura A, Moriwaki R, Numano F. Pregnancy in Takayasu's arteritis from the view of internal medicine. *Heart Vessels* 1992; 7: 120-124.
22. Bassa A, Desai DK, Moodley J. Takayasu's disease and pregnancy: Three case studies and a review of the literature. *S Afr Med J* 1995; 85: 107-112.
23. Kerr GS. Takayasu's arteritis. *Rheum Dis Clin North Am* 1995; 21: 1041-1058.
24. Hoffman GS, Leavitt RY, Kerr GS, Rottem M, Sneller MC, Fanci AS. Treatment of glucocorticoid-resistant or relapsing Takayasu's arteritis with methotrexate. *Arthritis Rheum* 1994; 37: 578-582.
25. Mevorach D, Leibowitz G, Brezis M, Raz E. Introduction of remission in a patient with Takayasu's arteritis by low dose pulses of methotrexate. *Ann Rheum Dis* 1992; 51: 904-905.
26. Daina E, Schieppati A, Remuzzi G. Mycophenolate mofetil for the treatment of Takayasu's arteritis: report of 3 cases. *Ann Intern Med* 1999; 130: 422-426.