

Pelvic hematoma resulting in obstructive uropathy

*Ahmed A. Abdulwahab, MGO, ABOG, Salah Hassan, MD, FRCS,
Lulu Al-Nuaim, MRCOG, ABOG, Rabie Abdel Halim, MD, FRCS.*

ABSTRACT

The use of anticoagulants, for whatever indication, may carry a high risk of hematoma formation following surgery. Obstructive uropathy is a very rare but possible example of complication secondary to an extensive pelvic hematoma. We describe a case of a patient with rheumatic heart disease and aortic valve replacement, who developed a massive postoperative pelvic hematoma following bilateral tubal ligation, resulting in bilateral ureteric obstructions. This was treated with bilateral ureteric stent through cystoscopy.

Saudi Med J 2003; Vol. 24 (11): 1254-1255

Sterilization of a female patient with rheumatic heart disease and valve replacement, who are on anticoagulant remain one of the most popular procedure due to the potential risks of other contraceptive methods, for example oral contraceptive pills and intra-uterine contraceptive device. However, surgery still carries the risk of major bleeding or hematoma formation, which can be big enough to result in a significant compression to any nearby organs.

Case Report. A 35-year-old woman, para 5 + 0 was referred for sterilization. She has a metallic aortic valve and repair of other valves, 3 years earlier. She was on daily warfarin, digoxin, frusemide and captopril. She used various forms of contraception. Apart from an irregular pulse, jugular venous pressure of 4 cm, pan-systolic murmur in the tricuspid area and an enlarged liver of 4 cm below the costal margin, she was normal. Her hemoglobin (Hb), blood biochemistry and coagulation profiles were normal. Warfarin was discontinued 72 hours before surgery. A loading dose

and intravenous heparin infusion was started, which was stopped 6 hours prior the surgery. Prophylactic antibiotics were given before surgery. Bilateral tubal ligation was performed using Pomeroy's method and Hulka clips. The recovery was uneventful. Heparin 1000 IU/hour intravenous was resumed 6 hours later. Warfarin 10 mg was started on the second day, and adjusted according to activated partial thromboplastin time (APTT). On the fifth day however, she complained of lower abdominal pain and inability to void. On examination, there was a huge tender pelvic-abdominal mass reaching the umbilicus. Foley's catheter was inserted but the bladder was empty. Abdomino-pelvic ultrasound verified the diagnosis of pelvic hematoma. Serum creatinine was 152 $\mu\text{mol/L}$ (range 62-115), Hb was 7 gm/dl, white blood count was 18,230 ($4-11 \times 10^9/\text{L}$) and hematocrit was 18.2 (37-47%). Coagulation profile showed APTT 76 (2-39) seconds, prothrombin time (PT) 28.2 (9.5 - 13.5) seconds and international normalized ratio 2.5 (0.8-1.3). Anticoagulants were discontinued, and patient was transferred to Surgical intensive care

From the Department of Obstetrics and Gynecology (Abdulwahab, Al-Nuaim) and the Department of Urology (Abdel Halim, Hassan), King Khalid University Hospital, Riyadh, Kingdom of Saudi Arabia.

Received 30th March 2003. Accepted for publication in final form 5th July 2003.

Address correspondence and reprint request to: Dr. Ahmed Abdulwahab, Department of Obstetrics and Gynecology, King Khalid University Hospital, PO Box 7805, Riyadh 11472, Kingdom of Saudi Arabia. Tel. +966 (1) 4670818.

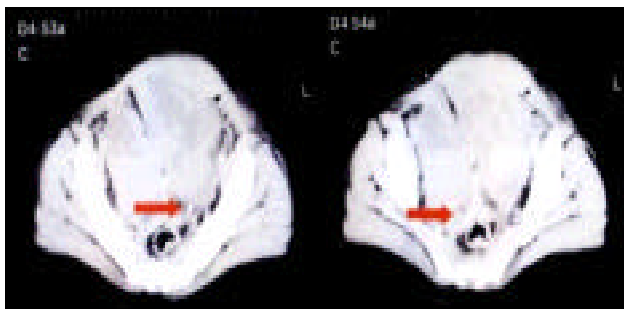


Figure 1 - Computerized tomography showing the heterogenous mass, (hematoma) on its initial stage. White spot (arrow) on both shows the displacement of both ureters.

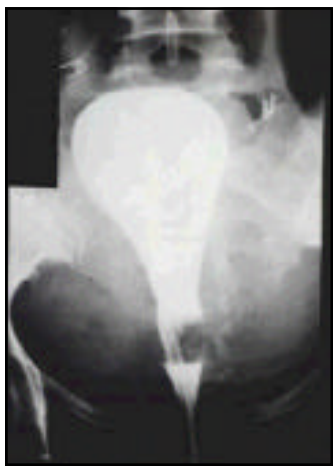

Figure 2 - Cystogram showing the compressed and elongated bladder for approximately 15 cm.

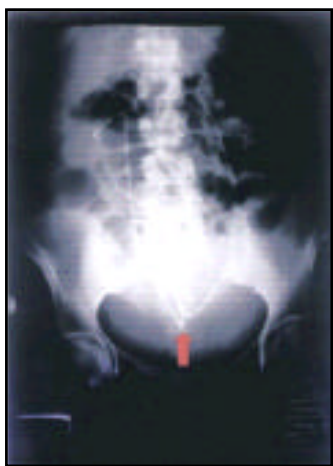

Figure 3 - Bilateral double J ureteric stent with acute kinking of the stent.

unit. Central venous pressure line was inserted and 2 units of packed cells were transfused. At cystoscopy revealed an elongated, compressed urinary bladder. Computerized tomography (CT) scan of abdomen and pelvis revealed a hematoma pushing the bladder posteriorly, with mild dilatation of the right kidney and ureter (**Figure 1**). Cystogram revealed, the bladder was severely compressed and elongated for approximately 15 cm (**Figure 2**). Bilateral double-J ureteric stent, (28 cm 8F) were inserted with difficulty, followed by 20F Foley's catheter (**Figure 3**). A scanty concentrated, blood-stained urine was drained. The urine increases and cleared gradually. Serum creatinine became normal after 24 hours. Heparin S/C was resumed followed by Warfarin, both adjusted, according to coagulation profile. Heparin was stopped after 8 days. Foley's catheter was removed on the 14th day. She was discharged in satisfactory condition with the ureteric stents. She remained well 4 weeks later. On the 14th week, a repeat CT scan revealed a marked reduction in the size of the hematoma. Ureteric stents were removed after 17 weeks.

Discussion. Hematomas are common in patients who are on combined anticoagulants,¹ when subjected to surgery. Intense movement can alter the intra-pelvic pressure, and initiate bleeding. Furthermore, captopril may predispose to bleeding. Massive retroperitoneal bleeding can occlude the intramural part of the ureters.^{2,3} Obstruction is caused by the upward displacement of the bladder, leading to acute kinking of the ureters in the juxta mural part. Sepsis can complicate pelvic hematomas leading to pulmonary embolism, adult respiratory distress syndrome and renal failure. Antibiotic therapy should thus be instituted early. Bilateral ureteric stenting in patients with extensive pelvic hematomas is a minimally invasive endoscopic technique. The stents can stay in-situ for up to 6 months, can be changed or removed anytime, and need no special care. The risk of infection to urinary tract, or the hematoma is small compared with open surgery or bilateral percutaneous nephrostomies.

Acknowledgment. We are grateful to and would like to thank both Professor Babatunde Adelus, Dr. Bengt Sporrang and Professor Kuofi for their helpful comments.

References

1. Fejgin MD, Lourhood DL. Low molecular weight heparins and their use in obstetrics and gynecology. *Obstet Gynecol Surv* 1994; 49: 424-432.
2. Hotker U, Rommens PM. Postrenal anuria in pelvic or acetabular injury. A report of three case. *J Trauma* 1996; 916-919.
3. Flint P, Charles FA. Pelvic fracture complicated by bilateral ureteral obstruction. Case report. *J Trauma* 1994; 36: 285-287.