

The pathological expressions of Brunner's gland hyperplasia into adenoma and hamartoma

Fayek A. Al-Hilli, D.Path, PhD(Path), Ashok K. Malik, MD, FRCPath, Sara M. George, MD.

ABSTRACT

The terms Brunner's gland adenoma and hamartoma are 2 pathological expressions of hyperplasia of these glands. We report 3 patients and review the recent literature to support our hypothesis of common pathology. Awareness of the existence and character of Brunner's gland lesions will increase the possibility of their accurate diagnosis.

Saudi Med J 2003; Vol. 24 (11): 1256-1260

Much of the confusion observed in the pathology of Brunner's gland (BG) lesions relates to the attempts to separate the term hyperplasia from the closely associated adenomas and hamartomas (Brunneroma) of these glands as well as the etiology of each of these conditions.¹⁻⁵ We believe that the terms adenoma and hamartomas represent 2 different pathological expression of hyperplasia. We report 3 patients of Brunner's gland hyperplasia (BGH) diagnosed at Salmaniya Medical Complex, Bahrain between 2001-2002. Two patients were presented with melena and the third with perforated prepyloric ulcer. We have reviewed the recent literature pertinent to the anatomy and pathophysiology of the BG to support our hypothesis. Clinical presentation, diagnosis and treatment of BG lesions will also be reviewed.

Case Reports. Patient One. A 56-year-old man with end-stage renal failure due to diabetic nephropathy underwent cadaver renal transplantation in July 2001. He also had hypertension and diabetic

neuropathy and retinopathy. He had been a chronic smoker for 15 years. After the transplant he developed acute tubular necrosis with delayed graft function. He was on cyclosporine, prednisolone and mycophenolate mofetil as immunosuppressive drugs besides antihypertensives, H₂ receptor blocker, vitamin D, calcium carbonate, ferrous sulphate, erythropoietin, and insulin. He recovered from the graft dysfunction with blood urea of 15.1 mmol/L (NR 3.0-7.8 mmol/L), serum creatinine of 123 μ mol/L (NR 60-142 μ mol/L). In December 2001 he was admitted for evaluation of renal dysfunction and anemia. He had no fever, dysuria, abdominal pain, hematemesis or melena. Physical examination showed a normotensive individual with pallor and mild pedal edema. There was tenderness in the graft region. Ultrasonography of the graft showed hydronephrosis. The laboratory investigations were as follows: hemoglobin (Hb) 5.9 g/dL with low red cell indices, blood urea 20.8 mmol/L, serum creatinine 197 μ mol/L, and normal levels of vitamin B12 and folate. Percutaneous

From the Department of Pathology, Salmaniya Medical Complex, Bahrain.

Received 18th May 2003. Accepted for publication in final form 9th August 2003.

Address correspondence and reprint request to: Dr. Fayek A. Al-Hilli, Department of Pathology, Salmaniya Medical Complex, PO Box 12, Bahrain. Tel. +973 279513. Fax. +973 279649.

nephrostomy drained large amount of urine. There was steady fall in the urea and creatinine levels but no improvement in Hb readings. Stools for occult blood was positive on three successive days. Endoscopy showed gastric antral erosions and a large polyp >2 cm in the second part of the duodenum. After packed red blood cells transfusion, which raised the Hb level to 9.0 g/L, an endoscopic polypectomy was performed. Histology of the polyp showed Brunner's gland hyperplasia. Following the procedure he had no further drop in Hb level, which remained above 10.0 g/L. His stools occult blood remained negative.

Patient 2. An 81-year-old Bahraini diabetic man on insulin therapy was admitted on November 2001 with intertrochanteric fracture of left femur for which he had a dynamic hip screw placement. In the same month following surgery, he developed thrombosis of left femoral vein for which he received oral anticoagulant therapy. Following this, he developed rectal bleeding and colonoscopy showed superficial rectal erosions. There were no masses and no biopsy taken as he had abnormal coagulation profile due to anticoagulant therapy. He was given 4 units of packed red blood cells transfusion for restitution of Hb due to blood loss. Subsequently, the anticoagulant was withdrawn and inferior vena cava filter was placed to prevent pulmonary embolism. He was readmitted on January 2002 with history of right lower limb edema and oliguria of one day duration. There was no fever, vomiting, diarrhea, dysuria or hematuria. Physical examination showed afebrile, conscious, moderately dehydrated patient with no dyspnea. There was mild swelling of the left lower limb and gross swelling of the right lower limb. The rest of physical examination was unremarkable. On Doppler ultrasonography, the cause of the right limb swelling was found to be a new venous thrombus. The Hb level was 10.5 gm/dl with normal total and differential white cell counts. The platelet count, bleeding time and activated partial thromboplastin time and iron studies were within normal limits. Blood urea was 14.8 mmol/L and serum creatinine was 172 μ mol/L. Following hydration, the serum creatinine dropped to 18 μ mol/L. Urine examination showed many red and white blood cells. While in the hospital he developed melena. His Hb dropped to 7.7 gm/L and the stool examination for occult blood was positive. Upper gastrointestinal endoscopy showed sliding hiatus hernia with ulcerations in the middle and lower esophagus and a polyp in the first part of duodenum measuring 1.5 cm in diameter with a small stalk. Clinical diagnosis of Grade III esophagitis and a Brunner's gland adenoma of the duodenum were made. He was given ranitidine and antacids, and after correcting the anemia with packed red cell transfusion, endoscopic polypectomy was carried out. The lesion was removed in 2 pieces and the histopathological examination confirmed the clinical diagnosis of BGH with surface erosion and no

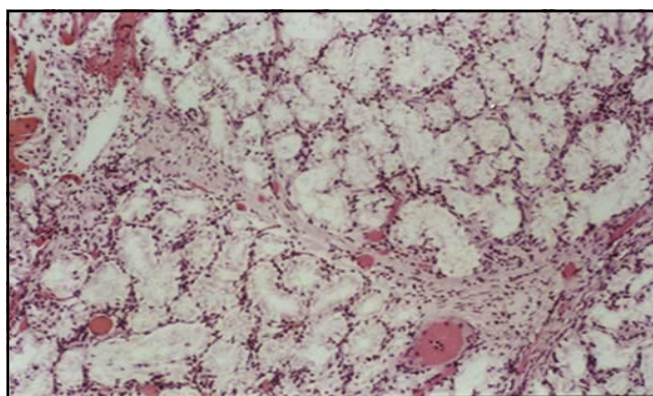


Figure 1 - Micrograph shows lobular proliferation of hyperplastic Brunner's glands and patchy stromal congestion. (Hematoxylin & Eosin x 100).

atypia (**Figure 1**). There was no recurrence of melena and Hb rose to 10 gm/dl.

Patient 3. A 57-year-old Bahrain male presented to the emergency room on November 2002 with history of abdominal pain of 3 days duration. He was in shock with acute abdomen and was diagnosed with a perforated viscus. He is a known case of chronic obstructive pulmonary disease and peripheral arterial disease with no history of peptic ulcer disease. The patient underwent laparotomy and was found to have a perforated prepyloric ulcer. Resection and anastomosis was carried out and a biopsy was taken from the ulcer. The histological section showed BGH and features of perforated prepyloric ulcer. During the postoperative period the patient went into septic shock and developed coma, acute respiratory distress syndrome, toxic myocarditis and acute renal tubular necrosis, which necessitated daily dialysis. He underwent tracheostomy for the respiratory difficulty and was put on controlled mechanical ventilation. Neurological assessment confirmed multiple lacunar brain infarcts, which were responsible for the comatose state of the patient. One month after admission and while in the hospital he developed gangrene of the right lower leg. Arterial Doppler studies revealed complete absence of blood flow in the popliteal arteries of both limb and the vessels distal to this. There were also atheromatous plaques in both femoral arteries. On January 2003 he underwent amputation of the right lower limb. At present, the patient is on controlled ventilation and daily dialysis.

Discussion. Brunner's gland is found exclusively between the pyloric ring and the papilla of Vater and rarely extends to the proximal jejunum.^{4,6,7} They secrete alkaline fluid composed of viscous mucin, whose main function is to protect the duodenal epithelium against the damaging effect of the gastric acid chyme.^{2,5,8,9} The glands make up to 55% of the

total area of the duodenum in infants but fall to 35% in persons >50-year-old.⁸ The reason for this involutional change is not known. The pathogenesis of BGH and its different expressions is not clearly understood but may be related to the excessive local irritation from the acidic gastric chyme, vagal stimuli, or from antral hormones not fully identified.^{6,9,10} Changes in the tone of lower esophageal sphincter and gastric emptying have also been implicated.¹¹ For these reasons, BGH occurred frequently in conditions associated with gastric hyperacidity and changes in gastric emptying such as esophagitis, hiatus hernia, gastritis, peptic ulcer, chronic pancreatitis, and renal insufficiency.^{2,11} Accordingly in the early stages when the pathology involves only a lobule of BG the lesion is small and may be focal, localized, solitary, nodular and sessile. Such small lesions <1 cm in diameter are asymptomatic. But in response to persistent gastric stimuli the lesion enlarges and involves more lobules. It becomes multifocal, multinodular, polypoid, pedunculated and prolapse into the duodenal lumen.^{3,5,12,13} These lesions are more than 1 cm in diameter and produce a variety of symptoms.^{7,14-19} Hyperplasia of the entire BG lobules will lead to the formation of diffuse and annular lesion infiltrating into the wall and circumference of the duodenum.¹⁹⁻²¹ It is worth noting that the confusing reports describing the gross morphology of the BG lesions as focal, multifocal, circumscribed nodular, multinodular, diffuse nodular, and circumferential represent the various stages of the development of BGH.^{3,5,6,11-13,15,18,19,21} It has been suggested that BG lesions <1 cm represent hyperplasia, whereas those >1 cm are called adenomas, or a hamartomas if these contain stromal elements.^{7,12,16,18} However, this categorization is not satisfactory since it applies to size rather than histological behavior. On the other hand, changes in size indicate progression of hyperplasia and do not imply neoplasia. Furthermore, an adenoma of any organ is made up of glandular structure lined by neoplastic cells, which stand in sharp distinction from normal glands. But in the case of BGH the lesion is made up of nodular proliferation of histologically normal branched acinotubular submucosal mucus secreting glands. In contrast to adenoma, BGH shows no atypia, pleomorphism, mitosis or even dysplastic changes to indicate its neoplastic nature. If BGH lesions were neoplastic (namely adenomas) then malignant transformation would have been very common occurrence since it is natural to assume that the long standing effect of gastric stimuli on these glands will not only lead to severe hyperplasia and dysplasia but also to oncogenesis noting that conditions associated with gastric hyperacidity are common worldwide. However, this is not the case since duodenal carcinomas are rare and the reported cases are probably primary duodenal adenocarcinoma or carcinoma arising from the BG rather than malignant transformation of BG adenoma.^{16,22}

Brunner's gland hyperplasia nodules with true neoplasm are also rare. Fujimaki et al¹⁷ demonstrated a focus of p53 positive atypical glands, which resembled the excretory ducts rather than the acinar cells of the glands indicating that some lesions may be neoplastic. But this finding needs to be substantiated since ductal element may be a primary BG lesion rather than secondary to gastric stimuli. An associated microcarcinoid is probably the only report associated with a true neoplasm.²³ But again, these are incidental findings of associated neoplastic foci unrelated to pathology of BG.

By definition, hamartoma is a localized disordered differentiation of tissues during embryonic development resulting in the formation of disorganized caricature of normal tissue. The suggestion that BGH is a hamartoma with predominance of BG elements is based on the observation that it contains stromal elements namely smooth muscle and adipose tissue and that it occurs in a region where hamartomas are common.^{1,3-5,12,18} We believe that lesion is not a hamartoma and we put forward the following arguments: 1. The presence of stromal elements within the BG nodules does not support their hamartomatous etiology since these structures are normal histologic components of the duodenal wall. It is expected that as the hyperplastic lobules enlarge, they disrupt and proliferate in between the muscle fibres and the serosal fat of the duodenum and thus appear in histology sections leading to misinterpretation of hamartoma. Nowhere in the literature are reports of other differentiated tissue elements found within the BGH nodules to qualify the terminology of hamartoma. 2. Bastounis et al⁵ have shown that continuity exist between the BGH nodules and adjacent normal BG pointing out that lesion is a nodular hyperplasia. 3. It has been reported that the size of BG 'hamartomatous polyps' regresses when antacid and antisecretory drugs were given.¹⁰ This means that the lesion is neither neoplastic nor hamartomatous but a hyperplastic condition in response to gastric hyperacidity and changes in gastric emptying. 4. If the BGH lesions are truly hamartomatous, then they should clinically present at an earlier life and not around the average age of 57.1-year-old.^{13,16,20} 5. The occurrence of BGH can be anywhere within the normal anatomic location of the BG. Why should a hamartoma become restricted to this region and occur only in conditions associated with gastric hyperacidity and changes in gastric emptying? 6. If hamartoma is to be considered, then the polypoid duodenal lesion may be part of other intestinal pathology such as Peutz-Jeghers syndrome and Juvenile Polyposis syndrome. But even in such cases the histological appearances of these lesion are different. The incidence of BG lesions received conflicting results in the literature because of the confusion related to the terminology used to describe these lesions, small number of patients or specimens studied, inconsistencies in the analysis of results,

inclusion of non-BG intestinal conditions in some reports, and differences in the correlation between morphological, endoscopic and radiologic findings.^{1-5,7,13,16,20,24,25} To demonstrate this confusing incidence it is worth noting that benign duodenal neoplasms were found to account for 0.008% of all surgical and autopsy tumor specimens and that 10.9% of all these neoplasms are BGH.^{20,24,25} Brunner's gland hyperplasia lesions also account for 6.9% of all duodenal inflammatory, hyperplastic and neoplastic polypoid lesions.²⁰ However, the true incidence of BGH is unknown since only symptomatic lesions are investigated and reported. Awareness of the existence of BG lesions will increase the possibility of accurate diagnosis. Brunner's gland hyperplasia is seen more in males than females and in all age groups from 13-86 years with most of the patients in their fourth to sixth decade of life and with an average age of 57.1 years.^{13,16,20} All the patients in this study were males >56 years. This pattern corresponds with higher incidence of gastric hyperacidity associated conditions thus pointing to the relationship between these conditions and the pathogenesis of BGH.

Brunner's gland hyperplasia lesions, similar to any other duodenal bulb lesions, will only become clinically relevant when they attain a critical size to either erode into the duodenum mucosa causing bleeding or infiltrate the circumference of the duodenal wall leading to gastric outlet obstruction.^{7,9,14-19} Accordingly, the symptomatology is non-specific and the lesions may erroneously be diagnosed as malignant.^{6,9} The presentation varies from asymptomatic to abdominal pain, vomiting, nausea, dyspepsia, weight loss and gastrointestinal hemorrhage presenting as melena, hematemesis or even severe anemia leading to cardiac failure.^{7,14,18,19,26} However, not all large BGH lesions are obstructive and the first clinical sign is bleeding.¹⁴ The melena in the case 2 of the present report may have been present before the endoscopic diagnosis of BGH but became clinically noticeable as a complication of the anticoagulant therapy prescribed for his DVT. He also had hiatus hernia, gastro-esophageal reflux and ulcerative esophagitis indicating the role of lower esophageal sphincter and changes in gastric emptying in the pathogenesis of BGH.¹¹ Uncommon clinical manifestations of duodenal bulb lesions include abdominal mass, pancreatitis, biliary obstruction, duodenojejunal intussusception and so forth.^{18,27,28}

The diagnosis of BGH lesions is made by endoscopy which, not only provides a chance for biopsy taking and total excision, but also the discovery of any associated pathology.^{3,12,16} Endoscopic ultrasound is also useful to detect mucosal involvement and help to differentiate between intraluminal and extraluminal growth.^{7,18} The results of these diagnostic modalities should be correlated with clinical and histopathological findings.³ The differential diagnosis of BGH lesions include other duodenal bulb lesions such as adenoma

and carcinoma of the superficial duodenal mucosal glands, periampullary tumors, neuroendocrine tumors, leiomyoma, neurogenic tumors, myoepithelial hamartomas, aberrant pancreatic tissue, heterogenic gastric mucosa, regenerative duodenal mucosa, prolapsed pyloric mucosa, antegrade intussusception of pedunculated antral polyps, duodenitis, hyperplastic polyps, mucosal polyps of Peutz-Jeghers syndrome, Juvenile Polyposis syndrome, lymphadenopathy, and so forth.^{3,7,16,25} The exact categorization of any of these conditions can only be made after examination of endoscopic biopsy. Furthermore, because of the association of extra-duodenal intestinal lesions of some of these conditions, a "top-and-tail" endoscopy should be performed. The treatment of small BGH lesions is by endoscopic excision as carried out in 2 cases of the present report.^{3,6,7,9,12,14} Large lesions inaccessible to the endoscopic snare, can be excised by laparoscopy.²⁹ But larger obstructive or bleeding lesions require open surgical resection.^{5,7,9,14,15} Postoperative regimen of antacids and H₂ antagonists is recommended.^{9,10} Furthermore, since the BG lesion may be associated with other lower esophageal and gastric pathology, attention to treat these conditions must also be addressed.

References

1. Rufenacht H, Kasper M, Heiz PU, Streule K, Harder F. "Brunneroma". Hamartoma or tumor? *Pathol Res Pract* 1986; 181: 107-109.
2. Farkas IE, Gero G. The role of Brunner's gland in the mucosal protection of the proximal part of the duodenum. *Acta Physiol Hung* 1989; 73: 257-260.
3. Merine D, Jones B, Ghahremani GG, Hamilton SR, Bayless TM. Hyperplasia of Brunner's glands: the spectrum of its radiographic manifestations. *Gastrointest Radiol* 1991; 16: 104-108.
4. Levine JA, Burgart LJ, Batts KP, Wang KK. Brunner's gland hamartoma: clinical presentation and pathological features of 27 cases. *Am J Gastroenterol* 1995; 90: 290-294.
5. Bastounis E, Pikoulis E, Leppaniemi A, Tsetis D, Tsetis AA. Polypoid hamartoma of Brunner's gland of the duodenum. *Dig Surg* 1999; 16: 431-433.
6. Peison B, Benisch B. Brunner's gland adenoma of the duodenal bulb. *Am J Gastroenterol* 1982; 77: 276-278.
7. Chong KC, Cheah WK, Lenzi JE, Goh PM. Benign duodenal tumours. *Hepatogastroenterology* 2000; 47: 1298-1300.
8. Kaplan EL, Dyson WL, Fitts WT. Hyperplasia of Brunner's glands of the duodenum. *Surg Gynecol Obstet* 1968; 126: 371-375.
9. Peetz ME, Moseley HS. Brunner's gland hyperplasia. *Am Surg* 1989; 55: 474-477.
10. De Angelis G, Villanacci V, Lovotti D, Gianni E, Mazzi A, Buonocore M, et al. Hamartomatous polyps of Brunner's gland. Presentation of 2 cases. Review of literature. *Minerva Chir* 1989; 44: 1761-1766.
11. Cavallaro G, Albanese V, Taranto F, Pustorino S, Baldari S. Brunner's adenoma, oesophageal reflux and gastric ulcer. A case report. *Chir Ital* 2000; 52: 703-706.
12. Singh K, Singh LM, Nagi B, Malik AK. Endoscopic removal of duodenal bruneroma. *Trop Gastroenterol* 1991; 12: 40-42.
13. Matsui K, Kitagawa M. Biopsy study of polyps in the duodenal bulb. *Am J Gastroenterol* 1993; 88: 253-257.

14. Rossonis GA, Tiniakos G, Tsioulis GJ, Fatsis ME, Rossonis SG. Large Brunner's gland adenoma. A case report. *Ital J Surg Sci* 1987; 17: 167-169.
15. Meier P, Guyer P, Genssenjager E, Stauli M. Giant adenoma of Brunner's glands. *Schweiz Med Wochenschr* 1989; 119: 1555-1559.
16. Matsuura H, Kuwano H, Kanematsu T, Sugimachi K, Harguchi Y. Clinicopathological features of elevated lesions of the duodenal bulb. *J Surg Oncol* 1990; 45: 79-84.
17. Fujimaki E, Nakamura S, Sugai T, Takeda Y. Brunner's gland adenoma with a focus of p53 -positive atypical glands. *J Gastroenterol* 2000; 35: 155-158.
18. Yadav D, Hertan H, Pitchumoni CS. A giant Brunner's gland adenoma presenting as gastrointestinal haemorrhage. *J Clin Gastroenterol* 2001; 32: 448-450.
19. Varma D, Prakash K, Augustine P, Mahadevan P, Ramesh H. Brunner's gland adenoma with circumferential duodenal involvement. *Indian J Gastroenterol* 2001; 20: 243.
20. Hochter W, Weingart J, Seib HJ, Ottenjann R. Duodenal polyps: Incidence, histologic substrate and significance. *Dtsch Med Wochenschr* 1984; 109: 1183-1186.
21. van Rooij WJ, van der Horst JJ, Stuijbergen WN, Pijpers PM. Extreme diffuse adenomatous hyperplasia of Brunner's glands: case report. *Gastrointest Radiol* 1990; 15: 285-287.
22. Akino K, Kondo Y, Ueno A, Yamazaki K, Hosikawa M, Shimoji H, et al. Carcinoma of the duodenum arising from Brunner's gland. *J Gastroenterol* 2002; 37: 293-296.
23. Matsui T, Iida M, Fujischiama M, Sakamoto K, Watanabe H. Brunner's gland hamartoma associated with microcarcinoids. *Endoscopy* 1989; 21: 37-38.
24. Jain KI, El Tayeb AA. Adenoma of Brunner's glands. Report of two cases. *Br J Surg* 1968; 55: 119-120.
25. Osborne R, Toffler R, Lowman RM. Brunner's gland adenoma of the duodenum. *Am J Dig Dis* 1973; 18: 689-694.
26. Adeonigbagbe O, Lee C, Karowe M, Feeney M, Wallack M, Montes M, et al. A Brunner's gland adenoma as a cause of anaemia. *J Clin Gastroenterol* 1999; 29: 193-196.
27. Chuang JH, Chen WJ. Duodenojejunal intussusception secondary to hamartomatous polyp of Brunner's glands. *J Pediatr Gastroenterol Nutr* 1991; 13: 96-100.
28. Mayoral W, Salcedo JA, Montgomery E, Al-Kawas FH. Biliary obstruction and pancreatitis caused by Brunner's gland hyperplasia of the ampulla of Vater; a case report and review of the literature. *Endoscopy* 2000; 32: 998-1001.
29. Yi NJ, Kim YW, Han HS, Fleischer GD. Duodenal polypectomy of Brunner's gland hyperplasia using a novel