

Isolated agenesis of the gallbladder

Pradeep J. Chopra, MS, FRCS Ed, Samir S. Hussein, MBBS, MSc(UK).

ABSTRACT

We report a rare case of agenesis of the gallbladder, which was misdiagnosed as cholecystitis. This is the first reported case from the Middle East. Despite advances in biliary imaging, the diagnosis is usually made at surgery. Like most patients, our patient became asymptomatic after the surgery. Extensive dissection to exclude the presence of gallbladder in an ectopic site is discouraged.

Saudi Med J 2003; Vol. 24 (4): 409-410

Agenesis of the gallbladder is a rare but well-recognized condition. Lemery first described it in 1701¹ and since then, more than 400 cases have been reported in the English literature. The reported incidence is around 0.01-0.06%.¹ Despite advances in biliary imaging, agenesis of the gallbladder is usually discovered at surgery for cholecystectomy. Non visualization of the gallbladder on ultrasonography in a symptomatic patient is presumed to be due to chronic cholecystitis (shrunken gallbladder).² Agenesis of the gallbladder is sometimes associated with other congenital malformations. The presence of the gallbladder in ectopic sites must be checked before the diagnosis is to be considered. For unexplained reasons, most of the patients become asymptomatic after the surgery.³

Case Report. A 32-year-old male presented with a 2-year history of episodic colicky right upper abdominal pain, which radiated to the interscapular region and was aggravated by fatty food. There was no history of jaundice or fever. Ultrasound scan at peripheral hospital showed gallstones and he was referred for laparoscopic cholecystectomy. Physical examination was unremarkable. Leukocyte count and liver function tests were within normal limits. A second ultrasound study did not identify the gallbladder. Cholescintigraphy

(^{99m}Tc-HIDA) also did not show filling of the gallbladder (**Figure 1**) and the tracer was found in the bowels after one hour. A presumptive diagnosis of nonfunctioning gallbladder caused by cholecystitis was made. The patient was posted for laparoscopic cholecystectomy. At laparoscopy on elevating the undersurface of liver, the gallbladder was not seen. There was no other anomaly. The falciform ligament, duodenal area and the left lobe of the liver were all normal. It was concluded that the patient has agenesis of the gallbladder and the procedure was terminated. Our patient did not have any family history to suggest gallbladder agenesis. He refused upper gastrointestinal endoscopy to rule out acid peptic disease. He was asymptomatic on 24 months follow-up.

Discussion. The gallbladder develops during the fourth week of intrauterine life from the caudal part of the hepatic diverticulum² and failure of the cystic bud to develop results in isolated gallbladder agenesis.² Most cases are found in infants with other major congenital anomalies.⁴ The fetal anomalies associated are diverse and include choledochal cyst,⁵ esophageal and rectovaginal fistulas, imperforate anus, polycystic kidneys, renal agenesis and duplication of the ureters,¹ tetralogy of Fallot, common atrium with agenesis of the left lung, atrial septal defect, patent foramen ovale,

From the Departments of Surgery (Chopra) and Nuclear Medicine (Hussein), Sultan Qaboos University Hospital, Al-Khod, Muscat, *Sultanate of Oman*.

Received 27th October 2002. Accepted for publication in final form 21st January 2003.

Address correspondence and reprint request to: Dr. Pradeep J. Chopra, Department of Surgery, Sultan Qaboos University Hospital, PO Box 38, Al-Khod 123, Muscat, *Sultanate of Oman*. Tel. +968 515119. Fax. +968 513009. E-mail: jpradeep@omantel.net.om

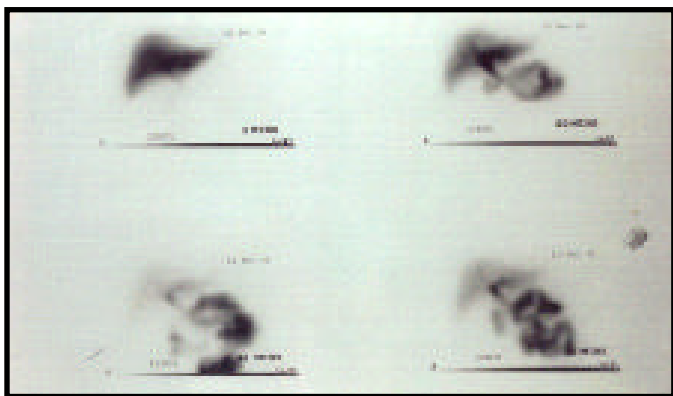


Figure 1 - Cholescintigraphy images at 5, 20, 40, and 60 minutes. The gallbladder was not seen in all images and almost all the tracer is in the bowel.

hypoplastic left heart syndrome and cleft lip and palate. Ectopic locations for the gallbladder include intrahepatic, between the leaves of the lesser omentum, in the retroperitoneum and retrohepatic region, within the falciform ligament, or in the retroduodenal and retropancreatic area.¹ Bennion et al³ suggested that agenesis of the gallbladder be categorized as a) associated with multiple fetal anomalies (children who invariably die in the perinatal period) b) asymptomatic (agenesis noted incidentally at autopsy or laparotomy for unrelated conditions) or c) symptomatic. They reported symptoms in 208 patients with agenesis of the gallbladder. Ninety percent had right upper quadrant pain, 66% nausea, 37% fatty food intolerance, and 36% jaundice.⁴ The cause of right upper quadrant abdominal pain in these patients is a matter of discussion. They have hypothesized that biliary dyskinesia was the cause of the pain. Biliary dyskinesia may be due to a greater retrograde ampullary sphincteric musculature contraction compared with normal subjects, promoting dilatation of the common bile duct and stasis¹ and calculi formation. Choledocholithiasis is reported to occur in 18-50% of patients with agenesis of gallbladder.¹ Dixon and Lichtman⁶ stated that the post-cholecystectomy syndrome is physiologically comparable with the symptomatology of the patient with agenesis of the gallbladder. Presumably, causes of pain shared by the 2 conditions include choledocholithiasis, biliary dyskinesia, or non biliary condition.

Preoperative diagnosis of gallbladder agenesis is not

conclusive and maybe difficult.^{1,2,7} Ultrasonography is the usual starting point in diagnosing biliary tract disease. Ultrasound of a patient with fever and right hypochondriac pain, in which the gallbladder is not visualized, might fairly indicate the presence of acute cholecystitis.¹ Shrunken gallbladder as an expression of chronic cholecystitis is probably the cause of preoperative ultrasound inaccuracy. It has been suggested that either a loop of gas containing bowel located in the gallbladder fossa or periportal tissue and subhepatic peritoneal folds mimic a shrunken gallbladder containing gallstones.^{1,2} Ancillary investigations such as scintigraphy would not outline the gallbladder, and raise the suspicion of cholecystitis.

For unknown reasons most symptomatic patients reported in the literature become symptom free after the operation.³ Those who remain symptomatic can be effectively managed with conservative treatment with smooth muscle relaxants. Sphincteroplasty may be reserved for nonresponders. The pros and cons of extensive dissection to exclude the presence of a gallbladder in an ectopic position have been discussed.⁴ In our patient we were able to confidently avoid such dissection on the strength of the evidence in ultrasonography and biliary scintigraphy. Computerized tomography of the abdomen and magnetic resonance cholangiography were not carried out as our patient refused any further investigations.

References

1. Singh B, Moodley J, Haffejee AA, Rajaruthnam P. Laparoscopic diagnosis of Gallbladder Agenesis. *Surg Laparosc Endosc* 1997; 7: 129-132.
2. Watemberg S, Rahmani H, R. Avrahami R, Nudelman IL, Deutsch AA. Agenesis of the Gallbladder found at laparoscopy for Cholecystectomy: an unpleasant surprise. *Am J Gastroenterol* 1995; 90: 1020-1021.
3. Bennion RS, Thompson JE Jr, Tompkins RK. Agenesis of the gallbladder without extrahepatic biliary atresia. *Arch Surg* 1988; 123: 1257-1260.
4. Richards RJ, Taubin H, Wasson D. Agenesis of the Gallbladder in Symptomatic Adults. A case and review of the literature. *J Clin Gastroenterol* 1993; 16: 231-233.
5. Goel AK, Seenu V, Khosla NK, Gupta A, Sarda AK. Agenesis of Gallbladder with Choledochal cyst - an unusual combination. *Trop Gastroenterol* 1994; 15: 33-36.
6. Dixon CF, Lichtman AL. Congenital absence of the gallbladder. *Surgery* 1945; 17: 11-21.
7. Azmat N, Francis KR, Mandava N, Pizzi WF. Agenesis of the gallbladder revisited laparoscopically. *Am J Gastroenterol* 1993; 88: 1269-1270.