

## Stone ingestion by a child

*Riyadh Hassan, MD.*

**F**oreign body (FB) ingestion is a common occurrence in everyday clinical practice, especially among children and psychologically abnormal people. Eighty to ninety percent passes through the gastrointestinal tract (GIT) spontaneously, 10-20% needs non-surgical intervention and <1% needs surgical intervention. Treatment depends on type of the foreign body, organ affected, type of symptoms and general condition of the patient.

Undigestible objects may be swallowed by children and deranged or inebriated adults. An object larger than 5x2 cm rarely pass the stomach.<sup>1</sup> At times FB ingestion is intentional and at others it is accidental. The management depends on the type of object, the affected organ, the type of symptoms and the patients conditions decides if, when, and how to intervene.<sup>2</sup> Foreign bodies in asymptomatic patients for the most part should be allowed to progress through the GIT spontaneously, monitored by serial radiographs. The role of the surgeon is to identify the occasional patient in whom surgical treatment is needed.

We present the case of a 10-year-old child with ingested massive amounts of stones and discovered accidentally. She was seen to the Emergency Room of Al-Qadiysia Hospital, Baghdad, Iraq, she was suffering from abdominal pain and vomiting for 2 days. She had a low-grade fever and pallor with tenderness and rebound tenderness in the right iliac fossa. A provisional diagnosis of acute appendicitis was made. After routine preoperative investigations, she was prepared to be operated upon as an emergency. At surgery, the cecum was full of small hard masses, this feeling extended to the whole large bowel and rectum and up to the small intestine. The appendix was acutely inflamed. Classical appendectomy was carried out. The problem was what to do on the stones. We picked one of the largest stones in the small bowel and tried to milk it down to the cecum trying to pass it through the ileocecal valve, the stone passed easily. So, we planned to do only anal dilatation. This recovered many stones from the rectum. On the next day a plain x-ray of the abdomen (**Figure 1**), which showed the huge number of stones in the bowel.

The family denied any abnormal behavior of their child. The patient was referred to a psychiatrist for

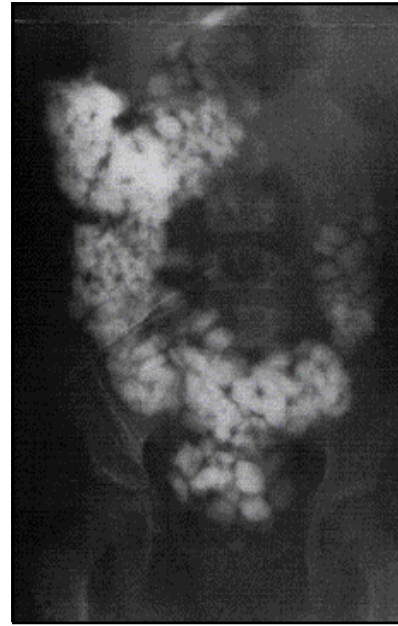


Figure 1 - Plain x-ray of the abdomen showing multiple stones.

further management. She had an uneventful postoperative recovery. On follow-up, the mother said that her child is passing a large number of small stones everyday.

Smooth objects are usually innocuous, and considerable patience should be exercised to permit their passage through the GIT. If after 4 weeks, the object remains, or the object is larger than the duodenal loop, or long and sharp, removal using fiberoptic endoscopy is indicated.

*Received 30th October 2002. Accepted for publication in final form 11th January 2003.*

*From the ENT Department, Al-Qadiysia Hospital, Baghdad, Iraq. Address correspondence and reprint requests to: Riyadh Hassan, Specialist Surgeon, Al-Qadiysia Hospital, PO Box 18558, Baghdad, Iraq. Fax. +964 (1) 8166584. E mail: maysoon@warkaa.net*

### References

1. Available from URL: [http://www.merckmanual.com/sec\\_3/ch\\_24/bezoars\\_and\\_foreign\\_bodies](http://www.merckmanual.com/sec_3/ch_24/bezoars_and_foreign_bodies).
2. Murshid KR, Khairy GE. Laparoscopic removal of a foreign body from the intestine. *J R Coll Surg Edinb* 1998; 43: 109-111.