

The significance of the neurovascular structures passing through the spinoglenoid notch

Mustafa Aktekin, MD, PhD, Deniz Demiryürek, MD, PhD, Alp Bayramoglu, MD, PhD, Eray Tüccar, MD, PhD.

ABSTRACT

Objective: To define the detailed anatomy of the neurovascular bundle at the spinoglenoid notch and to report the dimensions of these structures in cadavers.

Methods: In the present study, the external diameters of suprascapular artery, vein and nerve were measured at the spinoglenoid notch region in 18 formalin fixed cadavers (36 shoulders) by using a caliper. The study was carried out in the dissection laboratory of Anatomy Departments of Hacettepe University, Ankara University, Ankara and Mersin University, Mersin, Turkey, between 2002 and 2003.

Results: The average external diameter for the suprascapular vein was 2.6 mm, artery was 2.2 mm and nerve was 2.2 mm. The spinoglenoid notch was roofed by the spinoglenoid ligament and appeared as a fibroosseous foramen in all cadavers. We found that the vascular structures

(suprascapular artery and vein) occupied 68.5% and the suprascapular nerve occupied 31.5% of this foramen.

Conclusion: Although the diameters of the vascular structures at the spinoglenoid notch measured by magnetic resonance imaging have been reported, to our knowledge, external diameters of these structures at the spinoglenoid notch have not been described in cadavers. We believe that detailed anatomy of suprascapular neurovascular bundle at the spinoglenoid notch should be appreciated for better understanding of risk factors possibly causing the suprascapular nerve entrapment syndrome, specially for those who are involved in violent overhead sports activities such as volleyball and baseball.

Saudi Med J 2003; Vol. 24 (9): 933-935

Suprascapular nerve or its branches are liable to compression at distinct locations, namely the suprascapular notch and the spinoglenoid notch. Since the first description of suprascapular nerve entrapment syndrome by Thompson and Kopell,¹ a number of studies have been carried out to identify the etiologic factors. Compression by tumors and ganglion cysts, traction injuries, direct trauma such as fracture of scapula and variations in anatomy along the course of the nerve have been reported as the causes of the suprascapular nerve entrapment.²⁻⁸ Recently, enlarged veins have been described as potential mass lesions

causing suprascapular nerve compression neuropathy at the spinoglenoid notch.⁹ Although the diameters of the vascular structures at the spinoglenoid notch measured by magnetic resonance imaging (MRI) have been determined in a previous study, the external diameters of these structures at the spinoglenoid notch in cadavers have not been reported in the literature.

The purpose of the study is to define the detailed anatomy of the neurovascular bundle at the spinoglenoid notch and to report the dimensions of these structures in cadavers. This is of importance for better understanding of risk factors possibly causing the compression of the

From the Department of Anatomy (Aktekin), Faculty of Medicine, Mersin University, Mersin, Department of Anatomy (Demiryürek, Bayramoglu), Faculty of Medicine, Hacettepe University, and the Department of Anatomy (Tüccar), Faculty of Medicine, Ankara University, Ankara, Turkey.

Received 2nd April 2003. Accepted for publication in final form 26th May 2003.

Address correspondence and reprint request to: Dr. Deniz Demiryürek, Department of Anatomy, Faculty of Medicine, Hacettepe University, Sıhhye 06100, Ankara, Turkey. Tel. +90 (312) 3052359. Fax. +90 (312) 3107169. E-mail: mdeniz@hacettepe.edu.tr

suprascapular nerve, specially for those involved in violent overhead sports activities such as volleyball and baseball.

Methods. The study was carried out on both shoulders of 5 female and 13 male formalin fixed cadavers (36 shoulders) between the ages of 33 and 78 years (mean age was 55.4 years). Spinoglenoid notches of all cadavers were examined with a posterior approach. The skin incisions were made parallel and caudal to the spine of the scapula. Then the infraspinatus muscle was reflected from the infraspinous fossa from medial to lateral to expose the suprascapular neurovascular bundle entering the muscle tissue. The neurovascular bundle was dissected carefully towards the spinoglenoid notch and the fascia of the neurovascular bundle was cleaned to allow the visualization of the suprascapular nerve, artery and vein separately. Presentation of the spinoglenoid ligament and the relationship of suprascapular nerve with the vascular structures at the spinoglenoid notch, were inspected carefully. External diameters of suprascapular artery, vein and nerve at the spinoglenoid notch were measured by using a caliper.

Results. Spinoglenoid ligament was observed in all shoulders, and extended from inferior border of the lateral part of the spine of the scapula to the superior margin of the glenoid (**Figure 1**). Therefore, the neurovascular bundle was enclosed by a fibroosseous foramen formed by the spine of the scapula and the spinoglenoid ligament, in all cadavers. The vascular structures (suprascapular artery and vein) occupied 68.5% and the suprascapular nerve occupied 31.5% of this foramen. Suprascapular nerve, artery and vein coursed in an order from medial to lateral and from superior to inferior in all cadavers at the spinoglenoid notch (**Figures 2a & 2b**). The suprascapular nerve measured at the spinoglenoid notch, ranged from 1.5 mm to 2.7 mm in diameter with an average of 2.2 mm. These measurements were also the same for the suprascapular artery. The suprascapular vein measured at the spinoglenoid notch, ranged from 1.9 mm to 3.2 mm in diameter with an average of 2.65 mm.

Discussion. Particular attention in this anatomic study was devoted to the presence of spinoglenoid ligament and the neurovascular structures passing through the spinoglenoid notch. A striking finding in our study was the presence of spinoglenoid ligament in all examined shoulders. Previous anatomical studies have been inconsistent regarding the prevalence of this ligament. Mestdagh et al¹⁰ reported the existence of the spinoglenoid ligament (SGL) in 10 of 20 cadavers. Kaspi et al¹¹ found that the SGL was present in 72% of 25 specimens. Demaio et al¹² found the SGL present in only 2 of 75 shoulders. Cummins et al¹³ demonstrated a SGL in 81% of the 112 shoulders. Demirhan et al¹⁴ found the SGL present in 14 of 23 specimens. The

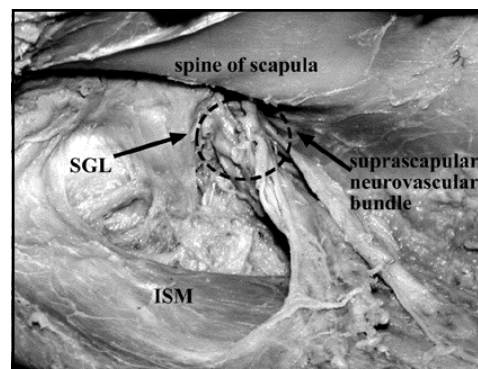


Figure 1 - Posterior aspect of a left scapula showing the spinoglenoid ligament and the suprascapular neurovascular bundle. SGL - spinoglenoid ligament, ISM - reflected infraspinatus muscle

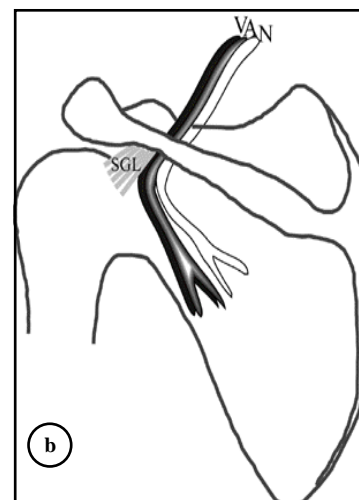
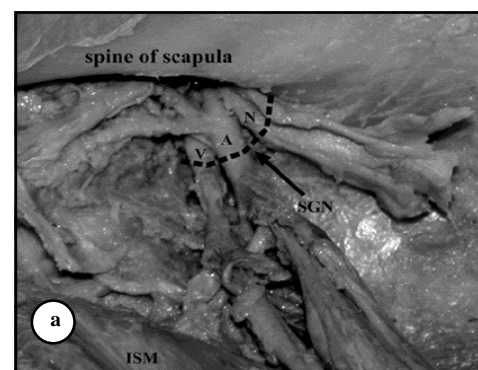


Figure 2 - Neurovascular structures at the spinoglenoid notch a) Posterior aspect of a left scapula showing the suprascapular nerve, artery and vein passing through the spinoglenoid notch in order. b) This diagram of the left shoulder from a posterior view portrays the course of the suprascapular nerve, artery and vein through the spinoglenoid notch. N - suprascapular nerve, A - suprascapular artery, V - suprascapular vein, SGN - spinoglenoid notch, ISM - reflected infraspinatus muscle, SGL - spinoglenoid ligament

presence of spinoglenoid ligament is of potential clinical importance for 2 reasons. First, the ligament may limit the advancement of the infraspinatus tendon during repair of a massive tear of the rotator cuff, placing the distal part of the suprascapular nerve at risk. Second, the spinoglenoid ligament roofing the spinoglenoid notch forms a potential site for entrapment of the suprascapular nerve, particularly with the added stress of traction that can occur with overhead athletic activities.¹³ Trauma, anatomical variations, overuse or mass lesions may cause compression of the suprascapular nerve. Mass lesions which may compress the suprascapular nerve including ganglion cysts, synovial sarcoma, Ewing sarcoma, chondrosarcoma and metastatic renal cell carcinoma have been described.^{15,16} Carroll et al⁹ described the MRI findings of distended veins as a cause of suprascapular nerve compression at the spinoglenoid notch region. In their study, the spinoglenoid notch vascular structures were specifically evaluated with MRI and the diameters of these structures in 6 patients with chronic shoulder pain were compared with the diameters in 10 age-matched controls. The average diameter in 6 patients was 8.4 mm and the average diameter of 10 controls was 2.2 mm. According to Carroll et al,⁹ enlarged veins were described for the first time in the radiology or orthopedic literature as potential mass lesions causing suprascapular nerve compression neuropathy.

To our knowledge, external diameters of the structures forming the neurovascular bundle at the spinoglenoid notch have not been described in the literature in cadavers and we believe that knowing the data given in our study should be appreciated for better understanding of risk factors possibly causing the suprascapular nerve entrapment syndrome at the spinoglenoid notch region, specially for those involved in violent overhead sports activities such as volleyball and baseball. We believe that enlargement of the vascular structures at the spinoglenoid notch in those individuals due to excessive shoulder movements might occur and result compression on the suprascapular nerve. Eventually, we would like to use MRI to compare the diameters of vascular structures in professional volleyball players with the findings of normal age-matched population.

References

1. Thompson WAL, Kopell HP. Peripheral entrapment neuropathies of the upper extremity. *N Engl J Med* 1959; 260: 1261-1265.
2. Alon M, Weiss S, Fishel B, Dekel S. Bilateral suprascapular nerve entrapment syndrome due to an anomalous transverse scapular ligament. *Clin Orthop* 1988; 234: 31-33.
3. Callahan JD, Scully TB, Shapiro SA, Worth RM. Suprascapular nerve entrapment. *J Neurosurg* 1991; 74: 893-896.
4. Clein LJ. Suprascapular entrapment neuropathy. *J Neurosurg* 1975; 43: 337-342.
5. Ganzhorn RW, Hocker JT, Horowitz M, Switzer HE. Suprascapular nerve entrapment: A case report. *J Bone Joint Surgery* 1981; 63A: 492-494.
6. Hadley MN, Sonntag VKH, Pittman HW. Suprascapular nerve entrapment: a summary of seven cases. *J Neurosurg* 1986; 64: 843-848.
7. Rengachary SS, Neff JP, Singer PA, Brackett CF. Suprascapular nerve entrapment neuropathy: A clinical, anatomical and comparative study. Part 1: Clinical study. *Neurosurgery* 1979; 5: 441-446.
8. Bayramoglu A, Demiryürek D, Erbil M, Aktekin M, Tetik O, Doral MN. Hypertrophy of the infraspinatus muscle might be an etiologic factor for suprascapular nerve entrapment at the suprascapular notch. *Neuroanatomy* 2002; 1: 5-6.
9. Carroll KW, Helms CA, Otte MT, Moelken MC, Fritz R. Enlarged spinoglenoid notch veins causing suprascapular nerve compression. *Skeletal Radiol* 2003; 32: 72-77.
10. Mestdagh H, Drizenko A, Gesthem P. Anatomical bases of suprascapular nerve syndrome. *Anat Clin* 1981; 3: 67-71.
11. Kaspi A, Yanai J, Pick JG, Mann G. Entrapment of the distal suprascapular nerve: an anatomical study. *Int Orthop* 1988; 12: 273-275.
12. Demaio M, Drez DJ, Mullins RJ. The inferior transverse scapular ligament as a possible cause of entrapment neuropathy of the nerve to the infraspinatus. *J Bone Joint Surg Am* 1991; 73: 1061-1063.
13. Cummins CA, Anderson K, Bowen M, Nuber G, Roth SI. Anatomy and histological characteristics of the spinoglenoid ligament. *J Bone Joint Surg Am* 1998; 11: 1622-1625.
14. Demirhan M, Imhoff AB, Debski RE, Patel PR, Fu FH, Woo SL. The spinoglenoid ligament and its relationship to the suprascapular nerve. *J Shoulder Elbow Surg* 1998; 7: 238-243.
15. Fritz RC, Helms CA, Steinbach LS, Genant HK. Suprascapular nerve entrapment: evaluation with MR imaging. *Radiology* 1992; 182: 437-444.
16. Tirman PF, Feller JF, Janzen DL, Peterfy CG, Bergman AG. Association of glenoid labral cysts with labral tears and glenohumeral instability: radiologic findings and clinical significance. *Radiology* 1994; 190: 653-658.