

# Amlodipine associated hyperpigmentation

Zulal Erbagci, MD.

---

## ABSTRACT

Amlodipine is a potent peripheral and coronary vasodilator with high selectivity for vascular smooth muscle, and is widely used in mild to moderate hypertension, chronic stable angina and vasospastic angina. Its most prevalent side effects are peripheral edema, flushing and headache. Cutaneous adverse reactions associated with amlodipine have been rarely reported. Herein, a male patient is described to develop oral mucosal and cutaneous hyperpigmentation one year after starting amlodipine, which became more noticeable with time. Although cutaneous hyperpigmentation was most prominent on the photoexposed areas, there was no history of previous photosensitivity, pruritus or flushing. To our knowledge, no case of oral and cutaneous hyperpigmentation associated with amlodipine has been formally reported up to date.

Saudi Med J 2004; Vol. 25 (1): 103-105

---

Calcium antagonists are a chemically heterogeneous group of agents with potent cardiovascular effects; namely, inhibition of the transmembrane influx of calcium ions into cardiac and vascular smooth muscle. They are widely used in the treatment of angina pectoris, arterial hypertension and cardiac arrhythmias.<sup>1</sup> Their most prevalent side effects are dose-dependent and related to their actions on calcium antagonism, such as vasodilatation presenting as leg edema, flushing, telangiectasia or headache.<sup>1-3</sup> Amlodipine, which was first introduced in 1993, is a **dihydropyridine**-derivative structurally related to nifedipine. As direct and selective action of amlodipine on arteriolar smooth muscles lead to a reduction in peripheral vascular resistance and blood pressure with a minimal effect on myocardial contractility or cardiac conduction, it is indicated for the first-line treatment of essential hypertension.<sup>4</sup> Such as other calcium antagonists, cutaneous adverse reactions associated with amlodipine have been rarely recorded.<sup>3,4</sup> In this report, the first case of generalized hyperpigmentation associated with amlodipine is described.

**Case Report.** A 45-year-old Caucasian Turkish male patient with Fitzpatrick's skin type III presented

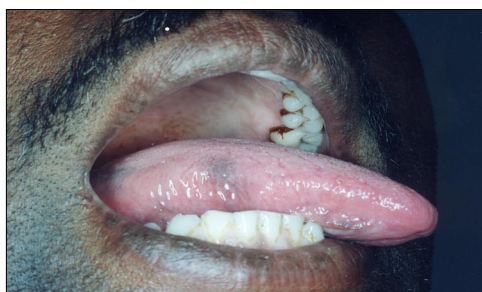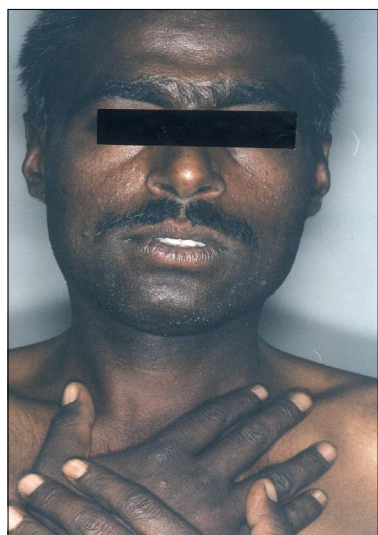
to our Dermatology Outpatient Clinic with a 2 year-history of gradually increasing, asymptomatic generalized hyperpigmentation. He had been given amlodipine 10 mg daily for essential hypertension for 3 years. His other medications included occasional H<sub>2</sub> antagonists and antacids for chronic gastritis. There were no history and evidence of any photosensitivity reaction, but he was a farmer and had been living in a sunny mountain village since childhood. Physical examination revealed a dark-brown extensive homogenous cutaneous pigmentation, pronounced mostly on the sun-exposed areas including face, neck, hand backs and forearms. Additionally, there were many small firm papules 1-3 mm in size located on the face, mainly on the cheeks. He also had a slate-gray discoloration on the lips, blue-gray patches on the lateral aspects of the tongue, and several pinpoint, brown pigmented macules on the hard palate. The sclera, nails, palms and soles were spared, but a dark brown pigmentation was present on the palmar and finger creases (**Figure 1a & 1b**). Clinical diagnosis was suggestive of Addison's disease, drug-induced hyperpigmentation, and amyloidosis, hemochromatosis or heavy metal deposition. A 4 mm-punch biopsy specimen from a facial papule along with contiguous pigmented skin demonstrated hyperkeratosis, mild

---

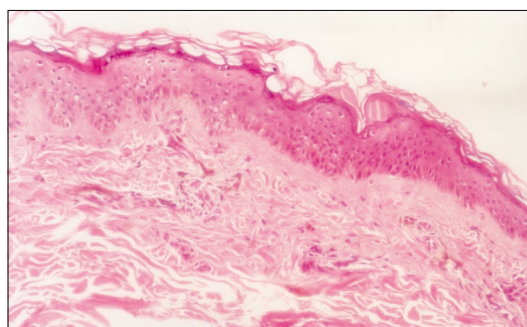
From the Department of Dermatology, Gaziantep University Medical Faculty, Gaziantep, Turkey.

Received 13th June 2003. Accepted for publication in final form 14th September 2003.

Address correspondence and reprint request to: Dr. Zulal Erbagci, Gazimuhtarapasa Bulvari. Gecit 1 No. 1/5, 27090 Gaziantep, Turkey. Tel. +90 (342) 3365400. Fax. +90 (342) 3603928. E-mail: zerbagci@yahoo.com/z/erbagci@hotmail.com



**Figure 1** - Amlodipine associated hyperpigmentation **a)** photoaccentuated dark brown cutaneous pigmentation and **b)** small keratotic papules on the cheek, slate-gray patchy discoloration of the lips and tongue, and pinpoint brown macules on the hard palate.



**Figure 2** - Histopathology showing increased pigmentation of basal layer, focal minimal interface changes, and dermal pigment laden cells admixed with sparse inflammatory cells around the dilated vessels (Hematoxylin-eosin: original magnification x 40)

acanthosis, minimal focal vacuolar changes at the dermoepidermal interface, and just adjacently, a flattened epidermis with effaced rete ridges showing increased pigmentation in the basal layer. There were also many pigment-laden macrophages around dilated and thin-walled dermal vessels (**Figure 2**). Congo red stain and Prussian blue stain were negative for amyloid and iron deposition. Pigment laden cells stained positively with Fontana-Masson stain, confirming that deposited pigment was melanin. The results of the laboratory investigations including complete blood cell count, serum urea nitrogen, creatinine, liver function tests, antinuclear antibodies, serum iron studies; basal cortisol levels and adrenocorticotrophic hormone stimulation test results were all in normal ranges or negative. A diagnosis of photo distributed cutaneous and oral mucosal hyperpigmentation associated with amlodipine was made. Photo protection along with replacement of amlodipine with another antihypertensive of different class was advised. He was then lost to follow-up. Nevertheless, he later reported by phone that skin discoloration faded slightly 8 months after changing amlodipine to metoprolol and strict avoidance of sun exposure.

**Discussion.** Drug-induced pigmentation represents 10-20% of all cases of acquired hyperpigmentation. It occurs usually slowly, worsens over time, and is frequently pronounced on photoexposed areas. However, it may also involve oral mucosa, conjunctiva, sclera and nails.<sup>5,6</sup> Drug-induced dyschromia should be suspected in all unexplained pigmented lesions whatever its pattern, especially in elderly people. Other cutaneous lesions including lichenoid lesions and a nonspecific inflammation associated with or without photosensitivity may occasionally accompany hyperpigmentation. The pathogenesis of drug-induced pigmentation is variable according to the causative medication, and following mechanisms have been proposed: (i) melanin accumulation, which may be due to a nonspecific cutaneous inflammation caused by the medication which worsens by sun exposure, or an increased melanin production by epidermal melanocytes specifically stimulated by the drug, or a lack of melanin clearance due to irreversible binding of the drug to melanin, (ii) accumulation of the triggering drug itself, (iii) synthesis of special pigments like lipofuscin under the direct influence of the drug and (iv) deposition of iron following drug-induced damage of dermal vessels.<sup>5</sup> The main drugs implicated in causing skin pigmentation are amiodarone, non-steroidal anti-inflammatory drugs, psychotropic agents, tetracyclines, antimalarials, cytotoxic drugs and heavy metals.<sup>5,6</sup> Aside from the well-known side effects related to the anticipated pharmacological properties of calcium antagonists, idiosyncratic reactions due to these agents have been rarely reported, including arthralgia, hepatotoxicity, gingival

hyperplasia, transitory mental confusion and akathisia.<sup>1-3,7,8</sup> Serious and rare reactions associated with these agents occur usually within the first 2 weeks after initiating drug therapy, and include erythema multiforme, Stevens-Johnson syndrome and exfoliative dermatitis associated with nifedipine verapamil and diltiazem, as well as toxic epidermal necrolysis due to diltiazem.<sup>2</sup> Cohen et al<sup>9</sup> suggested also a possible role for calcium channel blockers as precipitating or exacerbating factors in patients with psoriasis. The incidence of recognized cutaneous and mucosal adverse reactions due to amlodipine is very low (<1%), and include skin dryness, dermatitis, erythematous maculopapular rash, alopecia, urticaria, pruritus, erythema multiforme, lichen planus, granuloma annulare-like reaction, gingival overgrowth and swelling, photosensitivity, photo distributed telangiectasia and skin discoloration.<sup>4,7-14</sup> Although cases of photosensitivity reactions and photo distributed telangiectasia related to calcium antagonists have been occasionally reported,<sup>3,7,14-17</sup> an extensive literature search revealed no previously well documented case of hyperpigmentation induced by amlodipine or any other calcium channel blockers, except 4 cases of diltiazem-associated photo distributed reticulate hyperpigmentation.<sup>18</sup> The mechanism of amlodipine-associated discoloration in our case is unclear, and this association may be completely coincidental. However, when considering the pronounced photo distribution of the cutaneous pigmentation, it is possible that it may be related to a significant drug or light interaction, leading to a clinically inapparent phototoxic or photo lichenoid reaction that may result in increased melanization of basal layer and deposition of melanin in dermal macrophages. Histopathologic examination of the skin showed lichenoid dermatitis with prominent pigmentary incontinence, and the deposited pigment was clearly demonstrated to be melanin. Based on the spectrophotometric data, Hashimoto et al<sup>17</sup> have suggested that a metabolite might be the actual sensitizer in a Japanese farmer suffering from a pruritic lichenoid eruption due to diltiazem. The mechanism of oral pigmentation remains also to be determined, but it might be related to an increased concentration of amlodipine in the oral mucosa, since the concentrations of this drug have been shown to be much greater within the gingival crevicular fluid than in plasma in patients with gingival overgrowth.<sup>8</sup> Other triggering factors which can potentially cause such a pattern of dyschromia, including photo contact dermatitis related to cosmetics and fragrances, argyria and certain drugs such as amiodarone, antimalarials, imipramine or chlorpromazine were excluded in the current case on the basis of history and clinical findings. Minocycline induces hyperpigmentation in areas of cutaneous inflammation, typically in acne scars and pigment deposition related to minocycline has been demonstrated to be iron.<sup>19</sup> This drug also is unlikely to be the culprit agent in our case, since deposited pigment was demonstrated to be melanin

and minocycline is not available in Turkey. Treatment of drug-induced dyschromias is usually unsatisfactory, and often limited to sun-avoidance, the use of ultraviolet B and ultraviolet A blocking sunscreens with a bleaching agent such as hydroquinone, and if available, laser therapy.<sup>5,5</sup> Replacement of the offending drug with another antihypertensive agent of different pharmacologic activity is also of prime importance in the treatment since a cross-reactivity exists among the various calcium antagonists.<sup>2,3,18</sup> With these measures, a gradual fading in the pigmentation may occur, however, it lasts usually for a very long time or even becomes permanent in some patients.

## References

- Hedner T. Calcium channel blockers: spectrum of side effects and drug interactions. *Acta Pharmacol Toxicol* 1986; 58 (Suppl 2): 119-130.
- Stern R, Khalsa JH. Cutaneous adverse reactions associated with calcium channel blockers. *Arch Intern Med* 1989; 149: 829-832.
- Collins P, Ferguson J. Photodistributed nifedipine-induced facial telangiectasia. *Br J Dermatol* 1993; 129: 630-633.
- Tyler HM. Amlodipine: an effective once-daily antihypertensive agent. *J Hum Hypertens* 1991; 5 Suppl 1: 61-66.
- Dereure O. Drug-induced skin pigmentation. Epidemiology, diagnosis and treatment. *Am J Clin Dermatol* 2001; 2: 253-262.
- Fenske NA, Milam CP. Drug-induced pigmentation abnormalities. In: Demis DJ, editor. *Clinical Dermatology*. 19th ed. Philadelphia (PA): JB Lippincott Comp; 1992. p. 11-22.
- van der Vleuten CJ, Trijbels-Smeulders MA, van de Kerkhof PC. Telangiectasia and gingival hyperplasia as side-effects of amlodipine (Norvasc) in a 3-year-old girl. *Acta Derm Venereol* 1999; 79: 323-324.
- Ellis JS, Seymour RA, Thomason JM, Monkman SC, Idle JR. Gingival sequestration of amlodipine and amlodipine-induced gingival overgrowth. *Lancet* 1993; 341: 1102-1103.
- Cohen AD, Kagen M, Friger M, Halevy S. Calcium channel blockers intake and psoriasis: a case-control study. *Acta Derm Venereol* 2001; 1: 47-49.
- Orme S, da Costa D. Generalised pruritus associated with amlodipine. *BMJ* 1997; 315: 463.
- Bewley AP, Feher MD, Staughton RC. Erythema multiforme following substitution of amlodipine for nifedipine. *BMJ* 1993; 307: 241.
- Lim AC, Hart K, Murrell D. Granuloma annulare-like eruption associated with the use of amlodipine. *Australas J Dermatol* 2002; 43: 24-27.
- Swale VJ, McGregor JM. Amlodipine-associated lichen planus. *Br J Dermatol* 2001; 144: 920-921.
- Grabczynska SA, Cowley N. Amlodipine induced-photosensitivity presenting as telangiectasia. *Br J Dermatol* 2000; 142: 1255-1256.
- Basarab T, Yu R, Jones RR. Calcium antagonist-induced photo-exposed telangiectasia. *Br J Dermatol* 1997; 136: 974-975.
- Seggev JS, Lagstein Z. Photosensitivity reactions to calcium channel blockers. *J Allergy Clin Immunol* 1996; 97: 852-855.
- Hashimoto M, Tanaka J, Horin T. Photosensitivity due to diltiazem hydrochloride. *Acta Dermatol* 1979; 74: 181-186.
- Scherschun L, Lee MW, Lim HW. Diltiazem-associated photodistributed hyperpigmentation: a review of 4 cases. *Arch Dermatol* 2001; 137: 179-182.
- Pepine M, Flowers FP, Ramos-Caro FA. Extensive cutaneous hyperpigmentation caused by minocycline. *J Am Acad Dermatol* 1993; 28: 292-295.