Case Report

Thrombocytopenia responding to red blood cell transfusion

Ahmed A. Mubarak, MD, CABM, *Abdalla Awidi,* FRCP,
Kakil I. Rasul, CABM, MRCP, *Ussama Al-Homsi,* MD.

ABSTRACT

Three patients with severe symptomatic iron deficiency anemia and thrombocytopenia had a significant rise in platelet count a few days following packed red blood cell transfusion. Pre-transfusion platelet count of patient one was 17 x 10^9/L, 22 x 10^9/L in patient 2 and 29 x 10^9/L in patient 3. On the 6th day post transfusion, the platelet count rose to 166 x 10^9/L in patient one, 830 x 10^9/L in patient 2 and 136 x 10^9/L in patient 3. The possible mechanisms behind such an unreported observation are discussed.

Saudi Med J 2004; Vol. 25 (1): 106-109

Thrombocytopenia is reported occasionally in cases of severe iron deficiency anemia (IDA). Oral iron therapy is the usual management of IDA. Blood transfusion is reserved only for occasional cases of severe symptomatic IDA especially if there is hemodynamic instability. Three patients with severe symptomatic IDA and thrombocytopenia were treated with packed red blood cell (RBC) transfusion. Dramatic recovery of platelet count was observed following transfusion. In addition, the third patient had leucopenia which responded dramatically to packed RBC transfusion. A literature review did not show any reported cases of IDA whose thrombocytopenia corrected after blood transfusion. In this paper, we report 3 such cases.

Case Report. *Patient One*. A 25-year-old male patient was referred to the hematology clinic for evaluation of anemia and thrombocytopenia. He presented with severe epistaxis for one month with easy fatigue and palpitations. No history of purpura, melena, or hematuria. The dietary history indicated poor iron source intake. On examination the patient was pale, his pulse was 100/minute, blood pressure 100/70, temperature 37 °C. No cervical, axillary or inguinal lymphadenopathy. The chest and cardiac examinations were normal except for an ejection systolic murmur. Abdominal examination revealed normal liver span and no splenomegaly. Nasal examination revealed nasal bleeding with no evidence of local ear, nose, throat (ENT) pathology. Hemoglobin (Hb) was 4.2 gm/dl, mean cell volume (MCV) 60 fl, white blood count (WBC) was 5.8 x 10^9/L and platelet count was 17 x 10^9/L. The stool for occult blood was negative. No ova, cyst or parasites could be detected by stool examination. Urine examination was normal. Antinuclear antibody (ANA), anti-DNA, monospot test and human immunodeficiency virus (HIV) were all negative. Ferritin level was 12 mg/L (normal range 24-336 mg/L), serum B12 was 320 pmol/L (normal range 133-675 pmol/L), and RBC folate was 1320 nmol/L (normal range 338-1970 nmol/L). Bone marrow aspirate was hypercellular with a reduced megakaryocyte number. Bone marrow iron store was depleted. The patient was transfused 2 units of packed

From the Department of Medicine, Hamad Medical Corporation, Doha, *Qatar*.

Received 9th June 2003. Accepted for publication in final form 14th September 2003.

Address correspondence and reprint request to: Dr. Ahmed Mubarak, Department of Medicine, Hamad Medical Corporation, PO Box 3050, Doha, *Qatar*. Fax.+974 4392273. E-mail: mubarak1955@hotmail.com

RBC on the day of admission and 2 units 2 days later. The patient's platelet count recovered (**Figure 1).** He was discharged on oral ferrous sulfate 200 mg 3 times daily. A follow-up 2 months later showed a normal platelet count and normal hemoglobin.

Patient 2. A 17-year-old female patient presented with history of fatigue, shortness of breath and palpitation for 3 days. She had 7 days history of heavy menstrual bleeding preceded by intermittent vaginal bleeding for 2 months. She gave no history of bleeding tendency apart from the vaginal bleeding. She had a dietary history of poor meat intake. On examination, she was pale and looked tired. There was no evidence of petechiae nor ecchymosis. Physical examination showed normal chest and cardiac examination was normal apart from tachycardia and ejection systolic murmur. Abdominal examination showed no hepatosplenomegaly. Vaginal examination did not show any local cause for the vaginal bleeding. Hemoglobin was 3.8 g/dL, hematocrit (Hct) 12.1%, MCV 62.8 fl, WBC 8.1 x 10^9/L, platelets was 24 x 10^9/L, serum iron 2 mmol/L, total iron-binding capacity (TIBC) 104 mmol/L, serum ferritin 5 mg/L, serum B12 239 pmol/L, RBC folate 1278 nmol/L, prothrombin time and partial activated thromboplastin time were normal. Her blood urea, serum creatinine and liver function tests were normal. The stool for occult blood was negative, no ova, cysts or parasites could be detected by microscopic examination. Urine examination was also normal. The bone marrow showed hypercellularity with megakaryocytic hyperplasia, and negative iron stain. Being symptomatic, the patient was transfused with 2 units of packed RBCs. **Figure 2**. She started on oral iron (ferrous sulfate 200mg tablet TID) and was discharged after completing the investigations. On follow-up 2 months later, she had no more vaginal bleeding. Her hemoglobin was 12.4 g/dL, platelet count was 296 x 10^9/L. Six months later, she had no vaginal bleeding, the hemoglobin was 13.2 g/dL and platelets were 329 x 10^9/L.

Patient 3. A 23-year-old, single, female presented with a history of intermittent heavy vaginal bleeding with severe dizziness and shortness of breath with palpitation on mild exertion. On examination she was very pale. There was no petechiae or hemorrhage. Physical examinations were all normal except for sinus tachycardia and ejection systolic murmur at left sternal boarder. Her Hb was 4.8 g/dl, MCV 55.1, platelets 31 x 10^9/L, WBC count was 2.4 x 109/L, serum ferritin was 2 mg/L, vitamin B 12 was 254 pmol/L, serum folate was 13.1 mmol/L (normal range 1 - 6.8 mmol/L). Stool examination was negative for occult blood and all work up for parasitic infestation was negative. Urine examination was normal. She refused bone marrow examination. One day after she was transfused with 2 units of packed RBC. Her platelet count response is shown in **Figure 3**.

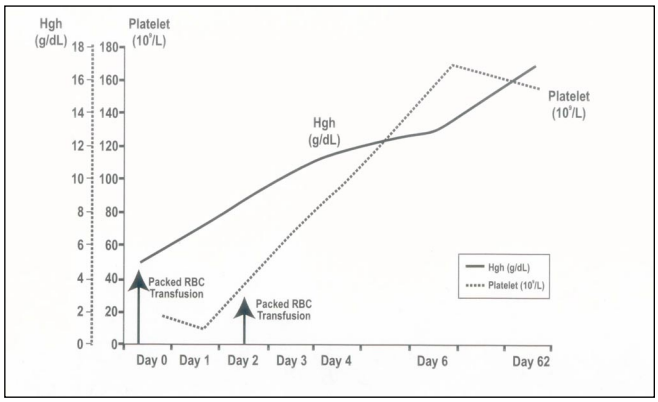

Figure 1 - Platelet response following packed red blood cell transfusion (in patient 1).

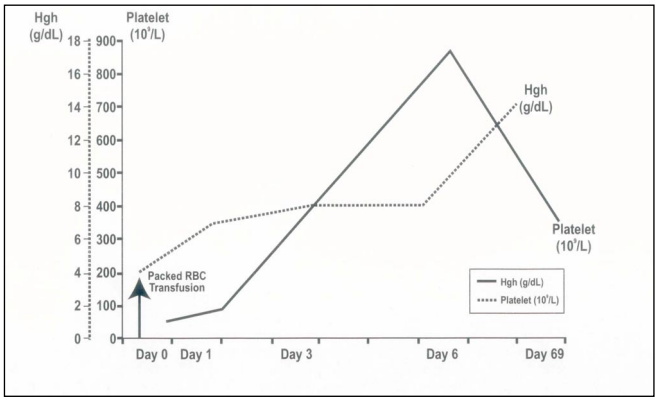

Figure 2 - Thrombocytopenia responding to packed red blood cell.

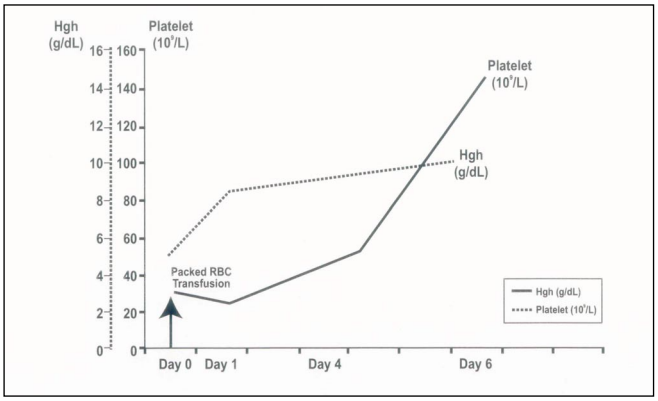

Figure 3 - Thrombocytopenia responding to packed red blood cell.

Discussion. We reported 3 cases with severe IDA and thrombocytopenia. The patients were severely symptomatic having repeated attacks of heavy bleeding and acute severe symptoms of anemia requiring blood transfusion. Surprisingly, an unexpected rapid stepwise rise in platelets count was observed within few days following transfusion. We believe that these are the first reported cases in humans in which thrombocytopenia responded to RBC transfusion. The explanation for such a phenomenon is not clear. An alteration in stem cells differentiation may give a clue to the explanation. In experimental animals, packed RBC hypertransfusion was found to enhance myeloid as well as thrombopoietic recovery. In mice receiving 350 rads as total body irradiation, the hypertransfused mice showed a greater rise in megakaryocyte concentration compared to similar group treated by plasma transfusion alone. The administration of daily dose of erythropoietin to hypertransfused mice delayed the rapid platelets recovery.[1] The most likely explanation for this observation is that erythropoietic demand influences megakaryocytopoiesis perhaps by altering the availability of the precursor from an earlier stem cell compartment. It seems that there is a sort of competition among the various hematopoietic cell lines for pluripotential stem cells and that by reducing the demand for one cell line, in this case the erythropoiesis, more stem cells became available for differentiation into other hematopoietic cell compartments (in this case thrombopoiesis). Such explanation has been proposed by several investigators.[2-6] Both our patients showed a dramatic rise in platelets count following packed RBC transfusion. Both patients had peak of platelets rise on the 6th day following transfusion. That pattern of the platelets rise is quite similar to the pattern of the platelets rise following the treatment of IDA with parenteral iron.[7] Moreover, the absence of platelets decline in our patients was also noted in those patients treated with parenteral iron therapy for IDA. The megakaryocyte count was low in the first and elevated in the second patient. Both of these findings were reported in patients with IDA and low platelets count. Iron was important for the development of megakaryocytes from the stem cells, which could explain the pathogenesis in the first patient. Moreover, the iron was found to be important for platelets production from megakaryocytes which could explain the pathogenesis in the second patient. A megakaryocytic thrombocytopenia was put in the differential diagnosis patient one, but the dramatic rapid response of platelets count to the packed RBCs transfusion made such a possibility quite unlikely. Thrombocytosis is well known to follow blood loss, but platelets were found to increase or decrease in nutritional IDA. The majority of patients with IDA have normal or elevated platelet count, but low platelet count has been observed as well.[7-10] Thrombocytopenia in IDA was found more commonly in pediatric age group.[7,8] In infants and children, up to 28% of patients with IDA had thrombocytopenia.8 That association was found particularly when the anemia was severe.[7,9,11,12] In thrombocytopenia and IDA, reduced number of megakaryocytes had been found in the bone marrow[13,14] while some patients had normal or elevated megakaryocyte number.[15]

In guinea pigs, chronic blood loss in animals on iron replacement resulted in 2.5 folds rise in platelets count above basal level, while chronic blood loss in animals with iron deficient diet caused 1.4 fold rise in platelets count above basal level.[16] Chronic blood loss in animal on iron replacement diet resulted in 3.8 fold rise in megakaryocytes number, while in animals on iron deficient diet chronic blood loss caused only 1.7 fold rise in megakaryocytic number.[16] This study concluded that iron is important for platelets production from megakaryocytes as well as megakaryocytes development from stem cells. Iron was found to be important for platelets protein synthesis. Thus 2,2 biperidin, a potent chelator of iron, inhibits platelets protein synthesis by 80%. That inhibition was overcome by addition of iron containing compound such as transferrin or hemin. [17,18] The mechanism by which IDA causes thrombocytopenia is quite controversial and several hypotheses were suggested. Severe IDA may interfere with folic acid and vitamin B_{12} utilization at the cellular level as suggested by observed megaloblastic changes in the bone marrow of patients with severe IDA despite normal serum B_{12} and folic acid level.[12] Moreover, hypersegmented neutrophils were seen in 3 patients with IDA having normal serum folate and borderline or normal B_{12} level. Interestingly, the increased neutrophil segmentation was corrected with iron repletion.[17,18] Another possible explanation is that thrombocytopenia may be related to superimposed deficiencies of vitamin B_{12} ,[19] folic acid[20] or ascorbic acid.[21] In another experiment it was noted that rats rendered iron deficient showed diminished absorption of vitamin B_{12} .[22] In this regard several investigators have noted that gastric atrophy and achlorhydria occurs late in the course of hypochromic anemia. [23,24] In addition changes in small bowel characterized by pallor, atrophy and local inflammation[25] were also observed in patients with severe IDA.

Finally, splenomegaly and increased sequestration of red cells in the spleen have been demonstrated in animals and humans with IDA26-28 and hypersplenism may be responsible at least in part for thrombocytopenia in IDA. The stimulatory effect of iron therapy on platelets count in patient with IDA make the association of IDA and thrombocytopenia representing a cause and effect relationship. The pattern of platelets rise in IDA following iron replacement (both parenteral and oral) was studied. The platelets rose with the reticulocytes and returned

to the normal levels during the same period of time. In those patients who received parenteral iron, the peak response occurred in 3-6 days (mean 4.5 days) following the start of parenteral iron and then the platelets returned back to normal levels.[29] Patient who received oral iron therapy showed initial decline followed by rise in platelet count. The peak rise in platelet count was seen 20 days following the start of oral therapy.[29] In the latter study the rise in platelet count occurred irrespective to the initial count. One patient had pretreatment platelet count of 750 x 109/L which raised to 1350 x 109/L following a single parenteral iron dose. Initial decrease in platelets count following initiation of iron therapy for the patients with IDA was observed both in pediatric[8] and adult patients.[29,30] The decline in platelets count was explained by the imbalance between the 2 iron related functions leading to initial drop followed by rise in platelets count. The bleeding tendency in both patients in this report was significant, but the platelet count was not severe enough to be blamed as a sole factor in creating bleeding tendency. A brittle and unhealthy mucous membrane caused by iron deficiency could be a cofactor in mucosal bleeding tendency. In one study patients with IDA, the stools were positive for occult blood and shortly following iron therapy the stool became negative.[29]

In addition to thrombocytopenia, patient 3 had leucopenia. Leucopenia has been reported in IDA. In a review of 100 cases in Mayo Clinic 14% were found to have leucopenia.[31] In our case, leucocytes count normalized one day following transfusion.

Leucocytes response to packed RBC transfusion has been shown before, patient with acute lymphocytic leukemia who were hypertransfused with packed RBC showed more enhanced leucocytes recovery following induction with chemotherapy in comparison with similar patients who were treated with traditional transfusion regimen.[32]

Acknowledgment. We would like to thank Dr. Mouhammed Kelta, Dr. Zainab Fawzi and Dr. Asma Al-Hassan for their active participation in doing this article and Mr. K. Daniel for his assistance.

References.

1. Smith PJ, Jackson CW, Whidden MA, Edwards CC. Effect of hypertransfusion on bone marrow regeneration in sub-lethally irradiated mice. Enhanced recovery of megakaryocytes and platelets. ***Blood*** 1980; 56: 58-63.
2. Bradley TR, Robinson W, Metcalf D. Colony production in vitro by normal, polycythemic and anemic bone marrow. ***Nature*** 1967; 214: 511-513.
3. Hellman S, Grate H. Hematopoietic stem cells: Evidence for competing proliferative demands. ***Nature*** 1967; 216: 65-68.
4. Lawrence JS, Craddock CG Jr. Stem cell competition: The response to antineutrophilic serum as affected by haemorrhagia. ***J Lab Clin Med*** 1968; 72: 731-733.
5. Metcalf D. The effect of bleeding on the number of in vitro colony forming cells in the bone marrow. ***Br J Haematol*** 1969; 16: 397-399.
6. Morley A, Howard D, Bennett B, Stohlman F Jr. Studies on the regulation of granulopoiesis II. Relationship to other differentiation pathways. ***Br J Haematol*** 1970; 19: 523-526.
7. Gross S, Keefer V, Newman AJ. The platelets in iron deficiency anemia. I. The response to oral and parenteral iron. ***Pediatrics*** 1964; 34: 315-323.
8. Benttler E, Lichtman MA, Coller BS, Kipps TJ. Iron deficiency. William Text Book of Haematology. 5th Ed. New York (NY): McGraw Hill; 1995. p. 497.
9. Sonneborn D. Thrombocytopenia and Iron Deficiency. ***Ann Intern Med*** 1974; 80: 111.
10. Scher H, Silber R. Iron responsive thrombocytopenia. ***Ann Intern Med*** 1976; 84: 571-572
11. Dincol K, Aksoy M. On the platelet levels in chronic iron deficiency anemia. ***Acta Haematol*** 1969; 41: 135-143.
12. Heath CW, Patek AJ. The anemia of iron deficiency. ***Medicine*** 1937; 5: 267-350.
13. Lopas H, Rabiner SF. Thrombocytopenia associated with iron deficiency anemia: A report of five cases. ***Clin Pediatr*** 1966; 5: 609-616.
14. Vossough P, Leikin S, Purugganan G. Evaluation of parameters of folic acid and vitamin B12 deficiency in patients with iron deficiency anemia. ***Pediatr Res*** 1968; 12: 179-186.
15. Garg SK, Amorosi EL, Karpatkin S. Use of the mega-thrombocyte as an index of megakaryocyte number. ***N Engl J Med*** 1971; 28: 11-17.
16. Karpatkin S, Garg S, Freedman ML. Role of iron a regulator of thrombopoiesis. ***Am J Med*** 1974; 57: 521-525.
17. Freedman ML, Karpatkin S. Requirement of iron for platelet protein synthesis. ***Biochem Biophys Res Commun*** 1973; 54: 475-478.
18. Beard MEJ, Weintraub LR. Hypersegmented neutrophilic granulocytes in iron deficiency anemia. ***Br J Haematol*** 1969; 16: 161-163.
19. Paddock FK, Smith KE. The platelets in pernicious anemia. ***Am J Med Sci*** 1989; 198: 372.
20. Luhby AL. Megaloblastic anemia in infancy, III. Clinical considerations and analyses. ***J Pediatr*** 1969; 54: 617-619.
21. Vilter RW, Woolford RM Spies TD. Severe scurvy. A clinical and hematological study. ***J Lab Clin Med*** 1946; 31: 609-611.
22. Yeh SDJ, Gabriel AR, Chow BF. Absorption of vitamin B_{12} by iron deficient rats (Abstract). ***Fed Amer Soc Exp Biol*** 1961; 451: 20.
23. Davidson WMB, Markson JL. Gastric mucosa in iron deficiency anemia. ***Lancet*** 1955; 2: 639-641.
24. Badenoch J, Evans JR, Richards WCD. The stomach in hypochromic anaemia. ***Br J Haematol*** 1957; 3: 172-173.
25. Schmehle E, Schmid H. Uber serum farbkurven bei pernizioser und einfach achylischer anamie. ***Klin Wochenschr*** 1939; 14: 675-676.
26. Beard MEJ, Johnson SAN. Thrombocytopenia and iron deficiency anemia in a patient with a1 thalassaemia trait: Response to iron therapy. ***Acta Haematol*** 1978; 59: 114-118.
27. Rodvien R, Tavassoli M, Crosby WH. The structure of spleen in experimentally induced iron deficiency anemia. ***Am J Pathol*** 1974; 75: 243-249.
28. Beveridge BR, Bannerman RM, Evanson JM, Witts LJ. Hypochromic anemia: A retrospective study and follow-up of 378 in-patients. ***Q J Med*** 1964; 34: 145-161.
29. Krizley H, Noyes WD. Iron deficiency anaemia, papilledema, thrombocytosis and transient hemiparesis. ***Arch Intern Med*** 1972; 129; 483-486.
30. Soff G, Levin J. Thrombocytopenia associated with repletion of iron in iron deficiency anaemia. ***Am J Med Sci*** 1988; 295; 35-38.
31. Smith PJ, Ekert H. Evidence of stem cell competition in children with malignant disease. A controlled study of hypertransfusion. ***Lancet*** 1976; 1: 776-779.
32. Toogood IRG, Ekert H, Smith PJ, Firkin FC. Controlled study of hypertransfusion during remission induction in childhood acute lymphocytic leukaemia. ***Lancet*** 1978; 2: 862-866.