# The effects of melatonin on focal cerebral ischemia-reperfusion model

*Ahmet Kavakli, MD, PhD, Engin Sahna, PhD, Hakan Parlakpinar, MD, Seyfettin Yahsi, MD, Murat Ogeturk, MD, PhD, Ahmet Acet, MD.*

The brain is highly susceptible to focal ischemia. Thromboembolic occlusion of the artery is the most important cause of focal ischemia in patients. In brain ischemia, cerebral blood flow is reduced in brain regions that are supplied with oxygen by the occluded vessels. In addition to the lack of blood flow and oxygen delivery, the restoration of blood flow has also been reported to contribute to cell damage due to the generation of free radicals. Over production of free radicals is important in the pathogenesis of the cerebral damage induced by ischemia-reperfusion (I/R).[1] Melatonin has many properties of an ideal neuro protectant against I/R injury; excellent tissue diffusion to achieve adequate local concentrations, no serious toxicity even at high doses, and active against multiple pathophysiological mechanisms.[2] The purpose of the present study was to evaluate the effects of melatonin on histopathological changes resulting from I/R of the middle cerebral artery (MCA) an in vivo rat model.

***Experimental group.*** Male wistar rats weighing 200-300g were purchased from the Experimental Research Unit, Erciyes University, Kayseri, Turkey, and housed in individual cages in the animal laboratory of Firat University, Turkey. All the protocols in the present study were performed according to the guidelines of the local ethics committee. The investigations were carried out in 16 male wistar rats, divided into 2 groups, I/R and I/R+melatonin. A control group of rats received an intraperitoneal injection of vehicle (normal saline) at the onset of middle cerebral artery occlusion (MCAO). Ischemia-reperfusion+melatonin group rats received melatonin (10mg/kg body weight per 1ml 10% ethanol i.p.; Sigma Chemical Co., St. Louis, MO, United States of America) 30 minutes before ischemia. Rats were anesthetized with i.p. ketamine hydrochloride (75mg/kg) and xylazine (8mg/kg) before the operation. Body temperature was maintained close to 37$^0$C by a heating pad.

***Middle cerebral artery occlusion.*** Occlusion of the right MCA was performed by a nylon filament as described previously.[3] Middle cerebral artery was occluded for 60 minutes followed by 24h reperfusion. Briefly, the right common carotid artery was exposed through a midline incision and carefully dissected from the surrounding tissue using microsurgery technique. The external carotid artery (ECA) was dissected further distally and coagulated along with the occipital and superior thyroid artery branches, which were then divided. The internal carotid artery (ICA) was isolated and carefully separated from the adjacent vagus nerve, and the pterygopalatine artery was ligated close to its origin with a 7-0 silk suture. Next, a 7-0 silk suture was tied loosely around the mobilized ECA stump, and a piece of 4-0 monofilament nylon suture, with its tip rounded by gentle heating, was inserted into the lumen of the right ECA stump and gently advanced via the right ICA to embed into the right anterior cerebral artery so that the right middle cerebral artery was occluded at its origin. Reperfusion was accomplished by pulling the filament.

***Histopathological examination of the brain.*** At the end of reperfusion, all rats were sacrificed and the brains were quickly removed, and was placed in neutral formalin (10%) and then cut into 2mm thick coronal slices for routine histopathological examination by light microscopy. Sections (5μm-thick) from the paraffin-blocks were stained with hematoxylin-eosin. Structural alterations in the brain tissues were determined as semi-quantitative + sign (0: absent, +: slight, ++: moderate, +++: severe).

In this light microscopy study, widespread necrotic areas, red neurons, vacuolization, congestion and edema were observed in the cerebral cortex in I/R group. In the melatonin group, findings of ischemia were not widespread and necrotic areas were absent. The light microscopic results were shown in **Table 1** and **Figure 1**.

Cho et al[2] administered melatonin at the beginning of cerebral reperfusion, which was

**Table 1** - Light microscopic findings in the brain tissue of group I (I/R) and group II (I/R+melatonin) rats (n=8 in each group).

| Light microscopic findings | I/R (control) | I/R+melatonin |
|---|---|---|
| Necrotic areas (infarct) | ++ | 0 |
| Eosinophilic degeneration (red neurons) | +++ | + |
| Edema | +++ | + |
| Vacuolization | +++ | + |
| Congestion | ++ | + |

I/R - ischemia-reperfusion, n - number, 0 - absent, + - slight, ++ - moderate, +++ - severe

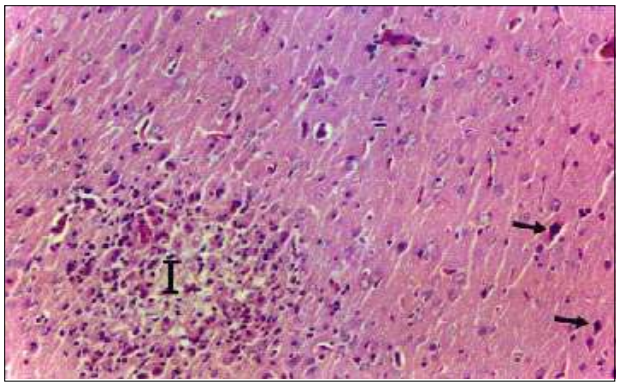


**Figure 1 -** Ischemia-reperfusion group: red neurons (arrows) and infarct (I) area are seen (hemoxylin eosin x100).

protected cornu ammonis (CA1) hippocampal neurons against 10, 20, 30 minutes of transient forebrain ischemia. Intraperitoneal injections of melatonin (10mg/kg) were given after 0, 2 and 6h or 1, 2 and 6h of cerebral reperfusion, or 30 minutes prior to ischemia. There was a trend toward significant CA1 protection in animals that were pre-treated with melatonin 30 minutes before ischemia. In our study we, too, administered melatonin 30 minutes prior to ischemia. We observed that melatonin ischemic protection had an effect on brain (I/R +++, I/R+melatonin +). Pei et al[4] put a single dose of melatonin into practice (1.5, 5, 15 or 50mg/kg) via an intraperitoneal injection at 30 minutes before MCAO. Relative infarction volumes were reduced in the groups treated with melatonin at 5 or 15mg/kg but not at 1.5 or 50mg/kg compared with the vehicle group. Their results indicate that the melatonin at a dose between 5 and 15mg/kg protects against focal cerebral ischemia. Our results indicate that pre-treatment with melatonin at single dose 10mg/kg i.p. protects the cerebral cortex focal cerebral ischemia. According to Gupta et al,[5] enhanced protection is observed with the use of melatonin at a dose of 20mg/kg in the MCAO model of acute ischemic stroke in rats. Torii et al[6] administered melatonin twice (6mg/kg) just to one hour of MCAO and one day after the surgery. In the melatonin-treated group especially the cerebral cortex, total volume of edema was reduced by 59.8% when compared with the control group. In our study we observed (+++) severe in the control group of edema; while (+) slight in the melatonin treated group.

In conclusion, our results show the beneficial effects of melatonin in the prevention of I/R induced damage in rats, and suggest that it would seem to test melatonin in further studies for prevention of possible I/R-induced damage. It was determined that a single dose of exogen melatonin in neuro-protective had an effect especially in pre-treatment. This result has a similarity with the one single dose of exogen melatonin studies, which had been carried out before. It must be thought how the endogen and exogen melatonin had an effect on the brain ischemic damage and what kind of difference would be between them in the studies, which are planned to be held in the future. It ought to be thought and planned that the question of what kind of result will be taken especially in the situation where there is no endogen melatonin hormone.

*Received 27th April 2004. Accepted for publication in final form 12th June 2004.*

*From the Departments of Anatomy (Kavaklı, Ogeturk), Pharmacology (Sahna), and Pathology (Yahsi), School of Medicine, Fırat University, Elazıg, Department of Pharmacology (Parlakpinar, Acet), School of Medicine, Inonu University, Malatya, Turkey. Address correspondence and reprint requests to Asst. Prof. Ahmet Kavakli, Firat University, Faculty of Medicine, Department of Anatomy, 23119 Elazig, Turkey. Tel. +90 (424) 2370000. Fax. +90 (424) 2379138. E-mail: kavaklia@hotmail.com*

## *References*

1. Chan PH. Reactive oxygen radicals in signaling and damage in the ischemic brain. ***J Cereb Blood Flow Metab*** 2001; 21: 2-14.
2. Cho S, Joh TH, Baik HH, Dibinis C, Volpe BT. Melatonin administration protects CA1 hippocampal neurons after transient forebrain ischemia in rats. ***Brain Research*** 1997; 755: 335-338.
3. Longa EZ, Weinstein PR, Carlson S, Cummins R. Reversible Middle cerebral Artery Occlusion Without Craniectomy in Rats. ***Stroke*** 1989 ; 20 : 84-91.
4. Pei Z, Pang SF, Cheung RT. Pretreatment with melatonin reduces volume of cerebral infarction in a rat middle cerebral artery occlusion stroke model. ***J Pineal Res*** 2002; 32: 168-172.
5. Gupta YK, Chaudhary G, Sinha K. Enhanced protection by melatonin and meloxicam combination in a middle cerebral artery occlusion model of acute ischemic stroke in rat. ***Can J Physiol Pharmacol*** 2002; 80: 210-217.
6. Torii K, Uneyama H, Nishino H, Kondoh T. Melatonin suppresses cerebral edema caused by middle cerebral artery occlusion/reperfusion in rats assessed by magnetic resonance imaging. ***J Pineal Res*** 2004; 36: 18-24.