

Idiopathic granulomatous mastitis

Clinical presentation, radiological features and treatment

Saleh M. Aldaqal, FRCSI, SBGS.

ABSTRACT

Objective: To determine the clinical characteristic, clinical presentations and radiological features of idiopathic granulomatous mastitis, and the best treatment approaches of this clinical entity.

Methods: Between 1996 and 2003 the files and histopathology reports of 25 patients with granulomatous mastitis at King Abdul-Aziz University Hospital, Jeddah, Kingdom of Saudi Arabia were reviewed. The data were analyzed and a Medline search was carried out from 1970 to 2003 to review relevant cases.

Results: The age of patients ranged from 24-66 years and the mean age was 36.6 ± 9.43 years. All patients were females. The most common clinical presentation was palpable tender mass. The most common mammographic finding was ill-defined mass. However,

mixed hypo- and hyper-echogenic lesions with tubular connections were the common ultrasonic findings. Treatment approaches were conservative or surgical excision or steroid. Conservative treatment associated with the higher rate of complications, while treatment with steroid showed complete remission of the disease.

Conclusion: Idiopathic granulomatous mastitis is a rare, benign breast disease that is usually underestimated or misdiagnosed. The clinical and radiological features resemble those of infectious mastitis or breast carcinoma. Early recognition and initiation of steroid treatment will result in complete remission of the disease and might prevent complications.

Saudi Med J 2004; Vol. 25 (12): 1884-1887

Idiopathic granulomatous mastitis (IGM) is a rare, benign inflammatory breast disease of unknown etiology. Many investigators speculated a possibility of an autoimmune process.¹⁻² The clinical and radiological features mistaken frequently for infectious mastitis or breast carcinoma. This study designed to review the clinical presentation and radiological finding of this clinical entity in a series of 25 cases diagnosed in our hospital, and to review relevant cases published in the literature to determine the characteristic,

clinical presentations and radiological features of IGM, and the best treatment approaches of this clinical entity.

Methods. In this retrospective analysis, the records of 25 patients diagnosed with granulomatous mastitis at King Abdul-Aziz University Hospital, Jeddah, Kingdom of Saudi Arabia, between 1996 and 2003 were reviewed. The data collected includes patient's demography, clinical presentation, initial diagnosis,

From the Department of Surgery, King Abdul-Aziz University Hospital, Jeddah, *Kingdom of Saudi Arabia*.

Received 5th July 2004. Accepted for publication in final form 14th August 2004.

Address correspondence and reprint request to: Dr. Saleh M. Aldaqal, Department of Surgery, King Abdul-Aziz University Hospital, PO Box 80215, Jeddah 21589, *Kingdom of Saudi Arabia*. Tel. +966 (2) 6408346. Fax. +966 (2) 6408347. E-mail: sdaqal@health.net.sa

mammographic and ultrasonic findings, magnetic resonance imaging findings if it is carried out, any associated diseases, histopathology results and fine needle aspiration (FNA) results if it is carried out, and the treatment which was received and the follow up of the results. The data were analyzed to determine the characteristics, clinical presentations and radiological features of IGM, and the best treatment approaches of this clinical entity. A Medline search was carried out from 1970 to 2003 to review relevant cases.

Results. The age of patients ranged from 24-66 years and the mean was 36.6 ± 9.43 . All patients were females. They were uniformly multi-parous. Clinical presentations were palpable tender mass in 16 cases, and palpable non-tender mass in 9 cases. Skin changes were noted in 7 cases. The size of the lesion ranges from 1-10 cm; mean 4.88 ± 2.78 . In 25 cases, 4 patients were lactating at time of the diagnosis, 3 patients were pregnant, and 3 patients were post-menopause. The disease was associated with erythema nodosum and polyarthritis in one patient, and Hashimoto's thyroiditis in one patient. Prior to biopsy, the clinical diagnosis in 10 cases was breast carcinoma, breast abscess in 10 cases, and infectious mastitis in 5 cases. Mammographic examination showed an ill-defined mass in 12 patients and asymmetric density in 8 patients. Skin thickening was noted in 3 cases (mammography was not carried out in 5 cases). Sonographic examination demonstrated mixed hypo- and hyper-echogenic lesions with tubular connections in 16 cases, and hypoechoic lesion in 5 cases; ultrasound was not carried out in 4 cases (Table 1). Magnetic resonance imaging was carried out in 2 patients who showed focal homogenous enhancing

masses with irregular borders, these finding were compatible with mastitis or malignancy. In 25 cases, the disease was diagnosed by FNA in 15 cases and confirmed by open biopsy in all cases. In 25 cases, 15 patients were treated conservatively with antibiotics and drainage of abscess, 4 patients had surgical resection of the lesion, and 4 patients were treated with steroid and 2 patients had spontaneous remission of the mass. In 15 cases that were treated conservatively, 6 patients had persistence of the mass, 5 patients had chronic suppurations, 3 patients had recurrences, and one patient had breast deformity. Four patients were treated by surgical excision, one patient had recurrence of the lesion. However, there were no recurrences or complications observed in 4 patients that were treated with steroid (Table 2).

Discussion. Idiopathic granulomatous mastitis is a rare, benign inflammatory breast disease of unknown etiology. Previous studies speculated a possibility of an autoimmune process.¹⁻² It is possible that damage to the ductal epithelium produced by local trauma, local irritant or infection, would allow luminal secretion to escape into the lobular connective tissue causing a granulomatous response with lymphocyte and macrophage migration. However, despite of extra investigation, all immunological and bacterial tests have been consistently negative.³⁻⁵ A literature review shows that IGM typically presents in reproductive age, parous women with mean age of 32 years (range 17-43).^{5,6} It was also reported in post-menopausal women and during pregnancy.¹ Clinically, it can mimic breast carcinoma or infectious mastitis with abscess formation. Usually, IGM presents with unilateral, firm, discrete tender mass, ranging from

Table 1 - Summary of the results.

| Findings | N of cases |
|--|------------|
| Clinical presentation (n=25) | |
| Palpable tender mass | 16 |
| Palpable non-tender mass | 9 |
| Clinical diagnosis prior to biopsy (n=25) | |
| Breast carcinoma | 10 |
| Breast abscess | 10 |
| Infectious mastitis | 5 |
| Mammographic examination (n=20) | |
| Ill-defined mass | 12 |
| Asymmetric density | 8 |
| Ultrasonic examination (n=21) | |
| Mixed hypo and hyper-echogenic lesion with tubular connections | 16 |
| Hypoechoic lesion | 5 |

Table 2 - Treatment and complications.

| Findings | N of cases |
|---|------------|
| Treatment (n=25) | |
| Conservative | 15 |
| Surgical excision | 4 |
| Steroid | 4 |
| Spontaneous remission | 2 |
| Complications post conservative treatment (n=15) | |
| Persistence of the mass | 6 |
| Chronic suppurations | 5 |
| Recurrence | 3 |
| Breast deformity | 1 |
| Complications post surgical excision (n=1) | |
| Recurrence | 1 |

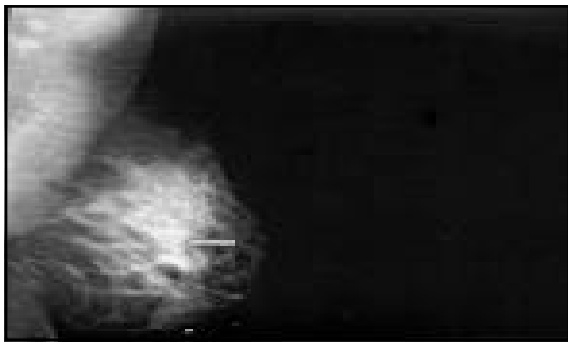


Figure 1

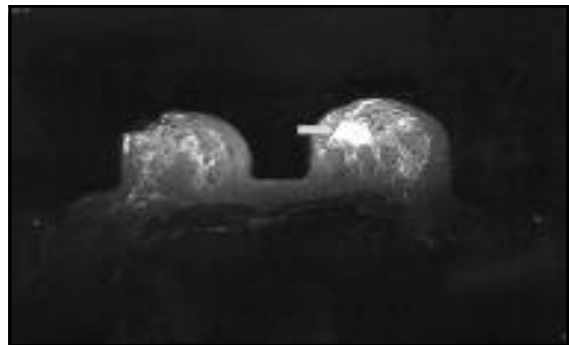


Figure 3

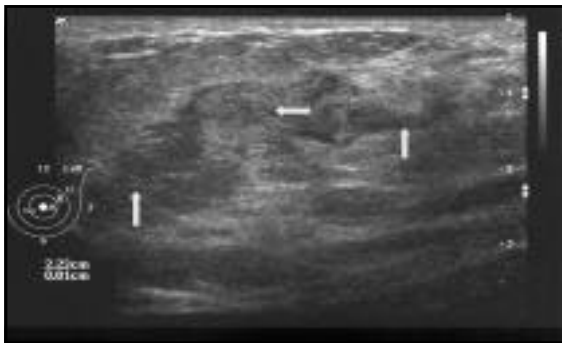


Figure 2

Figure 1 - Mammography of the left breast of one patient included in the study shows an ill-defined mass in the left breast. The patient is 39 year old, present with 2-3 cm palpable mild tender mass, the histopathology showed granulomatous mastitis.

Figure 2 - Ultrasound of the left breast of same patient, showed mixed hypo and hypoechogenic lesion with tubular connections.

Figure 3 - Magnetic resonance imaging of the both breast of same patient, showed focal homogenous enhancing masses with irregular borders.

0.5-10 cm in size with overlying skin often inflamed.^{5,7,8} But, sometimes it could presents with non-tender mass or pain alone.³ The nipple inversion may be present. Moreover, it could be associated with erythema nodosum or polyarthritis.¹ In our study, the disease was associated with Hashimoto's thyroiditis in one patient; this is the first report describing this association.

Mammography usually shows an ill-defined mass with surrounding normal breast parenchyma or irregular asymmetric density, and skin thickening³ (**Figure 1**). However, ultrasonic examination commonly demonstrates a non-mass lesion or hypoechoic lesion that is often tubular or is associated with a tubular portion or mixed hypo- and hyperechogenicity lesions³ (**Figure 2**). Magnetic resonance imaging findings in patient with IGM was described in 2 reports in the literature, which showed focal homogenous enhancing masses with irregular borders, these findings were compatible with mastitis or malignancy (**Figure 3**).

The histopathology of IGM shows discrete, non-caseating granulomas with acute and chronic inflammatory cells (**Figure 4**). It has to be differentiated from other causes of granulomatous mastitis as tuberculosis and sarcoidosis. Tuberculosis of the breast presents with caseating granulomas and acid-fast bacilli, whereas

sarcoidosis presents with non-caseating epithelioid granulomas, which often separate from breast lobules and ducts, centered in a perivascular arrangement with accompanying lymphocytic inflammation and devoid of neutrophils.^{1,9} In our study, the disease was diagnosed by FNA in 15 cases, we suggest that FNA alone can be diagnostic, but require further investigation (**Figure 5**).

Diagnosis of IGM is made clinically and by biopsy, and only after other possibilities have been excluded, especially breasts carcinoma and other known causes of granulomatous diseases as tuberculosis, sarcoidosis, fungal infection and foreign body reaction.²⁻⁸ Breast carcinoma can be ruled out by biopsy, while cultures and stains can be excluding acid-fast microorganism, bacterial and fungal infection. The natural history of IGM is that of a self-limited condition with no reported fatalities. In 50% of the cases, uneventful recovery is achieved. However, the other half is complicated by persistence, recurrence and development of complications as chronic suppuration and fistulae.² The optimal treatment of IGM is not well defined. The conservative treatment with antibiotics and drainage of abscess usually unsuccessful, it is commonly associated with a higher rate of recurrence and complications as chronic suppuration and breast deformity. Current literature suggests

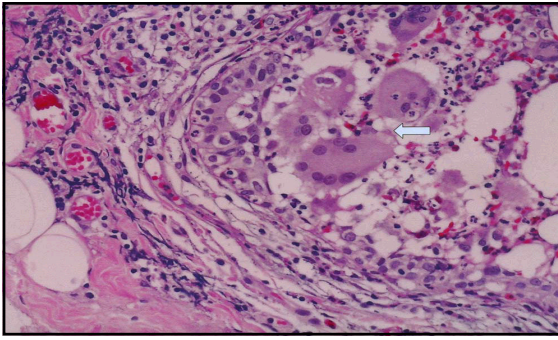


Figure 4 - Histopathology of the mass which was excised from the same patient, showed multiple granulomas composed of epithelioid histiocytes, lymphocytes and multinucleated giant cells. The rest of the breast tissues reveal severe acute and chronic inflammation. No evidence of malignancy. The finding consistent with granulomatous mastitis.

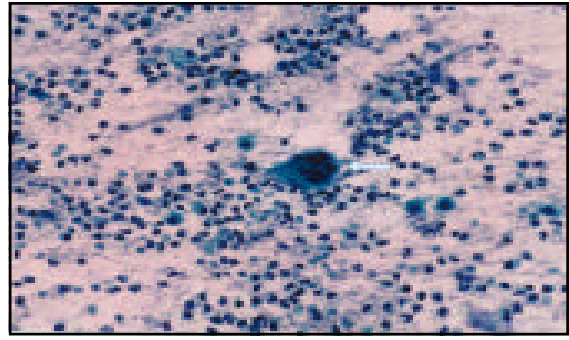


Figure 5 - Fine needle aspiration of the mass from the same patient, showed multinucleated giant cells, epithelioid cells, and dense lymphocytic infiltration consistent with granulomatous mastitis.

surgical resection of the lesions, when possible or initial open biopsy. If there are no improvement and recurrence or complications occur, a corticosteroid therapy should be started to give complete remission.^{2, 5-7}

In conclusion, IGM is a rare, benign breast disease that is usually underestimated or misdiagnosed. The clinical and radiological features resemble those of infectious mastitis or breast carcinoma. Early recognition and initiation of steroid treatment will result in complete remission of the disease and might prevent complications as chronic suppurations and breast deformity.

Acknowledgment. I gratefully acknowledge the help of Ms. Nora N. Yusuf in computer works.

References

1. Goldberg J, Baute L, Storey L, Park P. Granulomatous mastitis in pregnancy. *Obstet Gynecol* 2000; 96 (5 Pt 2): 813-815.

2. Schelfout K, Tjalma W, Cooremans I, Coeman D, Colpaert C, Buytaert P. Observations of an idiopathic granulomatous mastitis. *Eur J Obstet Gynecol Reprod Biol* 2001; 97: 260-262.
3. Cho K, Choi H, Lee S, Rhee C. Characteristic mammographic and sonographic findings in the diagnosis of granulomatous mastitis. *Ultrasound Med Biol* 2003; 29: S175.
4. Salam IM, Alhomsy MF, Daniel MF, Sim AJ. Diagnosis and treatment of granulomatous mastitis. *Br J Surg* 1995; 82: 214.
5. Van Ongeval C, Schraepen T, van Steen A, Baert AL, Moerman P. Idiopathic granulomatous mastitis. *Eur Radiol* 1997; 7: 1010-1012.
6. DeHertogh DA, Rossof AH, Harris AA, Economou SG. Prednisone management of granulomatous mastitis. *N Engl J Med* 1980; 303: 799-800.
7. Jorgensen MB, Nielsen DM. Diagnosis and treatment of granulomatous mastitis. *Am J Med* 1992; 93: 97-101.
8. Kessler E, Wolloch Y. Granulomatous mastitis: a lesion clinically simulating carcinoma. *Am J Clin Pathol* 1972; 58: 642-646.
9. Fitzgibbons PL, Smiley DF, Kern WH. Sarcoidosis presenting initially as breast mass: Report of two cases. *Hum Pathol* 1985; 16: 851-852.