

# Assessment of electrotherapy in treatment of hemorrhoids in Southern Iran

Ahmad Izadpanah, MD, Seyed-Vahid Hosseini, MD, Davood Mehrabani, PhD, Alimohammad Bananzadeh, MD.

## ABSTRACT

**Objectives:** In this study, we have developed an electrotherapy device in order to improve the outcome and decrease the number of referrals and duration of treatment of internal hemorrhoid.

**Methods:** We treated 2015 hemorrhoids among 931 patients (382 males and 549 females); 319 hemorrhoids were grade 1, 1158 grade 2 and 538 grade 3, from May 1995 to October 2002, at Nemazee and Faghihee Hospitals in Shiraz University of Medical Sciences, Shiraz, Iran. All patients were referred due to fresh rectal bleeding or reducible prolapsed hemorrhoid with no response to medical treatment. After introduction of anesthesia, 27-30 mAmp direct current was applied to each hemorrhoid with durations of 4.5 minutes for grade 1, 5.5 minutes for grade 2 and 7 minutes for grade 3.

**Results:** Our results showed that 97.1% of patients responded well to the treatment and 27 patients returned

with fresh rectal bleeding or prolapsed hemorrhoid in 2 weeks to 2 months postoperatively. Ninety-six percent of the patients were discharged on the same operating day. After 24 hours postoperation, 92% of the patients had no any pain and no need any analgesic. Among those patients who had not responded to the treatment; 24 cases underwent electrotherapy for a 2nd time and 3 patients were treated excising their prolapsed hemorrhoids. No other complications were detected.

**Conclusion:** Postoperative pain was mild and tolerable and 93.2% of patients returned to normal activity after 2 days. Electrotherapy with the above mentioned method is considered safe and effective without any major complications and with acceptable patient's satisfaction. This method can be used for treatment of grades 1, 2 and 3 hemorrhoids.

Saudi Med J 2004; Vol. 25 (12): 1896-1899

After conventional hemorrhoidectomy, which is considered as a standard and effective method, patients experience severe pain and may develop several complications.<sup>1,2</sup> To prevent postoperative complications and eliminate pain, many physicians have sought other ways to treat hemorrhoids.<sup>3-8</sup> Although most of them have not demonstrated consistent improvement in postoperative pain when compared with the standard technique.<sup>9-13</sup> Electrotherapy of hemorrhoid is a method, which is claimed to be safe and painless. This method was suggested in 1867, and applied by different

instruments.<sup>8</sup> The success rate of this modality was reported to be between 66-88% with the first application.<sup>8,14-16</sup> This method was used as an outpatient treatment without anesthesia, but 20% of the patients could not tolerate the operation and 16% experienced prolonged pain.<sup>8,17</sup> The mean number of re-treatment of hemorrhoid segments was reported to be 2.22 for grade 1, 2.42, for grade 2 2.76 for grade 3, and 3.44 for grade 4.<sup>8,16,17</sup> For treatment of each hemorrhoid, direct current (DC) was applied for 8-12 minutes in each session.<sup>8,15,17</sup> In this study, we have developed an electrotherapy

From the Division of Colorectal Surgery, Department of Surgery and Gastroenterohepatology Research Center (Izadpanah, Hosseini), Department of Pathology, Transplant Research Center (Mehrabani), Shiraz University of Medical Sciences and the Department of Surgery (Bananzadeh), Shiraz University of Medical Sciences, Shiraz, Iran.

Received 30th May 2004. Accepted for publication in final form 21st August 2004.

Address correspondence and reprint request to: Dr. Ahmad Izadpanah, Associate Professor of General Surgery, Division of Colorectal Surgery, Department of Surgery, Faghihi Hospital, Shiraz University of Medical Sciences, PO Box 71345-1853, Shiraz, Iran. Tel. +98 (711) 2294545. Fax. +98 (711) 2330724. E-mail: izadpana@sums.ac.ir

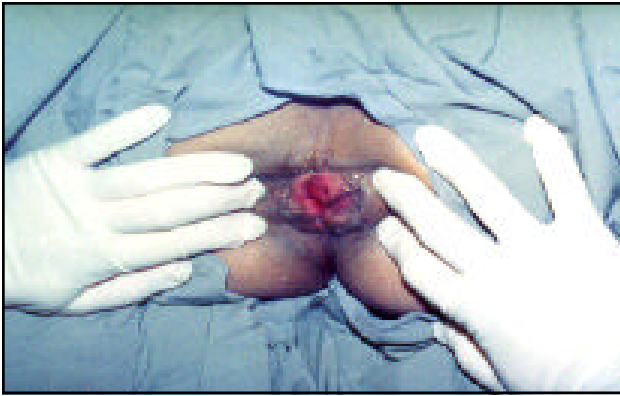

Figure 1 - Size and site of all tags were distinguished.

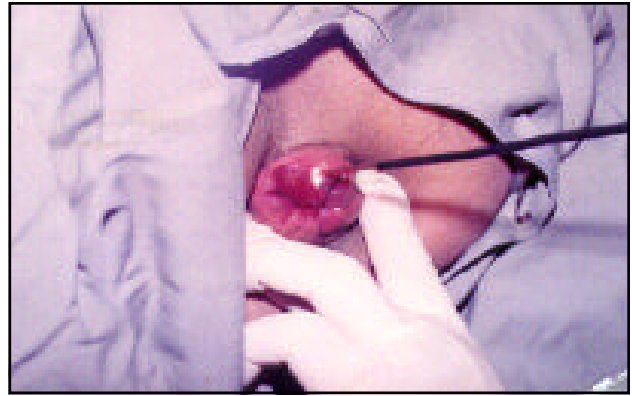


Figure 2 - Negative probe in hemorrhoidal tissue, gas bubbles come through the site of probing.

device in order to improve the outcome and decrease the number of referrals and duration of treatment for each segment.

**Methods.** From May 1995 to October 2002, we treated 2015 hemorrhoids among 931 patients (382 males and 549 females), 319 hemorrhoids were grade 1, 1158 were grade 2 and 538 were grade 3. All patients were referred due to fresh rectal bleeding or reducible prolapsed hemorrhoid with no response to medical treatment. The method was discussed with patients and an informed consent was obtained. Patients were informed that they might need more than one operation if there was no response to the first operation and were brought to the operating room as outpatients and with no bowel preparation. After introduction of general or spinal anesthesia, upon anesthesiologist's preference were examined in Telendelenberg position by using speculum, and the number, size and site of all tags were distinguished (**Figure 1**) and recorded in a special form. Patients with grade 4 hemorrhoids, anal fissures, previous anorectal operations or any other anorectal diseases were excluded. Thereupon, the positive plate of the device was put under the buttocks of the patient and the negative probe (like a needle which is changeable) was inserted into the hemorrhoid at approximately one centimeter deep (**Figure 2**). The current increased gradually from 0 to maximum. Afterwards, 27-30 mAmp DC was applied to each hemorrhoid with durations of 4.5 minutes for grade 1, 5.5 minutes for grade 2 and 7 minutes for grade 3 according to the timetable, which we had from our previous study.<sup>18</sup> All hemorrhoids were attempted to be treated in the first session. The treatment was terminated either at the end of above-mentioned timetable or if the gas bubbles stop (**Figure 2**) through the probing site or stiffness of the hemorrhoid. If the skin tag was present, it was excised. Patients were discharged a few hours post-operation except for those who had

surgical or medical problems that had to be kept under observation. No antibiotic was administered for the patients.

Two weeks and 2 months later, the patients were asked of any postoperative symptoms and were examined with an anoscope to determine the result of treatment. The hemorrhoid should be disappeared after 2 weeks and patients were randomly followed by one of our senior residents. After that, they were requested to refer to our clinic if they developed any signs or symptoms. Follow up period was 6-90 months (mean of 50 months). The cost of operation was approximately half of the cost of conventional hemorrhoidectomy in our hospitals.

**Results.** From 931 patients who underwent electrotherapy, 904 patients (97.1%) responded well to the treatment and 27 patients (2.9%) returned with fresh rectal bleeding or prolapsed hemorrhoid in 2 weeks to 2 months postoperatively. Anoscopy was performed and revealed that 51 hemorrhoids had remained in those who had not responded to treatment. Twenty-four cases underwent electrotherapy again and 3 patients were treated by excision of their hemorrhoids due to non-reducible prolapsed hemorrhoids. Out of 24 patients, 9 patients continued with bleeding or the hemorrhoids did not disappear, and therefore they underwent hemorrhoidectomy. Ninety-six percent of the patients were discharged on the same operating day, and 41 patients had 2-5 days (mean of 2.7 days) hospital stay due to surgical complications such as pain or prolapsed hemorrhoid or medical status. We used categorical scale for determination of pain intensity.<sup>19</sup> All patients ceased to have moderate to severe anal pain (due to insertion of speculum and operation) a few hours after operation. All patients had one injection of 50 mg pethidine in this period of time. Forty percents of patients continued to have mild pain for the first 24 hours and 8% (82

patients) for 2-8 days as such that they had to take 2-3 tablets of 25 mg diclofenac Na orally or sitz-bath. After 6 hours of operation, 52% of patients and after 24 hours 92% of patients had no any pain and no need to take any analgesic. In the day 2, 8% of the patients; in the day 3, 4% and in the day 7, 1% of them had mild pain and had to take diclofenac Na as analgesic (25 mg 3 times per day). Among 1% of patients, we had to repeat the injection of pethidine (50 mg intramuscularly) because of having moderate to severe pain in first postoperative day and 93.2% of the patients started their ordinary job in 2 days and 5% of them up to sixth day after operation. However, 1.8% of the patients had to stay home up to 2 weeks due to pain and discomfort. Forty-three percent of the patients reported few drops of bloody discharge on the fifth to seventh postoperative days. Urine retention was developed in 6% of the patients who needed one time catheterization and 2% needed 2-3 times catheterization.

During the follow up of 1-7 years, 71 of the patients had referrals due to anal pain, bleeding or itching. Anoscopy and sigmoidoscopy revealed new grade 1 or 2 hemorrhoids in 52 and fissures in 17 patients. Two of the patients had nonspecific colitis. No other complications such as anal stricture, incontinence or infection were observed among patients. Satisfaction of the patients was determined according the criteria in **Table 1**, which is not validated before. But we approved its validity in a pilot study. The patients were asked on their symptoms during the follow up period and their scores were determined. Among the patients, 1.2% had score of 4, 3.2% had scores of 5-8, 17.6% had scores of 9-12 and 78% had scores of 13-16.

**DISCUSSION.** The treatment of hemorrhoid is divided into medical and mechanical types.<sup>1-4,14,20,21</sup> If medical therapy is not effective, mechanical therapy should be selected. Conventional hemorrhoidectomy was known as standard treatment for hemorrhoidal disease but patients experienced severe postoperative pain and many of them were not able to return to their ordinary life or jobs, even up to a few weeks and developed some catastrophic complications. For these problems, other methods such as rubber band ligation, photocoagulation and electrotherapy were introduced as more comfortable methods with fewer complications. Electrotherapy was suggested as an outpatient treatment without anesthesia, but for prevention of pain during operation not more than 16 mAmp DC could be used.<sup>8,17</sup> Due to this restriction, the operating time for one segment was 8-12 minutes and the mean referral times for treating one segment was 2.2-3.68 times and only 54% responded to the first operating session and one segment had to be operated at each session.<sup>8,16,17</sup> To omit the above restrictions of electrotherapy, we operated our patients using 27-30 mAmp DC with anesthesia, treating all hemorrhoids in the same session. Using this method, the operating time was reduced to 3.5 minutes for grade 1, 4.5 minutes for grade 2 and 6 minutes for grade 3 hemorrhoids and among 24 patients (2.6%) electrotherapy was applied for the second time for hemorrhoids remaining 2 months postoperatively. In these patients, 46 hemorrhoidal segments (2.3%) were remained. Nine patients (<1%) did not respond to 2 sessions of electrotherapy and were treated by hemorrhoidectomy. Therefore, only 12 patients (1.3%) did not respond to this method. This means

Table 1 - Criteria for postoperatin patient's satisfaction.

Symptoms	4 Scores (%)	3 Scores (%)	2 Scores (%)	1 Scores (%)
Pain	No pain after 6 hours (52)	Mild pain for 2 days subsided by oral analgesics (92)	Mild pain for more than 2 days subsided by oral analgesics (7)	Pain for more than 2 days, not subsided by oral analgesics (1)
Bleeding	No bleeding (61)	Few drops on each bowel movement for 2-3 days (26)	Few drops on each bowel movement for one week (11)	Sustained bleeding such as preoperation (2)
Status of hemorrhoid	Not protruded at all (98.2)	Protruded up to 2 weeks later on defecation (1.8)	Protruded for more than 2 weeks on defecation (0.9)	Is protruded all the time (0.3)
Recurrence of the symptoms such as itching	No symptom at all (88.3)	Any preoperative symptom appeared after 6 months (7.5)	Any Preoperative symptom appeared after 3 months (1.3)	Persistent symptoms such as preoperation (2.9)
13-16 scores (excellent), 9-12 scores (good), 5-8 scores (poor), 1-4 (very poor).				

that the success rate in this study was 98.7%. In 3 patients we had to do resection of the treated hemorrhoids with electrotherapy, due to increase in the volume that caused prolapse and incarceration. In this method, the volume of each hemorrhoid will increased 2-3 times due to the release of H<sup>+</sup> and O<sup>-</sup> with electrolysis mechanism during the operation.<sup>8,17</sup> After the operation, the volume of the treated hemorrhoid decreased gradually as such that after 24 hours it was similar to pre-treatment. Then, the segment became smaller and smaller and after 2 weeks it disappeared completely. If a big hemorrhoid was near the dentate line, it might protrude through the anal canal after the operation. For this reason, we advised that the hemorrhoids to be pressed at the end of operation to be evacuated for the gases and to reduce the volume. In the follow up period, 52 patients (5.5%) developed new hemorrhoids, but no complication such as infection, ulceration or stricture was detected. In this method, postoperative pain was mild and tolerable and the patients needed small amounts of analgesics to relieve the pain and return to normal activity. In **Table 1**, the patient's satisfaction was determined, and was excellent and good in 95.6% and poor and very poor in 4.4% of the patients, some of them had to undergo another operation. Comparing the postoperative pain severity, complications and return to the normal life style in the patients treated by above mentioned electrotherapy method to the patients treated by conventional hemorrhoidectomy reported in literature,<sup>1,2,7,9,12,14,20,21</sup> showed the feasibility of this electrotherapy method.

We can conclude that electrotherapy with the above mentioned method is considered as an easy, safe, simple, comfortable, non-expensive and effective method without major complications and with excellent patient's satisfaction. This method can be used for treatment of grades 1, 2 and 3 hemorrhoids.

**Acknowledgment.** We would like to thank the Office of the Vice Chancellor for Research of Shiraz University of Medical Sciences, Shiraz, Iran for the financial support to this project. We would also like to thank Mr. Najib T. Aladeeb, medical student, for his accurate Arabic translation of the abstract and Miss Gholami in the Center for Development of Clinical Research at Nemazee Hospital for her cooperation and assistance in preparing this manuscript.

## References

- Ibrahim S, Tsang C, Lee YL, Eu KW, Seow-Choen F. Prospective randomized trial comparing pain and complications between diathermy and scissors for closed hemorrhoidectomy. *Dis Colon Rectum* 1998; 41: 1418-1420.
- Read MG, Read NW, Haynes WG, Donnelly TC, Johnson AG. A prospective study of the effect of hemorrhoidectomy on sphincter function and faecal continence. *Br J Surg* 1982; 69: 396-398.
- Orrom W, Hayashi A, Rusnak C, Kelly J. Initial experience with stapled anoplasty in the operative management of prolapsing hemorrhoids and mucosal rectal prolapse. *Am J Surg* 2002; 183: 519-524.
- Wexner SD. The quest for painless surgical treatment of hemorrhoids continues. *J Am Coll Surg* 2001; 193: 174-178.
- Altomare DF, Rinaldi M, Sallustio PL, Martino P, De Fazio M, Memeo M. Long-term effects of stapled hemorrhoidectomy on internal anal function and sensitivity. *Br J Surg* 2001; 88: 1487-1491.
- Sayfan J, Becker A, Koltun L. Sutureless closed hemorrhoidectomy: A new technique. *Ann Surg* 2001; 234: 21-24.
- Ho YH, Cheong WK, Tsang C, Ho J, Eu KW, Tang CL, et al. Stapled hemorrhoidectomy-cost and effectiveness. Randomized, controlled trial including incontinence scoring, anorectal manometry, and endoanal ultrasound assessment up to three months. *Dis Colon Rectum* 2000; 43: 1666-1675.
- Norman DA, Newton R, Nicholas GV. Direct current electrotherapy of internal hemorrhoids: an effective, safe and painless outpatient approach. *Am J Gastroenterol* 1989; 84: 482-487.
- Khan S, Pawlak SE, Eggenberger JC, Lee CS, Szilagy EJ, Wu JS, et al. Surgical treatment of hemorrhoids. Prospective, randomized trial comparing closed excisional hemorrhoidectomy and the harmonic scalpel technique of excisional hemorrhoidectomy. *Dis Colon Rectum* 2001; 44: 845-849.
- Armstrong DN, Ambroze WL, Schertzer ME, Orangio GR. Harmonic Scalpel vs. electrocautery hemorrhoidectomy: a prospective evaluation. *Dis Colon Rectum* 2001; 44: 558-564.
- Tan JY, Soew-choen F. Prospective, randomized trial comparing diathermy and harmonic scalpel hemorrhoidectomy. *Dis Colon Rectum* 2001; 44: 677-679.
- Filingeri V, Giudiceandrea F, Rosati R, Fiorito R, Casciani CU. Surgical treatment of hemorrhoid disease. A comparison between techniques. *Minerva Chir* 2001; 5: 41-46.
- Pfenninger JL. Modern treatments for internal haemorrhoids. *BMJ* 1997; 314: 1211-1212.
- Pfenninger JL, Surrel J. Nonsurgical treatment options for internal hemorrhoids. *Am Fam Physician* 1995; 52: 821-837.
- Yang R, Migikovsky B, Peicher J, Laine L. Randomized, prospective trial of direct current versus bipolar electro coagulation for bleeding internal hemorrhoids. *Gastrointest Endosc* 1993; 39: 766-769.
- Randall GW, Jensen DM, Machicado GA, Hirabayashi K, Jensen MI, You S, et al. Prospective randomized comparative study of bipolar versus direct current electro coagulation for treatment of bleeding internal hemorrhoids. *Gastrointest Endosc* 1994; 40: 403-410.
- Wright RA, Kranz KR, Kirby SL. A prospective cross over trial of direct current electrotherapy in symptomatic hemorrhoidal disease. *Gastrointest Endosc* 1991; 37: 6210-6213.
- Izadpanah A. Treatment of internal hemorrhoids utilizing direct current electricity. *Med J Islamic Republic Iran* 1998; 11: 311-314.
- Miller RD. Practice guidelines for pain management. In Anesthesia. 5th ed. Philadelphia (PA): Churchill Livingstone; 2000. p. 2831.
- Hussain JN. Haemorrhoids: Essentials of clinical management. *Aust Fam Physician* 2001; 30: 29-35.
- Van Tets WF, Kuijpers JH, Tran K, Mollen R, Van Goor H. Influence of parks' anal retractor on anal sphincter pressures. *Dis Colon Rectum* 1997; 40: 1042-1045.