

Analysis of small bowel tumors

Maad M. Abdul-Rahman, FRCS(Ed), Mustafa M. Al-Waali, CABS, Ahmed S. Al-Naaimi, MSc.

ABSTRACT

Objective: Small bowel tumors are remarkably rare. The colon is affected 40 times than the small bowel. Even though the small intestine accounts for 80% of the length and 90% of the mucosal surface of the gastrointestinal tract, only 3-6% of the gastrointestinal malignancies arise from the small bowel. The aim of the study is to enlighten the subject in our community including: therapeutic intervention, the histopathologic types, the risk factors and outcome.

Methods: Between January 1997 and January 2002, 40 patients with primary small bowel tumors were followed in Baghdad Hospital, Gastroenterology and Hepatology Hospital, Al-Mansour Hospital for Pediatrics at Medical City Teaching Centre and the Al-Zahraa Private Hospital, for presentations, preoperative investigations, operative procedures and outcome. Chi-square test or where appropriate Fishers exact test was used to assess for the statistical significance of the site of the tumor and outcome. The relative risk (RR) and odds ratio (OR) where possible, were used to measure the magnitude of developing a certain outcome (like death) in the presence of risk factor compared to its absence. *P* value less than the 0.05 level of significance is considered statistically significant. The 95% confidence interval was used to

express the expected range of incidence rate of certain outcomes in the target population.

Results: The most frequent age group affected is 46-60. The most frequent symptoms in decreasing order were abdominal pain (75%), vomiting (72.5%), and weight loss (52.5%). The most sensitive diagnostic procedure was barium study (84.6%). Lymph nodes were the most common site of metastases 15 (37.5%). The duration of follow up was from 2-60-months. The site: duodenum has the highest case fatality rate (62.5 %) with an RR=9.9 which was statistically significant ($p=0.006$) as compared to the jejunum (25%) that has an RR=3.9 ($p=0.16$ NS), then the ileum (6.3%).

Conclusion: Overall, the prognosis for patients with small intestinal tumors is poor. The duodenum as a site of the small bowel tumors was the only significant risk factor with regard to case fatality rate. Despite current advanced diagnostic modalities, the small intestine remains a difficult area to image with both radiographs and the endoscope.

Saudi Med J 2004; Vol. 25 (12): 1900-1905

Small bowel tumors are remarkably rare. The colon is affected 40 times than the small bowel.¹ Even though the small intestine accounts for 80% of the length and 90% of the mucosal surface of the gastrointestinal tract, only 3-6% of the gastrointestinal malignancies arise from the small bowel.^{2,3} The reasons for this difference are unknown. Several theories have been proposed as possible explanations: rapid transit time decreases the time for contact of carcinogens with the mucosa; the local immune system of the small bowel

mucosa; the alkaline pH of the succus entericus; the absence of bacteria that might convert certain ingested products into carcinogens; and the presence of mucosal enzymes that destroy certain carcinogens.¹ The surgeon is challenged in the diagnosis and treatment of these tumors, due to their infrequency, the different histological types and unspecific symptoms.⁴ The first report of a case of duodenal carcinoma was made by Hamburger.⁵ The first collective series of malignant small bowel neoplasm was published by Leichtenstein.⁶

From the Department of Surgery, Iraqi Commission of Medical Specializations, Baghdad, Iraq.

Received 25th February 2004. Accepted for publication in final form 15th June 2004.

Address correspondence and reprint request to: Prof. Maad M. Abdul-Rahman, Chairman Surgical Scientific Council, Iraqi Commission of Medical Specializations, PO Box 5116, Bab Al-Moadam, Baghdad, Iraq. Fax. +964 (1) 4140664. E-mail: maadmadhat@yahoo.com

Methods. Between January 1997 and January 2002, 40 patients with primary small bowel tumors were followed for presentations, preoperative investigations, operative procedures and outcome in Baghdad Hospital, Gastroenterology and Hepatology Hospital and Al-Mansour Hospital for Pediatrics at the Medical City Teaching Center and Al-Zahraa Private Hospital. The patients with peri-ampullary tumors or tumors arising primarily from the mesentery and those with peripheral lymphadenopathy or abnormal white blood cell count were excluded.

Statistical analysis. Data were translated into codes using a specially designed coding sheet and then converted to a computerized database. An expert statistical advice was sought for. Statistical analyses were carried out using statistical package for social sciences version 7.5 computer software in association with EPI version 6.2 (Epidemiological package). Chi-square test or where appropriate Fishers exact test (used in case of small-expected frequencies) was used to assess for the statistical significance of between 2 categorical variables (like the site of the tumor and outcome). The relative risk (RR) was used to measure the magnitude of developing a certain outcome (death) in the presence of risk factor compared to its absence. This kind of risk assessment is valid for a cohort design in which the risk factor status is known at the start of the study and the study subjects are followed for a certain period of time to record the development of the outcome of interest. In cases of a cross sectional design OR (odds ratio) is used to assess the magnitude of risk. *P* values less than the 0.05 level of significance is considered statistically significant. The 95% confidence interval was used to express the expected range of incidence rate of certain outcomes in the target population and thus gives an idea regarding the calculated estimates for the small samples.

Results. The most frequent age group affected by the small bowel tumors is 46-60 that represented 13 patients of the study sample (32.5%) followed by the patients less than 16-years of age that showed 9 patients (22.5%), then the age group of 16-30 that showed 7 patients (17.5%). For statistical analysis we divided our study sample into 2 groups: that less than 30 and those 30 and above. There were 23 males (57.5%) and 17 females (42.5%). The mean age (range) of the patients was (38.1 year) with standard deviation of 22.3. The male to female ratio was 1.4:1. The most frequent symptoms in decreasing order were abdominal pain (75%), vomiting for example. The duodenum was involved by 8 (20%) cases of the small bowel lesions: 3 (37.5%) were non-Hodgkin's lymphoma, 2 (25%) cases of adenocarcinoma, 2 (25%) cases of

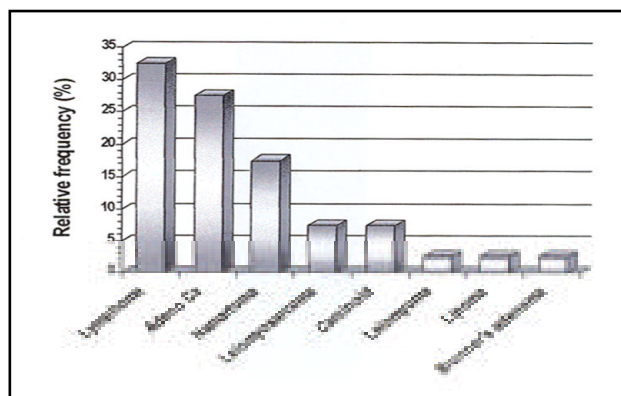


Figure 1 - Bar chart showing the relative frequency of different histopathological types.

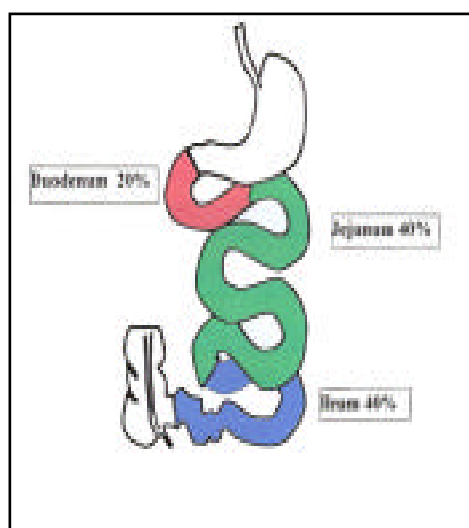


Figure 2 - The site of tumor.

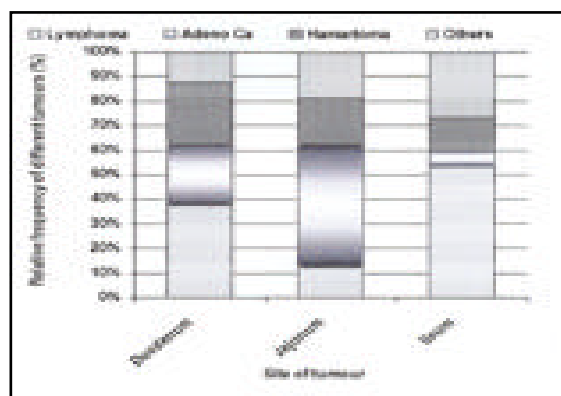


Figure 3 - Stacked bar chart showing the relative frequency of different histopathological types of tumor by site.

hamartoma (Peutz-Jegher's syndrome) and one (12.5%) case of Brunner's gland adenoma. The jejunum was involved by 16 (40%) cases of small bowel tumors: 8 (50%) were adenocarcinoma cases, 3 (18.8%) cases of hamartoma (Peutz-Jegher's syndrome), 2 (12.5%) cases of lymphoma, 2 (12.5%) cases of leiomyosarcoma and one (6.3%) case of lipoma. The ileum was involved by 16 (40%) cases of the small bowel lesions: 8 (50%) were non-Hodgkin's lymphoma, 3 (18.8%) cases of carcinoid tumor, 2 (12.5%) cases of hamartoma (Peutz-Jegher's syndrome), only one (6.3%) case of adenocarcinoma, leiomyosarcoma and leiomyoma (6.3%) each. The above findings were re-analyzed by using the odds ratio and we found that the ileum was more frequently (61.5%) involved with lymphoma compared to other tumors (29.6%). The risk of ileal involvement by lymphoma is 3.8 times more as compared to other tumors, ($p=0.05$). Also we found that duodenum and jejunum were more frequently (90.9%) involved with adenocarcinoma compared to other tumors. The risk of duodenal and jejunal involvement by adenocarcinoma is 10.7 times more as compared to other tumors ($p=0.01$), (Table 1). Esophagogastroduodenoscopy was conclusive, in diagnosing small bowel tumors, in 9 patients out of 17 patients who underwent the procedure (52.9%). Delineation of the luminal narrowing, pre-obstruction dilatation and the possibility of intussusception were possible by Barium study that was conclusive in 11 out of 13 patients (84.6%). Ultrasonography has been carried out on 23 patients and was conclusive in 13 of them (56.5%) as it describes the presence of soft tissue masses, their lobulated appearance, echogenic center, their relation to the small bowel loops and the presence of mesenteric lymph nodes. The presence of ascites and liver metastases were found by ultrasound examination. The single most accurate diagnostic procedure is that one provides histologic diagnosis. Fine needle aspiration cytology was diagnostic in 2 cases of lymphoma that presented with features of chronic illness and abdominal mass, the base on which chemotherapy

of lymphoma was started. As the majority of the small intestinal tumors presented as emergency cases, the exploration played an integral part of their diagnosis in spite of the available image procedures. The characteristic magnetic resonance imaging (MRI) scan image of the ileal carcinoid and its hepatic metastases were found in the only one case of carcinoid syndrome together with the high urinary level of the 5-hydroxy-indol acetic acid. One case of duodenal adenocarcinoma and its hepatic secondaries were found by MRI scan. We found that the elective surgical intervention was more frequent (53.8%) than the emergency one (46.2%). Segmental resection with restoration of the continuity by end to end anastomosis was performed in 24 (60%) patients: 15 patients with jejunal lesions (93.8%) and 9 patients with ileal lesions (56.3%). Right hemicolectomy with ileo-transverse anastomosis was performed in 3 (7.5%) cases of ileal lesion. Bypass procedure was carried out in 3 (7.5%): 2 patients with duodenal lesion (25 %) and one (6.3%) patient with jejunal lesion. Biopsy alone was performed in 3 (7.5%): 2 patients with duodenal lesion (25%) and one (6.3%) patient with ileal lesion. Endoscopic extirpation was performed in 3 (7.5%): one patient with duodenal lesion (12.5%) and 2 (12.5 %) patients with ileal lesion. Whipple's operation was performed in only one (2.5 %) case of duodenal lymphoma (12.5%). Ileostomy was performed in only one (2.5%) malignant case of perforated lymphoma of the ileum (12.5 %), Table 2. Lymph nodes were the most common site of metastases 15 (37.5%), then adjacent structure 9 (22.5%), liver 5 (12.5%), and peritoneal seedlings 5 (12.5%). These cases were followed on the bases of short and long outcome. The period of follow up rang from 1-60-months (the period of the study). Three (7.5%) patients died during their hospital stay. One duodenal lymphoma patient died next day to his diagnosis as of advanced obstructing tumor and another patient with ileal hamartomatous polyp who died also next day to her colonoscopic examination in the coronary care unit as of myocardial infarction. Majority had smooth

Table 1 - Type of tumor and the site involved.

Type of tumor	Site involved		Total n (%)	Odds ratio	p value
	Duodenum and jejunum n (%)	Ileum n (%)			
Lymphoma					
Absent	19 (70.4)	8 (29.6)	27 (100)	3.8	0.05
Present	5 (38.5)	8 (61.5)	13 (100)		
Adenocarcinoma					
Absent	14 (48.3)	15 (51.7)	29 (100)	10.7	0.01
Present	10 (90)	1 (9.1)	11 (100)		

Table 2 - Histopathological diagnosis and type of surgical intervention.

Variables	Site of tumor		
	Duodenum	Jejunum	Ileum
Histopathological diagnosis			
Lymphoma	3 (37.5)	2 (12.5)	8 (50)
Adenocarcinoma	2 (25)	8 (50)	1 (6.3)
Leiomyosarcoma		2 (12.5)	1 (6.3)
Carcinoid			3 (18.8)
Hamartoma	2 (25)	3 (18.8)	2 (12.5)
Leiomyoma			1 (6.3)
Lipoma		1 (6.3)	
Brunner's gland adenoma	1 (12.5)		
Type of surgical intervention			
No surgery	2 (25)		
Resection + end to end anastomosis		15 (93.8)	9 (56.3)
Right hemicolectomy			3 (18.8)
Whipple's resection	1 (12.5)		
Bypass	2 (25)	1 (6.3)	
Ileostomy			1 (6.3)
Biopsy	2 (25)		1 (6.3)
Endoscopic extirpation	1 (12.5)		2 (12.5)
Total	8 (100)	16 (100)	16 (100)

Table 3 - Overall case fatality rate by selected independent variables.

Variables	Negative n (%)	Positive n (%)	Total n (%)	Relative risk	p value
Site of tumor					
Duodenum	3 (37.5)	5 (62.5)	8 (100)	9.9	0.006
Jejunum	12 (75)	4 (25)	16 (100)	3.9	0.16 *
Ileum	15 (93.8)	1 (6.3)	16 (100)		
<i>p value (trend) 0.005</i>					
Age in years					
<30	15 (93.8)	1 (6.3)	16 (100)		
≥30	15 (62.5)	9 (37.5)	24 (100)	5.9	0.02
Gender					
Male	19 (82.6)	4 (17.4)	23 (100)		
Female	11 (64.7)	6 (35.3)	17 (100)	2.1	0.17*
Presence of metastasis					
Absent	17 (81)	4 (19)	21 (100)		
Present	13 (68.4)	6 (31.6)	19 (100)	1.6	0.29*
Histopathologic type					
Lymphoma	9 (68.2)	4 (30.8)	13 (100)	2.5	0.22*
Adenocarcinoma	7 (63.6)	4 (36.4)	11 (100)	2.9	0.16*
Other tumors	14 (87.5)	2 (12.5)	16 (100)		
*not significant					

post-operative period. One (2.5%) patient had duodenal fistula that was discharging through the abdominal drain with obstructive jaundice increasing her morbidity. Thirty-six patients were discharged home and followed for variable periods ranging from 1-60 months thereafter. Eleven patients (39.3%) had a disease free status during the period of the study as proved by clinical examination, ultrasonography and chest radiography every 3 months after they had finished their chemotherapy in the oncology department. Seven (25%) patients died, 6 (21.4%) patients were receiving treatment, and 2 (7.1%) presented with recurrence of the original pathology and the last 2 (7.1%) patients underwent re-exploration. The remaining 8 (22.2%) were lost to follow up. Overall case fatality rate by selected independent variables **Table 3**. With regard to death as an outcome, we found that the duodenum has the highest case fatality rate (62.5%) with an RR=9.9 which was statistically significant ($p=0.006$) as compared to the jejunum (25%) that has an RR=3.9 ($p=0.16$ NS), then the ileum (6.3%). The age as a risk factor, the patients of 30 years and above have a case fatality rate of (37.5 %) with an RR=5.9 ($p=0.02$ NS). Females have a higher case fatality rate (35.3%) than do males (17.4%) with an RR=2.1 ($P =0.17$ NS). Presence of metastases has a higher case fatality rate (31.6 %) than without (19%) and an RR=1.6 ($p=0.29$ NS). The histopathology as a risk factor, adenocarcinoma has the highest case fatality rate (36.4 %) and an RR=2.9 ($p=0.16$ NS) as compared to lymphoma (30.8%) with an RR=2.5 ($p=0.22$ NS) and other tumors (12.5%). The duodenum shows a 62.5% case fatality rate, the jejunum shows 25% and the ileum shows 6.3% which means that the more proximal the lesion, the more mortality rate.

Discussion. Small intestinal tumors are rare tumors. They represent less than 2% of all malignant tumors of the gastrointestinal tract.⁷ Diagnosis is often delayed as of the nonspecific nature of the symptoms they produce. Thus, they are often in advanced stages before they are detected. It is reported that 75% of symptomatic small bowel tumors are malignant.⁸ Despite current advanced diagnostic modalities, the small intestine remains a difficult area to image with both radiographs and the endoscope.⁹ The most common symptoms of small bowel tumors include abdominal pain, nausea and vomiting, bleeding, weight loss, and intermittent obstruction. These symptoms have been reported to occur in 8-80% of patients.¹⁰⁻¹² Abdominal pain has been reported to be the most common complaint in 65-83% of patients, with nausea and vomiting found in 35-54%.^{11,12} These nonspecific complaints led to a delay in diagnosis ranging from 1-26 months.^{10,12-14}

In our study, the most common presenting symptom, in order of frequency were abdominal pain (75%), vomiting (72.5%) and weight loss (52.5%). In the study of James and Mark,⁹ males had a greater incidence of small bowel malignancy than females, by a ratio of 1.8-1.0.¹⁵ This is similar to the findings reported by Kusumoto et al.¹¹ Also in our study, males outnumber females by a ratio of 1.4: 1. The highest incidence of the tumors in the small intestine was noted in patients between 46 and 60, a little younger than in the study of Brücher et al and other authors.^{4,16,18-23} James and Mark⁹ found that the most common histologic types of small intestinal malignant tumors are adenocarcinoma (47%), carcinoid (28%), leiomyosarcoma (13%), and lymphoma (12%).⁹ We found that the most common histologic types are lymphoma (32.5%), adenocarcinoma (27.5%), hamartoma (17.5%), leiomyosarcoma (7.5%) and carcinoid (7.5%). While in the Brücher et al⁴ series, the main histologic entities in malignant SBTs were; adenocarcinoma (38.3 %), neuroendocrine tumors (31.9 %), NHLs (12.8 %) and leiomyosarcomas (10.6 %), figures that are comparable to those of Martin¹⁶ and Broll et al.²⁴ The anatomical distribution of the small bowel tumors of our series shows a predominance of the ileal (40%) and jejunal (40%) lesions and then the duodenal (20%) lesions. This is comparable to that of Brücher et al,⁸ duodenum (32%), jejunum (34%) and ileum (34%) that was statistically equal and comparable to the data of Coit²⁵ and Zollinger.²⁶ Other authors^{8,16-18,20,21,24,27,28} showed an ileal predominance. Only Klem et al²⁹ described predominance of malignant small bowel lesion in the jejunum.

Our series shows that lymphoma cases are predominant in the ileum (61.5 %), while in Brücher et al series⁴ NHL cases are predominant in the jejunum (66.6%). The adenocarcinoma cases are predominant in the jejunum (50%), **Table 2**, in contrast to Brücher et al⁴ and Adler et al³⁰ whose adenocarcinoma cases were predominant in the duodenum (61.1%). None of them described an ileal involvement in comparison to our series and Coit²⁵ who describe approximately (7.7%) and (22%) ileal adenocarcinoma. James and Mark⁹ described (24%) ileal adenocarcinoma. According to the data of Peck et al,³¹ 93.3% of neuroendocrine tumors were localized in the ileum, while Ouriel and Adams²² report neuroendocrine tumors as ileal lesions in 57-84.7%.²² In our series, carcinoid tumors were primarily ileal lesions. Brücher et al described a rate of 83.1%/ 16.9%.

We found that the site is a significant risk factor as the case fatality rate increases with the more proximal lesions: duodenum (62.5 %) with an RR=9.9 ($p=0.006$), jejunum (25%) with an RR=3.9 ($p=0.16$ NS) and ileum (6.3%). James et al⁹ showed that survival of patients with adenocarcinoma was

not dependent on location within the small bowel. We found that 19 (47.5%) patients of our study sample had metastases. The lymph nodes were the most common site of metastases (37.5%) followed by adjacent structure (22.5%), liver and peritoneal seedlings (12.5%) each. While Brücher et al⁴ found (40.4%) of his study sample has distant metastases of which the liver was the commonest site. This difference can be attributed to the relative difference of the lymphoma, adenocarcinoma and the carcinoid tumor between our series and that of Brücher et al.⁴ The presence of metastases was found to be a statistically significant prognostic factor by Brücher et al.⁴ We found that the presence of metastases has a higher case fatality rate (31.6 %), RR=1.6 though this was not statistically significant ($p=0.29$), than the absence of metastases (19%).

Overall, the prognosis for patients with small intestinal tumors is poor. This is mainly due to the nonspecific nature of the symptoms, which contributes to a delay in diagnosis. This allows the tumor to grow and reach an advanced stage of disease before detection. A high degree of suspicion on the part of the physician is probably the only means of accelerating the diagnostic evaluation of these patients. The duodenum as a site of the small bowel tumors was the only significant risk factor with regard to case fatality rate. The other risk factors: age of 30-years and more, female gender, presence of metastases and the histopathologic type were all not significant though they increased the case fatality rate. Despite current advanced diagnostic modalities, the small intestine remains a difficult area to image with both radiographs and the endoscope.

References

1. Mark EB, Courtney M, Townsend J, James CT. Neoplasms of the small intestine. Chap. 25. Principles of Surgery. 7th ed. New York (NY): Mc Graw-Hill; 1999. p. 1238-1246.
2. Agustin AB, Miguel EM, Bernard MJ. Tumors of the Small Intestine. Chap 38. Maingot's Abdominal Operations. 10th ed. Englewood Cliffs (NJ): Prentice Hall International; 1997. p. 1173-1184.
3. Herbsman H, Wetstein L, Rosen Y et al. Tumors of the small intestine. In: Ravitch MM, editors. Current Problems in Surgery. Vol. 17. Chicago (IL): Yearbook Medical; 1980.
4. Brücher B, Roder JD, Fink U, Stein HJ, Busch R, Siewert JR. Prognostic Factors in Resected Primary Small Bowel Tumors. *Dig Surg* 1998; 15: 42-51.
5. Hamburger G. De ruptura intestine duodeni. *Jena Ritterianis* 1746.
6. Leichtenstern O. Handbuch der speciellen Pathologie und Therapie. *Leipzig Vogel* 1876. p. 523-524.
7. Ashley SW, Wells SA. Tumors of the small intestine. *Semin Surg Oncol* 1988; 15: 116-128.
8. Darling RC, Welch CE. Tumors of the small intestine. *N Engl J Med* 1959; 260: 297-408.
9. James HN, Mark SP. Malignant Tumors of the Small Intestine: A Review of 144 Cases. The American Surgeon. From the Surgical Oncology Service, Eisenhower Army Medical Center, Fort Gordon, Georgia, 2000. (As taken from the Internet).
10. Ciresi DL, Scholten DJ. The continuing clinical dilemma of primary tumors of the small intestine. *Am Surg* 1995; 61: 698-703.
11. Kusumoto H, Takahashi I, Yoshida M, Maehara Y, Watanabe A, Oshiro T et al. Primary malignant tumors of the small intestine: Analysis of 40 Japanese patients. *J Surg Oncol* 1992; 50: 139-143.
12. Garcia-Marcilla JA, Sanchez-Bueno F, Aguilar J, Parrilla-Paricio P. Primary small bowel malignant tumors. *Eur J Surg Oncol* 1994; 20: 630-634.
13. Baille CT, Williams A. Small bowel tumors: A diagnostic challenge. *J R Coll Surg Edinb* 1994; 39: 8-12.
14. Basson MD. Small bowel tumors. *Curr Opin Gen Surg* 1993; 219-224.
15. Frost DB, Mercado PD, Tyrell JS. Small bowel cancer: A 30- year review. *Ann Surg Oncol* 1994; 1: 290-295.
16. Martin GM. Malignant tumors of the small intestine. *Surg Clin North Am* 1986; 6: 779-785.
17. Barclay THC, Schapira DV. Malignant tumors of the small intestine. *Cancer* 1983; 51: 878-881.
18. Croom RD, Newsome JF. Tumors of the small intestine. *Am Surg* 1975; 41: 160-167.
19. Delcore R, Thomas JH, Forster J, Hermreck AS. Improving resectability and survival in patients with primary duodenal carcinoma. *Am J Surg* 1993; 166: 626-631.
20. Miles RM, Crawford D, Duras S. The small bowel tumor problem: An assessment based on 20 years experience with 116 cases. *Ann Surg* 1978; 189: 732-740.
21. Mittal VK, Bodzin JH. Primary malignant tumors of the small bowel. *Am J Surg* 1980; 140: 396-399.
22. Ouriel K, Adams J. Adenocarcinoma of the small intestine. *Am J Surg* 1984; 147: 66-71.
23. Cunningham JD, Aleali R, Aleali M, Brower S, Aufses AHI: malignant small bowel neoplasms: Histopathological determinants of recurrence and survival. *Ann Surg* 1997; 225: 300-306.
24. Broll R, Bruch HP, Daniel D, Schiedeck TH. Maligne Dünndarmtumore: Diagnostische Probleme und differenzierte chirurgische Therapie. *Chirurgie* 1994; 65: 451-456.
25. Coit DG. Cancer of the small bowel. Chap. 29. In: Cancer Principles and Practice of Oncology, ed 4. Philadelphia (PA): Lippincott Williams & Wilkins; 1993. p. 915-926.
26. Zollinger RM, Sternfeld WC, Schreiber H. Primary neoplasms of the small intestine. *Am J Surg* 1986; 151: 654- 658.
27. Cicarelli O, Welch JP, Kent GG. Primary malignant tumors of the small bowel: The Hartford hospital experience, 1969 - 1983. *Am J Surg* 1987; 153: 350-354.
28. Buchholz J, Strosche H, Krawzak HK, Kahl N. Primäre Dünndarmmalignome-Symptomatik, Diagnostik und Therapie. *Leber Magen Darm* 1988; 4: 197-203.
29. Klem C, Padberg W, Zimmermann T, Hürgen M, Buhr J. Maligne Tumoren des Dünndarms. *Zentralbibl Chir* 1994; 119: 639-644.
30. Adler S, Lyon D, Sullivan P. Adenocarcinoma of the small bowel: Clinical features, similarity to regional enteritis, and analysis of 338 documented cases. *Am J Gastroenterol* 1982; 77: 326-330.
31. Peck JJ, Shields AB, Boyden AM, Dowrkin LA, Nadal JW. Carcinoid tumors of the ileum. *Am J Surg* 1983; 146: 124.