Saphenofemoral ligation as a safe and effective alternative for the treatment of chronic venous leg ulcer

Emad A. El-Hafez, *MD,* ***Mohamed I. Seleem,*** *FRCS, FACS.*

ABSTRACT

Objectives: To evaluate the effectiveness and safety of isolated saphenofemoral junction ligation for the treatment of chronic venous leg ulcer in comparison to traditional stripping procedure.

Methods: Thirty six patients (28 men and 8 women) with mean age of 42.3 ± 8.7, presented with a venous leg ulcer. After taking a full history, they underwent examination for presence of edema, cellulitis or local ulcer infection. The site and size of ulceration were recorded and ankle-brachial pressure index (ABPI) was measured. Venous color Doppler ultrasonography was performed and venous valvular incompetence was assessed using Valsalva test and calf compression. Patients were divided into 2 groups. Group I, (n=10) assigned for long saphenous stripping, while group II, (n=26) assigned for saphenofemoral ligation and divided combined with ligation of major tributaries under local infiltration anesthesia. Mean operative time, postoperative complications and hospital stay were recorded. The study was carried out in Benha University Hospital, Egypt and Armed Forces Hospital, Khamis Mushayt, Southern Region, Kingdom of Saudi Arabia, between January 2000 and December 2001.

Results: The mean operative time and the hospital stay were significantly ($p<0.05$) reduced in group II compared to group I. The postoperative complications were significantly ($x^2=7.5$, $p<0.05$) reduced in group II. Ulcer healing started after 3 months in group II and 6 months in group I, but, by 12 months, group II had a significant ($x^2=6.7$, $p<0.05$) number of healed ulcers (n=22, 84.6%), compared to group I (n=7, 70%).

Conclusion: The isolated ligation of saphenofemoral junction is a minimally invasive, safe and effective modality for treatment of chronic leg ulcer, and being easily performed under local anesthesia and considered to be a satisfactory procedure for treatment of leg ulcer in patients who are unfit for general anesthesia.

Saudi Med J 2004; Vol. 25 (2): 172-176

Chronic venous disease in the lower limbs is common, with a prevalence of approximately 50-55% of women and 40-50% of men.[1] Complicated cases of chronic venous insufficiency are also frequent. Approximately 2% of the population will some time in their lives suffer from leg ulceration, half of these are venous leg ulcers.[2] Leg ulcers are caused by many factors, approximately 70% of ulcers above the foot are of mainly venous origin,[3] and the arterial component can be safely ignored in legs with an ankle-brachial pressure index (ABPI) of <0.8.[4] Lower extremity venous ulceration resulting from long-standing venous stasis has been attributed to venous flow obstruction and reflux in the deep venous system and has been regarded as an inevitable consequence of postphlebitic syndrome.[5] However, the presence

From the Department of General Surgery (El-Hafez), Benha Faculty of Medicine, Zagazig University, *Egypt* and the Department of General Surgery (Seleem) Armed Forces Hospital, Southern Region, Khamis Mushayt, *Kingdom of Saudi Arabia.*

Received 20th September 2003. Accepted for publication in final form 20th October 2003.

Address correspondence and reprint request to: Dr. Mohamed I. Seleem, Consultant General and Vascular Surgeon, Armed Forces Hospital, Southern Region, PO Box 101, Khamis Mushayt, *Kingdom of Saudi Arabia*. Tel/Fax. +966 (7) 2510587. E-mail. saleem1961@hotmail.com

of reflux in the superficial venous system, at the saphenofemoral junction, and in particular the great saphenous vein, has been recognized as an important cause of chronic leg insufficiency with its characteristic lipodermatosclerosis and intractable ankle ulcerations.[6] Furthermore, reflux from the short saphenous system has been demonstrated to affect the lateral side of the ankle in the same way as greater saphenous vein insufficiency causes chronic venous insufficiency on the medial aspect.[7] Color duplex ultrasonography is a fast and non-invasive assessment, gives anatomical and functional information, and has largely replaced venography in the assessment of lower-limb venous disorders.[8] Primary use of duplex to identify patients with chronic venous ulceration whom surgery might be of benefit is reported.[9] We carried out this study to evaluate the effectiveness and safety of isolated saphenofemoral junction ligation for the treatment of chronic venous leg ulcer in comparison to traditional stripping procedure.

Methods. In Benha University Hospital, Egypt and Armed Forces Hospital, Khamis Mushayt, Southern Region, Kingdom of Saudi Arabia, 36 patients with leg ulcer, resistant to local treatment for more than 6 months, were seen in the surgical outpatient clinic between January 2000 and December 2001, seek surgical treatment. A chronic ulcer was defined as being present for at least one month, ranged from 2-7 cm in diameter and was characteristically punched out and deep. All patients enrolled in the study underwent the following: 1) Full history taking, including history of ulcer development, duration of ulceration, types of treatment received, history of previous deep vein thrombosis, varicose surgery or hip surgery. 2) Both lower limbs were examined for venous diseases, the presence of edema, cellulitis or local ulcer infection. The site and size of ulceration were recorded. The ulcer site was defined as follows: zone I - the foot; zone II - the gaiter area extending from 2.5 cm below the malleoli to the point where the calf muscles become prominent posteriorly and zone III - extending above this point to the knee.[10] 3) The ABPI was measured using a continuous wave Doppler ultrasonographic probe and mercury sphygmomanometer. It was considered to be abnormal if below 0.9. Any patient with ABPI<0.9 was excluded from the study. 4) Venous color Doppler ultrasonographic examination was performed using Acuson 128 (Acuson Corp, Mountain view, CA, USA) color flow duplex with a 5 MHz linear probe. All major veins of the lower limbs, from the groin to the ankle, were examined. Venous valvular incompetence was assessed using the Valsalva test and calf compression (manual or with a pneumatic cuff). The increased abdominal pressure during the Valsalva maneuver provokes reversed blood flow if the venous valves are incompetent. Calf compression and decompression simulates the calf muscle pump. Valvular incompetence was shown by reversed flow during decompression and was graded, based on blood flow velocity (frequency shift) and duration estimated from the color scale into high grading, high velocity and turbulence, as indicated by a pale color as well as long duration and low grading, low velocity, as indicated by a darker color and short reflux duration. A local jet flow at the valve level was not considered significant. The long saphenous and the femoral veins were examined with the patient in the supine position, and the popliteal and short saphenous veins with the patient in the prone position on a bed tilted 40 degree feet-down. The posterior tibial, peroneal veins and calf perforators were tested with the patient sitting on a bed with the foot in the examiner's lap. Manual calf or foot compression was used for testing reflux in the lower leg. Perforator reflux was defined as an outward flow from the deep to superficial veins during compression/ decompression. Both cross-sectional and longitudinal imaging was used. Based on color Doppler findings venous insufficiency in the legs was classified as mainly superficial (long or short saphenous veins, or both), mixed superficial and deep or mainly deep (superficial or deep femoral or popliteal veins).[11] Patients with mainly superficial venous insufficiency were enrolled in the study.

Preoperative preparation. All patients were prepared for surgery with complete bed rest and 15 cm foot elevation in the trendelenburg position until edema and infection subsided. All ulcers were swabbed for bacteriological examination and culture and sensitivity examination. Intravenous antibiotics were given to 7 patients (19.4%) with severe local infection and cellulites according to the culture results. The local wound care regimen included hourly irrigation with normal saline during daytime and night dressings with debrisan. The patients were given the option between the 2 surgical techniques. This study was divided between these 2 groups: Group I (control group) comprised 10 patients assigned to undergo long saphenous stripping under general anesthesia using Trendelenburg maneuver combined with ligation of major tributaries and surgical debridement of the ulcer if needed. Group II (study group) comprised 26 patients assigned to undergo long saphenofemoral ligation and divided combined with ligation of major tributaries and surgical debridement of the ulcer if needed. Surgery was assigned to be carried out under local infiltration anesthesia using plain 0.25% bupivacaine.

Surgery technique. Before surgery, the saphenofemoral junction (SFJ) was carefully identified by color flow duplex imaging and its location was marked with indelible ink with the

patient standing. Through a 4-5 cm transverse skin incision at the previously marked spot, the SFJ was identified under the fascia, and the saphenous vein was ligated, femoral vein, flushed with the non-absorbable suture and then was divided. All venous tributaries in the area were identified and ligated. Postoperative wound care included daily cleansing of the ulcer with a normal saline solution, dressing with a hydrocolloid dressing, and a 3-layer bandage. Mean operative time, postoperative complications and hospital stay were recorded. Patients received a compression stocking, and were examined monthly for 3 months, then every 3 months until ulcer healing or for 12 months. The overall results were analyzed, as well as in subgroups.

Results. Among the 36 patients (28 men and 8 women) with a mean age of 42.3±8.7 years (range 29-61), only 4 (15.4%) patients in group II refused local anesthesia for exaggerated apprehension and requested the administration of general anesthesia

Patients had lower limb ulcers resisting treatment for a mean period of 11±2.2 (range 7-15) months. There were 8 patients with more than one ulcer, and one patient had a foot ulcer, 2 patients had an ulcer located above the calf muscles prominence, while the other 33 ulcers were located in zone II. Ulcer size varied between 2 and 9 cm with a mean diameter of 4.8±1.7 cm and 7 patients had secondary infection requiring systemic antibiotics aside from the local treatment. All patients received previous local treatment, 20 had used compression for variable periods and 30 patients received previous oral medications. Sclerotherapy was tried for varicosities in 7 patients, while 3 patients underwent previous skin grafting (**Table 1**). There was a non-significant discrepancy between patients data in both groups. Operative time was significantly ($p<0.05$) reduced in group II, (mean 54.6±13, range 35-75 minutes) compared to group I, (mean 81.5±20.3, range 60-120 min). The hospital stay was significantly ($p<0.001$) reduced in group II, (mean 2.5±1.1, range 1-5 days) compared to group I, (mean 7±1.6; range 5-10 days), (**Figure 1**). The postoperative complications were significantly reduced in group II compared to group I, ($x^2=7.5$, $p<0.05$) (**Table 2**).

Both modalities of management succeeded to induce ulcer healing that started to be evident after 6 months of follow-up. However, by 12 months of follow-up, group II had a significant, ($x^2=6.7$, $p<0.05$) number of healed ulcers (n=22, 84.6%), compared to group I, (n=7, 70%), (**Table 3, Figure 2**). Moreover, there was a progressive decrease of the ulcer size throughout the follow-up period. In group I the mean ulcer size at 6, 9 and 12 postoperative months was significantly decreased compared to initial ulcer size and to ulcer size detected at one and 3 postoperative months, with a non-significant difference in both groups. On the other hand, in group II, ulcers showed progressive decrease starting 3 month after surgery until the end of the follow-up period, with a significant decrease compared both to the initial ulcer size and ulcer size was measured after one month, and at 6, 9, and 12 month as compared to size measured at 3-months, and at 12 months compared to size determined at 6 months, (**Table 3, Figure 3**). Four ulcers (15.4%) remained unhealed until the end of follow-up period in group II, whereas there were 3 ulcers (30%) in group I, (**Table 3**).

Discussion. Venous ulceration is a debilitating problem associated with significant financial cost due to loss of work hours and cost of medical care

Table 1 - Patients data.

Characteristics	Group I (%)	Group II n (%)	Total (%)
Duration (months)	10.7 ± 2.8 (7-15)	11.1 ± 2 (8-15)	**11 ± 2.2 (8-15)**
N of ulcers			
Single	7	28 (73.7)	**21**
Two	2	5 (17.9)	**3**
Multiple	1	3 (8.4)	**2**
Site of grading			
I	0	1 (2.8)	**1**
II	10	33 (91.6)	**13**
III	0	2 (5.6)	**2**
Total size (cm)	**4.6 ± 2.1 (2-9)**	**4.8 ± 1.6 (2-8)**	**4.8 ± 1.7 (2-9)**
Secondary infection	3	4	**7 (19-4)**
Previous treatment			
Local care	10	36 (100)	**26**
Compression	7	20 (55.6)	**13**
Sclerotherapy	3	7 (19.4)	**4**
Oral medication	7	30 (84)	**23**
Skin grafting	2	3 (8.4)	**1**

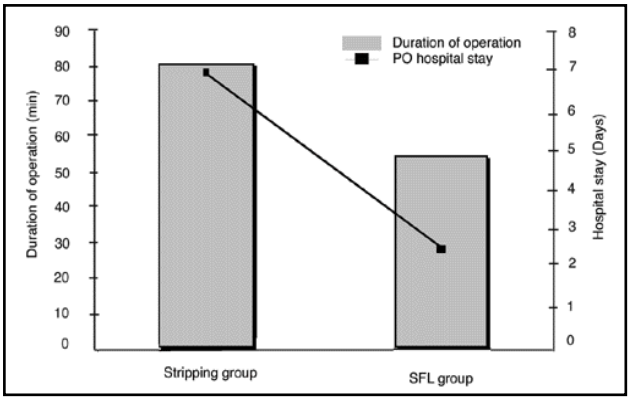

Figure 1 - Duration of striping and saphenofemoral ligation (SFL) operations and postoperative hospital stay in both groups. PO - postoperative

Table 2 - Postoperative complications.

Type of complications	Group I (N=10) n (%)	Group II (N=26) n (%)
Severe pain	7 (70)	11 (42.3)
Stripping hematoma	8 (80)	0 (0)
Local hematoma	8 (80)	6 (23.1)
Leg swelling	4 (40)	2 (7.7)
Wound infection	3 (30)	4 (15.4)
Delayed wound healing	4 (40)	5 (19.2)
Need for leg elevation	9 (90)	4 (15.4)
Initial walking disturbances	7 (70)	5 (19.2)

for the patients. Chronic venous leg ulceration affects 1-2% of the population, often with a protracted course of delayed healing and multiple recurrences.[12] Venous hypertension resulting from reflux and/or obstruction of the venous system is the underlying pathophysiological mechanism.[13] Operative time and hospital stay were significantly ($p<0.05$) reduced in group II compared to group I. The reduction of operative time was attributed to the simplicity of the surgical technique and to the abandoned need for stripping with concomitant need for a second incision and the time consumed during stripping itself. Shorter hospital stay in group II can be attributed to reduced postoperative complications as compared to group I. The diminished requirement for analgesia, the decreased incidence of leg swelling and the early ambulation can be attributed to the use of local anesthesia and the minimal dissection needed. Bass et al[14] reported that ligation of saphenopopliteal junction proved to be effective in controlling stasis manifestations and promoting healing of the ulcers through the application of a safe, minimally invasive operative procedure of little morbidity and good long-term results. While, Barwell et al[12] reported minimal postoperative complications after surgical correction of isolated venous reflux. In the present series, the overall healing rate was significantly increased in group II compared to group I, with a significant increase in number of patients with healed ulcer 12 months after surgery, 22 patients (84.6%) versus 7 patients, (70%) in the 2 groups. The obtained results signified that surgical correction of refluxing saphenous system rather than any coincidental incompetent perforators has often greater hemodynamic effect on the affected limb. In support of this, it has been reported that surgical correction of isolated superficial venous reflux has been

Table 3 - Follow-up data of unhealed ulcers.

Duration	Group I n (%)	Group I Size Mean ± SD	Group II n (%)	Group II Size Mean ± SD
Initial	10 (100)	4.6 ± 2.1 (2 - 9)	26 (100)	4.8 ± 1.7 (2 - 8)
1 month	10 (100)	4.6 ± 2.1 (2 - 9)	26 (100)	4.6 ± 1.8 (2 - 8)
3 months	8 (80)	2.6 ± 2.1 (0 - 7)	24 (92.3)	2.7 ± 1.6 (0 - 5)*†
6 months	7 (70)	1.8 ± 1.9 (0 - 6)*†	15 (57.7)	1.3 ± 1.4 (0 - 4)*†‡
9 months	5 (50)	1.4 ± 2 (0 - 6)*†	8 (30.8)	0.7 ± 1.2 (0 - 3)*†‡
12 months	3 (30)	1 ± 1.6 (0 - 4)*†	4 (15.4)	0.4 ± 1 (0 - 3)*†‡§

*significant versus the initial size, †significant versus size measured after one month, ‡significant versus size measured after 3 months, §significant versus size measured after 6 months

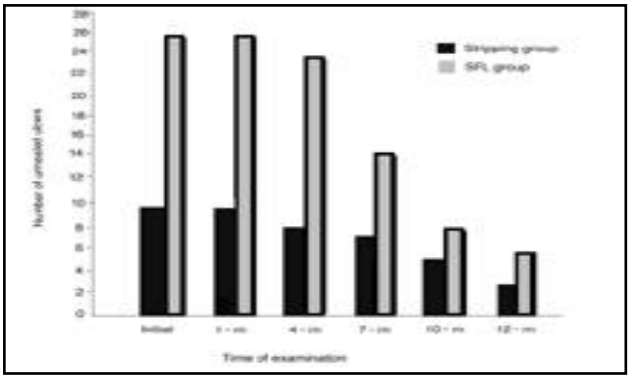

Figure 2 - Mean number of unhealed ulcers in both groups throughout the study period. SFL - saphenofemoral ligation

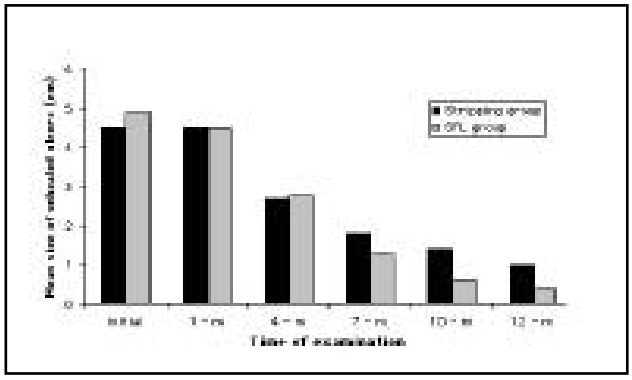

Figure 3 - Mean size of unhealed ulcers in both groups. SFL - saphenofemoral ligation

associated with reduced ulcer recurrence rates.[15-18] Moreover, there was significant decrease of the size of unhealed ulcers in both groups compared to the initial size determined prior to surgery. However, the decrease in size started to be significantly evident earlier in group II (after postoperative 3 month) compared to group I, (after 6 postoperative months). This illustrates the better resumption of hemodynamic stability and proper cutaneous circulation after saphenofemoral ligation procedure. The results in this series coincided with reported results, that ligation of saphenofemoral or saphenopopliteal perforators alone has been claimed as an effective treatment for non-healing venous ulcers.[19-21] Nelzén[21] reported healing of all leg ulcers (16 patients) after only subfacial endoscopic saphenofemoral perforators ligation.

We can conclude that isolated ligation of saphenofemoral junction is a minimally invasive, safe and effective modality for the treatment of chronic leg ulcer with results superseding the traditional stripping procedure, and being easily performed under local infiltration anesthesia. It is a satisfactory procedure for the treatment of leg ulcer in patients unfit for general anesthesia.

References

1. Callam MJ. Epidemiology of varicose veins. ***Br J Surg*** 1994; 81: 167-173.
2. Nelzén O, Bergqvist D, Lindhagen A. The prevalence of chronic lower-limb ulceration has been underestimated: results of a validated population questionnaire. ***Br J Surg*** 1996; 83: 255-258.
3. Nelzén O, Bergqvist D, Lindhagen A. Leg ulcer etiology- a cross sectional population study. ***J Vasc Surg*** 1991; 14: 557-564.
4. Ghauri AS, Nyamekye I, Grabs AJ, Farndon JR, Poskitt KR. The diagnosis and management of mixed arterial/venous leg ulcers in community-based clinics. ***Eur J Vasc Endovasc Surg*** 1998; 16: 350-355.
5. Scott TE, LaMorte WW, Gorin DR, Menzoian JO. Risk factors for chronic venous insufficiency: a dual case-control study. ***J Vasc Surg*** 1995; 22: 226-228.
6. Labropoulos N, Leon M, Geroulakos G. Venous hemodynamic abnormalities in patients with leg ulceration. ***Am J Surg*** 1995; 169: 572-574.
7. Magnusson MB, Nelzén O, Risberg B, Sivertsson R. A color Doppler ultrasound study of venous reflux in patients with chronic leg ulcers. ***Eur J Vasc Endovasc Surg*** 2001; 21: 353-360.
8. DePalma RG, Hart MT, Zanin I, Massarin EH. Physical examination, Doppler ultrasound and color flow duplex scanning: guides to therapy for primary varicose veins. ***Phlebology Journal*** 1993; 8: 7-11.
9. Grabs AJ, Wakely MC, Nyamekye I, Ghauri ASK, Poskitt KR. Color duplex ultrasonography in the rational management of chronic venous ulcers. ***Br J Surg*** 1996; 83: 1380-1382.
10. Callam MJ, Harper DR, Dale JJ, Ruckley CV. Chronic ulcer of the leg: clinical history. ***BMJ*** 1989; 294: 1389-1391.
11. Magnusson MB, Kälebo P, Lukes P, Sivertsson R, Risberg B. Color Doppler ultrasound in diagnosing venous insufficiency. A comparison to descending phlebography. ***Eur J Vasc Endovasc Surg*** 1995; 9: 437-443.
12. Barwell JR, Taylor M, Deacon J, Ghauri ASK, Wakely C, Phillips LK et al. Surgical correction of isolated venous reflux reduces long-term recurrence rate in chronic venous leg ulcers. ***Eur J Vasc Endovasc Surg*** 2000; 20: 303-308.
13. Tassiopoulos AK, Golts E, Oh DS, Labropoulos N. Current concepts in chronic venous ulceration: Review article. ***Eur J Vasc Endovasc Surg*** 2000; 20: 227-232.
14. Bass A, Chayen D, Weinmann EE, Ziss M. Lateral saphenous ulcer and short saphenous vein insufficiency. ***J Vasc Surg*** 1997; 25: 654-657.
15. Bellc M, Scriven M, Hartshornf T. Superficial venous surgery in the treatment of venous ulceration. ***Br J Surg*** 1999; 86: 755-759.
16. Darke SG, Penfold C. Venous ulceration and saphenous ligation. ***Eur J Vasc Surg*** 1992; 6: 4-9.
17. Bradbuy AW, Stonebridge PA, Callam M, Ruckley CV, Allan PL. Foot volumetry and duplex ultrasonography after saphenous and subfacial perforating vein ligation for recurrent venous ulceration. ***Br J Surg*** 1993; 80: 845-858.
18. Dunn JM, Cosford FJ, Kernick VE, Campbell WB. Surgical treatment for venous ulcers is it worthwhile? ***Ann R Coll Surg Engl*** 1995; 77: 421-424.
19. Pierik EG, Wittens CH, van Urk H. Subfacial endoscopic ligation in the treatment of incompetent perforating veins. ***Eur J Vasc Endovasc Surg*** 1995; 9: 38-41.
20. Serven JM, Bianchi V, Hartshorne T, Bell PRF, Naylor AR. A clinical and hemodynamic investigation into the role of calf perforating vein surgery in patients with venous ulceration and deep venous incompetence. ***Eur J Vasc Endovasc Surg***1998; 16: 148-152.
21. Nelzén O. Prospective study of safety, patient satisfaction and leg ulcer healing following saphenous and subfacial endoscopic perforator surgery. ***Br J Surg*** 2000; 87: 86-91.