Variants and deformities of atlas vertebrae in Eastern Anatolian people

Ahmet Kavaklı, MD PhD, Atıf Aydınlıoglu, MD PhD, Hakkı Yeşilyurt, MD PhD, Ilter Kus, PhD, Semih Diyarbakırlı, PhD, Saadet Erdem, MSc, Ömer Anlar, MD.

ABSTRACT

Objective: At the craniocervical junction, developmental anomalies of the atlas may produce clinical symptoms by compressing on the vertebral artery, particularly during extreme rotational movements of the cervical spine. The aim of the present study was to investigate several varieties and deformities of the atlas vertebra from the skeletal specimens of Eastern Anatolian people.

Methods: This study was carried out over a 3-year period, 2000 through to 2002 in the Department of Anatomy, Firat, Yuzuncu Yil and Ataturk University, Turkey. Developmental anomalies and the variants of the first vertebrae were investigated on 86 atlas.

Results: Ponticulus posterior was observed with a low frequency on right as 2.3%. The bilateral localization was 10.5% and the left-side localization was 9.3%. Ponticulus lateralis showed an equal localization as 1.2% on the right, 1.2% on the left and 1.2% bilateral. In the present study, a complete subdivision of the joint surface was observed in 11 atlases (12.8%). Processus infratransversarius atlantis with a frequency between 1.2-7%, arthrotic formation and corona atlantis peridentals in 8 cases (9.3%) were also found.

Conclusion: The low frequency for fonticulus posterior might be peculiar to the population living in this area.

Saudi Med J 2004; Vol. 25 (3): 322-325

Craniocervical junction is the area comprising the inferior portion of the occipital bone that surrounds the foramen magnum and the first 2 cervical vertebrae, atlas and axis. Due to its complicated embryonic development, this area is easily susceptible to skeletal and neural developmental variants and anomalies, producing a wide spectrum of symptom.[1] Clinical syndromes develop as a result of mechanical disturbance of movement or of deformities of the cervical cord accompanying these developmental anomalies and the variants of skeletal elements. The bone deformity itself may be sufficient to cause pressure on the upper cervical cord and the vertebral artery during movements of the head and neck. In some situations (such as, transient vertebra basilar insufficiency, Barre-Lieou syndrome and chronic upper cervical syndrome) a developmental variant of the atlas is a significant factor.[2-5] Due to the clinical significance, a variation of the first vertebrae, retroarticular canal, was examined in several populations.[3,5-9] Recently, a review by Prescher[10] also reported the osseous variations in the craniocervical junction.

The present study was undertaken to investigate several varieties or deformities of the atlas vertebra from skeletal specimens of the Eastern Anatolian people. The purpose of the present study was to determine the frequencies of the varieties of the first

From the Department of Anatomy (Kavakli, Kus), School of Medicine, Firat University, Elazig, Department of Anatomy (Aydinlioglu, Erdem), Department of Neurology (Anlar), School of Medicine, Yuzuncu Yil University, Van, Department of Anatomy (Yesilyurt, Diyarbakırlı), School of Medicine, Atatürk University, Erzurum, *Turkey*.

Received 11th August 2003. Accepted for publication in final form 29th October 2003.

Address correspondence and reprint request to: Dr. Ahmet Kavakli, Fırat University, Department of Anatomy, School of Medicine, 23119 Elazıg, *Turkey*. Tel. +90 (424) 2370000. Fax . +90 (424) 2379138. E-mail: kavaklia@yahoo.com

Table 1 - Variations and arthrotic changes of atlas found in the present study (N=86).

Variations	Localization						Development			
	Right		Left		Bilateral		Complete		Incomplete	
	n	(%)	n	(%)	n	(%)	n	(%)	n	(%)
Ponticulus posterior	2	(2.3)	8	(9.3)	9	(10.5)	11	(12.8)	8	(9.3)
Ponticulus lateralis	1	(1.2)	1	(1.2)	1	(1.2)	2	(2.3)	1	(1.2)
Ponticulus posterolateralis					1	(1.2)	1	(1.2)		
Facies articularis superior atlantis bipartita	5	(5.8)	4	(4.7)	2	(2.3)				
Processus infratransversarius atlantis	3	(3.5)	1	(1.2)	6	(7)				
	Arthrotic formation									
	n	(%)								
Corona atlantis peridentalis	8	(9.3)								

cervical vertebra in the mentioned population, which have not been documented in the literature. The clinical symptoms and disturbances caused by the anomalies of the atlas were also reviewed.

Methods. This study was carried out over a 3-year period from 2000 through to 2002, in the Department of Anatomy, Firat, Yuzuncu Yil and Ataturk University, Turkey. The present study is based on the examination of 86 complete and undamaged adult atlas vertebrae. Most of them were the course materials obtained from cadavers for our medical students. The others were from a collection of vertebrae available in our departments. Our materials were of undetermined age and gender. Special attention was directed to the bridge formation and arthritic changes of the atlas, which are responsible for clinical symptoms.

Results. The results are summarized in **Table 1** as the shape variations and arthritic formations (**Figures 1-4**).

Bony bridges. (**Figure 1**) In the present study, ponticulus posterior was observed with a frequency of 2.3% on the right. The percentage of bilateral localization was 10.5% and the left-sided localization was found with 9.3%. Partial posterior bridge formation was found with 9.3% and complete formation with 12%. The lateral bony bridge, ponticulus lateralis represented an equal localization with frequencies of 1.2% on the right, 1.2% on the left and 1.2% bilateral. One case showed both posterior and lateral bridges (**Table 1**).

Facies articularis superior atlantis bipartite. (**Figure 2**) Eleven atlases (12.8%) presented with a complete subdivision of the joint surface was found in our study (**Table 1**). No incomplete subdivision was observed.

Processus infratransversarius atlantis. (**Figure 3**) This variation was observed with a frequency and localization of 3.5% on the right, 1.2% on the left and 7% bilateral (**Table 1**).

Arthritic deformities. (**Figures 3 & 4**). In our study, an arthritic formation at the arcus anterior atlantis was found in 8 cases with a frequency of 9.3% (**Table 1**).

Discussion. ***Bridge formations of the atlas vertebrae: ponticulus posterior and ponticulus lateralis.*** According to standard anatomical description, a wide groove for vertebral artery and suboccipital nerve on the superior aspect of the posterior arch of the atlas vertebra crosses behind each lateral mass. In some cases it is partly or wholly made of a foramen by bone arching back from the superior surface of the lateral mass.[11] This bony bridge was first reported by MacAlister.[6] It was variously described as ponticulus posterior or posticus, Kimmerle's variant, retroarticular canal, foramen retro-articular superior, retro condylar vertebral artery ring, posterior atlantoid foramen, foramen arcual and atlas bridging.[2-5,8,10,12,13] The ponticulus posterior was observed with a low frequency on the right (2.3%) (**Table 1**). The percentage of the bilateral and left side localization (**Figure 1**) showed no difference with those of the American population, which was reported to be between 9-15%.[3,5,6,9] Its incidence in the Indian population was found as 11.4%[14] while in the South African population, it was reported with complete occurrence as 11.7% on the right and 24.6% on the left.[4] Our study presented with partial posterior bridge formation with 9.3% and complete formation with 12.8% (**Table 1**). Taitz and Nathan[5] found partial formation as 25.9% and complete formation as 7.9%.

Ponticulus lateralis. Represents the lateral bridge, which extends from the upper edge of the massa lateralis to fuse with the posterior root of the transverse process.[5,10] The frequency of the lateral

Figure 1 - A bony arch bridging the sulcus arteriae vertebralis (arrows) behind the massa lateralis atlantis, namely, ponticulus posterior. A complete bridge over the foramen processus transversi of the atlas, ponticulus lateralis (asterisk).

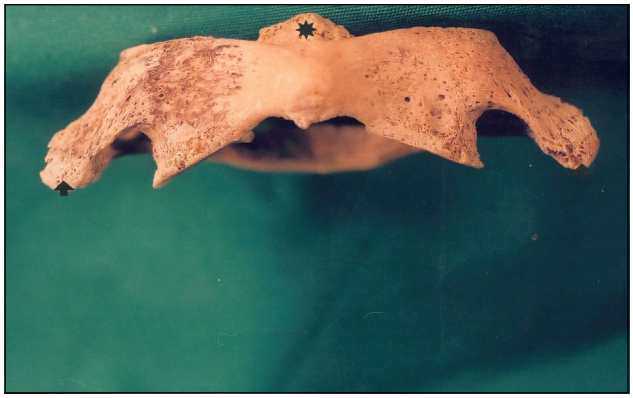

Figure 3 - A bony extension in the caudal direction, emerging from the transverse process of the atlas (such as, processus infratransversarius atlantis) (arrows) and arthrotic formation of the atlas at the arcus anterior atlantis (asterisk).

Figure 2 - Superior articular facet of atlas vertebra showing subdivision into 2 parts, facies articularis superior atlantis bipartite, with bilateral localisation (asterisk).

Figure 4 - A bony element at the arcus anterior atlantis, corona atlantis peridentalis or "coulisse of the atlas" (asterisk).

bridge in our study generally resembles to that of the previous studies. In the literature, this variation is reported with a percentage between 1.8-3.8,[5,10,15] which agrees with our findings. Our study also presented an equal localization for this formation, namely 1.2% on the right, 1.2% on the left and 1.2% bilateral. Our observations showed a ratio of 2:1 for complete and incomplete formation, similar to Taitz and Nathan[5] finding. In our study, one atlas (1.2%) showed both posterior and lateral bridges (**Table 1**), which accords with the literature.[5,10] The origin of atlas bridging has been debated in the literature. The opinion of ancient authors was that the posterior bridge is a direct homologue of the superior oblique process of other mammals.[6,16] Familial nature of atlas bridging proposed by Selby et al[17] and an acquired ossification of ligaments occurring with aging[5,8] was not the same with the study of Lamberty and Zivanovic,[3] that cartilaginous ponticuli posteriores have been seen in fetuses and children. Recently, atlas bridging is supposed to develop from materials of the dorsal arch and the lateral extensions of the proatlas and to belong to the manifestations of the occipital vertebra.[10]

The clinical significance of bridge formation has been discussed in reference to their possible effect on normal vertebral artery function due to the ponticulus formations that can be identified on the conventional lateral and a.-p. radiographs.[3,10,18] This formation can cause compression of the vertebral artery, particularly during extreme rotational movements of the cervical spine. This may play a role in reduction of vertebral artery blood flow, leading to symptoms of vertebrobasilar insufficiency.[3,4,7] A correlation between migraine cervicale and the presence of a ponticulus posterior was reported. In such cases, resection of the ponticulus may be indicated, which results in decompression of the vertebral artery and the accompanying nerves.[10,18]

Facies articularis superior atlantis bipartita. The superior articular surface of the

atlas is concave and elongated, joint with the corresponding occipital condyle. Sometimes the articular surface is divided into 2-facet.[11] In the present study, a complete subdivision of the joint surface was observed in 11 atlases (12.8%) (**Table 1**) (**Figure 2**). Prescher[10] found this variation in 28 out of 200 atlases (14%): 7.5% on the right, 2% on the left, 4.5% bilateral. In the literature, the frequency of the bipartite superior joint surface was reported between 5.5-33%.[10,19] That this variation develops from 2 sources, namely, the proatlas and C1 segment, may explain its origin.[10,18,20] Clinical symptoms and disturbances caused by facies articularis superior bipartita atlantis have not been reported. However, it may be mistaken for fractures in tomography.[21]

Processus infratransversarius atlantis. This is a bony extension emerging from the transverse process in caudal direction.[10] In the present study, this structure was observed in different localization with a frequency of 1.2-7% in variable lengths (**Figure 3**). Clinically, this variation may represent symptomatic disturbances at the craniocervical junction.[22] Patients with symptomatic variations of the craniocervical junction often complain of pain in the neck region or at the back of the head or they suffer from vertigo or disturbances in balance. Principal mechanisms of symptoms are mechanical compression of nervous and vascular structures, marked instability or in contrast, elevated rigidity.[23]

Arthrotic formations simulating variants: Corona atlantis peridentalis. In the present study, arthritic formation, corona atlantis peridentalis or "coulisse of the atlas" termed by Prescher,[10] at the arcus anterior atlantis was found in 8 cases (9.3%), corresponding to the "coulisse of the dens" (**Figure 3 & 4**). Lombardi[24] reported that these formations might be partly attributed to the occipital vertebra. He also observed that the patients in his series were free of any physical disturbances attributable to the malformation.

In conclusion, the findings from our study generally agree with those of the previous. The only difference was that ponticulus posterior was observed with a low frequency on the right, only perhaps encountered by chance. It might even be peculiar to the population living in the area. Our results for processus infratransversarius atlantis, arthrotic formation and corona atlantis peridentalis, will also be compared with those of further works for our literature survey failed to find any data concerning them in other populations.

Acknowledgment. The authors would like to thank Assoc. Prof. Hassan Boynukara who made the necessary correction of the English grammar.

References

1. Kumar A, Jafar J, Mafee M, Glick R. Diagnosis and management of anomalies of the craniovertebral junction. ***Ann Otol Rhinol Laryngol*** 1986; 95: 487-497.
2. Buna M, Coghlan W, deGruchy M, Williams D, Zmiywsky O. Ponticles of the atlas: a review and clinical perspective. ***J Manipulative Physiol Ther*** 1984; 7: 261-266.
3. Lamberty BGH, Zivanovic S. The retro-articular vertebral artery ring of the atlas and its significance. ***Acta Anat*** 1973; 85: 113-122.
4. Mitchell J. The incidence and dimensions of the retroarticular canal of the atlas vertebra. ***Acta Anat (Basel)*** 1998; 163: 113-120.
5. Taitz C, Nathan H. Some observations on the posterior and lateral bridge of the atlas. ***Acta Anat (Basel)*** 1986; 127: 212-217.
6. MacAlister A. Notes on the development and variations of the atlas. ***Journal of Anatomy and Physiology*** 1893; 27: 518-542.
7. Ossenfort WP. The atlas in whites and Negroes. ***Am J Phys Anthropol*** 1926; 9: 439-443.
8. Pyo J, Lowman RM. The 'ponticulus posticus' of the first cervical vertebra. ***Radiology*** 1959; 72: 850-854.
9. Romanus T, Tovi A. A variation of the atlas: Roentgenologic incidence of a bridge over the groove on the atlas for the vertebral artery. ***Acta Radiol Diagn (Stockh)*** 1964; 2: 289-297.
10. Prescher A. The craniocervical junction in man, the osseous variations, their significance and differential diagnosis. ***Anat Anz*** 1997; 179: 1-19.
11. Williams PL, Warwick R, Dyson M, Bannister LH. Grays Anatomy. 37th ed. London (UK): Churchill Livingstone; 1989. p. 318.
12. Kendrick GS, Biggs NL. Incidence of the ponticulus posticus of the first cervical vertebra between ages six to seventeen. ***Anat Rec*** 1963; 145: 449-454.
13. Saunders SR, Popovich F. A family study of two skeletal variants: Atlas bridging and clinoid bridging. ***Am J Phys Anthropol*** 1978; 49: 193-204.
14. Gupta SC, Gupta CD, Arora AK, Maheshwari BB. The retrotransverse groove (canal) in the Indian atlas vertebrae. ***Anat Anz*** 1979; 145: 514-516.
15. Radojevic S, Negovanovic B. La Goittiére et les anneaux osseux de l'artére vertébrale de l'atlas. ***Acta Anat (Basel)*** 1963; 55: 186-194.
16. Allen W. The varieties of the atlas in the human subject and the homologies of its transverse process. ***J Anat*** 1879; 14: 18-28.
17. Selby S, Garn SM, Kanareff V. The incidence and familial nature of a bony bridge on the first cervical vertebra. ***Am J Phys Anthropol*** 1955; 13: 129-141.
18. Von Turklus D, Gehle W. The upper cervical spine. London (UK): Butterworth Heinemann; 1972. p. 93.
19. Singh S. Variations of the superior articular facets of atlas vertebrae. ***J Anat*** 1965; 99: 565-571.
20. Ganguly DN, Singh-Roy KK. A study on the cranio-vertebral joint in the man. ***Anat Anz*** 1964; 114: 433-452.
21. Kattan KR. Two features of the atlas vertebra simulating fractures by tomography. ***Am J Roentgenol*** 1979; 132: 963-965.
22. Schmidt H. Über den processus infratransversarius. Fortschr Geb Rontgenstr. ***Fortschr Geb Rontgenstr Nuklearmed*** 1968; 109: 110-111.
23. Prescher A, Brors D, Adam G. Anatomic and radiologic appearance of several variants of the craniocervical junction. ***Skull Base Surgery*** 1996; 6: 83-94.
24. Lombardi G. The occipital vertebra. ***Am J Roentgenol*** 1961; 86: 260-269.