# Mycetoma of the hand

*Mohamed E. Abd El-Bagi,* FFRRCSI, *Osman Abdul Wahab,* DMRD, *Mohamed A. Al-Thagafi,* MD, *Hassan El-Sheikh,* MD, *Khalid Al-Salman,* MD, *Mohamed K. Taifoor,* MBBS, *Fatmah M. Osman,* MBBS.

## ABSTRACT

**Objective:** To describe the incidence and radiographic signs of hand infection in mycetoma.

**Methods:** A retrospective review was carried out from the radiographic records of 516 confirmed cases of mycetoma seen between January 1994 and October 2002 at the referred outpatient clinic of the Mycetoma Research Center, Soba Teaching Hospital, Khartoum University, Khartoum, Sudan.

**Results:** The hands were involved in 24 (4.6%) of the 516 patients. The wrist was involved in 9 (1.7%). Total involvement of the hand and wrist together was 33 (6.4%) of the 516 patients. Radiographic signs included fanning of the metacarpals, bone erosions, sclerosis, periostitis and soft tissue swelling. The most common sign was soft tissue swelling in 29 (88%) while bones were involved in 15 (45%) of the 33 patients.

**Conclusion:** Hand infection in this series is less than previous reports. A wide range of radiographic signs is reported in hand mycetoma. This is the first detailed report of the radiographic findings in mycetoma of the hand. Early detection of mycetoma infection is important to avoid the need for amputation if diagnosis is delayed.

**Saudi Med J 2004; Vol. 25 (3): 352-354**

Mycetoma is a chronic destructive granulomatous infection[1] affecting the skin subcutaneous tissues and bones.[2] The disease is endemic in dry countries between latitudes 30° North and 15° South.[3] Mycetoma was also reported in Europe and North America.[4] This peculiar clinical entity can be caused either by bacteria "actinomycetoma" or by "true fungi" "maduromycetoma".[5] Mycetoma is characterized by the clinical triad of painless soft tissue swelling, cutaneous sinuses and presence of colored grains.[5] This chronic infection has a prolonged sinister course and early diagnosis is important to avoid amputation.[6] Fahal and Hassan[5] and Khatre et al[7] have recently reported the involvement of the hand in 12% of mycetoma patients. However, previous reports indicated a lesser frequency of patients with mycetoma swelling in the hand.[8] Abbot[9] reported a 14 (6.6%) incidence of hand infection from a large series of 213 mycetoma patients, similar to Woodruf.[10] Other mycetoma series did not include any cases of hand infection.[11,12] None of the previous reports have described the radiographic findings in hand mycetoma with detail. The objective of this paper is to describe the incidence and radiographic signs of hand infection with mycetoma agents.

**Methods.** Five hundred and sixteen radiographic records of the patient population who attended the out patient clinic of the Mycetoma Research Center, Soba Teaching Hospital, Khartoum University, Khartoum, Sudan, between January 1994 and October 2002 were randomly included in this review. Computerized tomography, ultrasound and magnetic resonance imaging, which are rarely performed, were excluded. All patients

From the Mycetoma Research Centre (Abd El-Bagi), Department of Radiology (Abdul Wahab, El Sheikh, Taifoor, Osman), Soba Teaching Hospital, Khartoum University, *Sudan*, Department of Radiology (Al-Thagafi, Salman), Armed Forces Hospital, Riyadh, *Kingdom of Saudi Arabia*.

Received 18th May 2003. Accepted for publication in final form 29th October 2003.

Address correspondence and reprint request to: Dr. Mohamed E. Abd El-Bagi, Senior Consultant Radiologist (Teaching), Armed Forces Hospital, PO Box 7897, Riyadh 11159, *Kingdom of Saudi Arabia*. Fax. + 966 (1) 4767348. Email: drm_bagi@hotmail.com

were confirmed to have mycetoma by clinical signs and biopsies. Patients demographics were recorded. The site and pattern of mycetoma infection on radiographs were noted. Three hundred and ninety-nine (77.3%) of those 516 mycetoma patients were males. One hundred and seventeen (23%) were females. Ages were 4-65 with a mean age of 27.4 years.

**Results.** The hand was involved in 24 (4.6%) while the wrist was involved in 9 (1.7%), a total of 33 (6.3%). There was a combined hand-foot syndrome in 5 (1%) of the 516 patients representing 15% of the 33 hand infections. The most common radiographic sign encountered was soft tissue swelling in 29 (88%) of the 33 patients (**Figure 1**). This could be minimal or large. Diffuse sclerosis was noted in 9 (27.2%) (**Figure 2**) and osteoporosis in 2 (6.1%). Bones were involved in 15 (45.4%) of the 33 cases suffering hand mycetoma infection. Bone cavities (**Figure 3**) were seen in 12 (36.4%). The size of the cavities varied from 1-22 mms. Periostitis was seen in 5 (15.1%) of those patients (**Figure 4**). Joint involvement was present in 5 (15.1%). Bone erosions were seen in 8 (24.2%) of the 33 patients while bowing or external cortical scalloping (**Figure 1**) was seen in 9 (27.3%). Recurrence after previous amputation of a finger was seen in 2 patients (6%). Radiographic appearance could mimic other diseases including osteosarcoma. (**Figure 4**)

**Discussion.** Hand mycetoma is not well described unlike pedal mycetoma.[2] Previous descriptions of radiographic findings were brief and limited.[13-15] Those reports involved small numbers of patients.[13-15] In temperate countries, osteomyelitis due to mycetoma agents was reported following traumatic laceration due to "punch" injuries of fist cuffs.[16] Mycetoma usually affects the foot.[2] Extrapedal disease is less common.[9] In this series, hand infection is less than the previous reports[5,7] but

**Figure 1 -** Oblique radiograph of the right hand showing small soft tissue swelling at the dorsum of the hand and the thenar eminence (white arrow heads). Note extrinsic compression of the medial cortex of the thumb metacarpal manifest as bowing (black arrow heads). This indicates a pre-invasive stage.

**Figure 3 -** Oblique radiograph of the right hand showing a bilocular cavity in the head of the middle metacarpal (white arrow). Note amputation of the ring ray of phalanges and metacarpal. A small remnant of the base of the right ring finger metacarpal is present (black arrow head). The causative agent was fungal maduromycetoma causing recurrence after amputation.

**Figure 2 -** Frontal radiograph of the right index and middle fingers showing subtle diffuse sclerosis (back arrow heads) of the bones due to extrinsic irritation of the bone by mycetoma infection of the soft tissues (white arrow head).

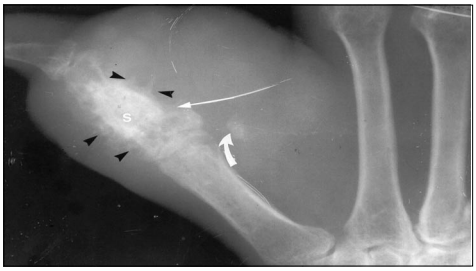

**Figure 4 -** Radiograph of the hand showing periosteal reaction (black arrow head). Note: soft tissue swelling, marginal erosions (curved white arrows) and small cavities (straight white arrow). Appearances could be confused with osteosarcoma. Note soft tissue swelling (curved with arrow), marginal erosions and small cavities (straight white arrow)

higher than others.[11,12] Our results concurred with previous studies in the same country[4,10] Our results are, however, based only on the positive radiographs. A clinical review to include patients who did not have radiographs or whose radiographs were negative at the time of examination would be more accurate. Soft tissue swelling is almost always present in mycetoma patients (88%). Bones were involved in nearly half of the cases (45%). The number as well as the size of bone cavities was variable. It is known that bacterial "actinomycetoma" produces numerous small cavities while fungal "maduromycetoma" produces larger and fewer cavities (**Figure 3**).[17] Bowing or external cortical scalloping is a warning sign of pre-invasive stages (**Figure 1**) while diffuse sclerosis is a sign of irritation due to impending bone invasion[2] (**Figure 2**) Joint involvement indicates an unfavorable outcome. The worst situation is where re-amputation becomes a necessity. Unfortunately, this can occur leading to re-amputation with disastrous physical and psychological consequences.[5] The radiographic appearance of hand mycetoma may be confused with other diseases including joint arthropathies benign tumors or even malignant tumors (**Figure 4**).

This study provides a description of radiographic findings in hand mycetoma. To our knowledge, this is the largest radiographic series for patients suffering hand mycetoma. A wide range of radiographic signs can be seen in hand infections with mycetoma. Awareness of these radiographic signs is important for early detection of this disease to avoid surgical amputation if diagnosis is delayed.

**Acknowledgment.** We would like to thank Professor A. H. Fahal for his encouragement and allowing free access to the records of the Mycetoma Research Centre at Khartoum University, Sudan. We wish to thank the Radiologists and staff of the X-ray Department, Soba Hospital, Sudan for maximal cooperation. We are grateful to Mrs. Sally Lumanlan for typing the manuscript and to the Medical Illustration Department, Armed Forces Hospital, Riyadh, Kingdom of Saudi Arabia for producing the illustrations.

## References

1. Mahgoub ES, Muray IG. Mycetoma. London (UK): William Heinemann Medical Books; 1973. p. 1-116.
2. Abd El-Bagi ME. New radiographic classification of bone involvement in pedal mycetoma. ***AJR Am J Roentgenol*** 2003; 180: 665-668.
3. Welsh O. Mycetoma. ***Semin Dermatol*** 1993; 12: 290-295.
4. Tight RR, Bartlett MS. Actinomycetomas in the United States. ***Rev Infec Dis*** 1981; 3: 1139-1150.
5. Fahal AH, Hassan MA. Mycetoma. ***Br J Surg*** 1992; 79: 1138-1141.
6. Abd Bagi ME, Sammak B, Al-Shahed M, Yousef BA, Demuren OA, Al-Jared M et al. Rare bone infections "excluding the spine". ***Eur Radiol*** 1999; 9: 1078-1087.
7. Khatri ML, Al-Halali HM, Khalid MF, Saif SA, Vyas MC. Mycetoma in Yemen: Clinicoepidimiologic and histologic study. ***Int J Dermatol*** 2002; 41: 586-593.
8. Hitchcock TF, Amadio PC. Fungal infections. ***Hand Clin*** 1989; 5: 599-611.
9. Abbot P. Mycetoma in Sudan. ***Trans Roy Soc Trop Med Hyg*** 1956; 78: 376-379.
10. Woodruff AW. In: Woodruff AW, Wright SG, editors. Medicine in the Tropics. 2nd ed. London (UK): Churchill Livingstone; 1984. p. 379.
11. Czechowski J, Nork M, Haas D, Lestringant G, Ekelund L. MR and other imaging methods in the investigation of mycetomas. ***Acta Radiol*** 2001; 42: 24-26.
12. Lestringant GG, Al-Homsi MF, Qayed KI, Nsanze H. Presentation and treatment of actinomycetoma in Tawam Hospital, Al Ain, UEA. ***J Dermatolog Treat*** 2001; 5: 87-91.
13. Altman DT, Lubahn JD, Kuhn PJ. A case report and review of mycetoma of the hand: a diagnostic and therapeutic challenge. ***J Hand Surg [Am]*** 1994; 19: 998-1002.
14. Martinez RE, Couchel S, Swartz WM, Smith MB. Mycetoma of the hand. ***J Hand Surg [Am]*** 1989; 14: 909-912.
15. Bourrel P, Andrew JM, Cazenave JC. Mycetoma of the hand. Apropos of 10 cases. ***Ann Chir*** 1989; 43: 814-823.
16. Blinkhorn RJ Jr, Strimbu V, Effron D, Spagnuolo PJ. 'Punch' actinomycosis causing osteomyelitis of the hand. ***Arch Intern Med*** 1988; 148: 2668-2670.
17. Bendl BJ, Mackey D, Al-Saati F, Sheth KV, Ofole SN, Bailey TM. Mycetoma in Saudi Arabia. ***J Trop Med Hyg*** 1987; 90: 51-59.