

# Congenital esophageal stenosis

*Mahmoud A. Machmouchi, DESC-AECP, Mohamed A. Al Harbi, FRCSC, Khalid A. Bakhsh, FRCSC,  
Zain H. Al Shareef, FACHARZT, FACS.*

---

### ABSTRACT

Congenital esophageal stenosis (CES) is an uncommon anomaly that rarely goes undiagnosed until adulthood. We report 2 cases of CES. The first was a one-month-old baby boy who was referred for work up of swallowing disorder and recurrent pneumonias. The diagnosis was confirmed by a continuous fluoroscopic esophagogram, and endoscopic exploration. Simple dilatation resolved his symptoms completely. The second was an 18-month-old boy, who was referred with a feeding gastrostomy due to complete esophageal obstruction. Resection and end-to-end anastomosis was performed with uneventful postoperative course.

Saudi Med J 2004; Vol. 25 (5): 648-650

---

Congenital esophageal stenosis (CES) is a rare condition that has historically been confused with esophageal strictures secondary to inflammation, especially due to gastroesophageal reflux. Congenital esophageal stenosis is rare reported to occur once in every 25,000 to 50,000 births.<sup>1</sup> As of 1995, only 500 cases have been described in the world literature.<sup>1,2</sup> We report 2 cases of CES to highlight 3 facts: First, the evaluation of swallowing disorder should be based on a continuous fluoroscopic esophagogram, not only on a simple esophagogram or upper gastrointestinal (GI) series. Second, in severe esophageal stenosis if gastrostomy is indicated, a string should be inserted to facilitate the later dilation of the stenosis and or exploration of the esophagus. Third, whenever esophageal stenosis is diagnosed the evaluation of patency of the distal esophageal segment and its softness is critical for appropriate planning. This evaluation should be performed during the same general anesthesia for gastrostomy if indicated.

**Case Report.** *Patient One.* A one-month-old baby boy a product of spontaneous vaginal delivery,

after an uneventful pregnancy to a gravid 2, Para 2 mother. The parents were first-degree cousins. He was referred as of chocks during feeding since birth, which was complicated later on by recurrent pneumonias. An 8 french size naso-gastric tube passed without difficulties. An upper GI study confirmed patency of the esophagus, and minimal aspiration was seen as well. He was referred to us for evaluation of esophageal dysmotility with a nasogastric tube feeding. Upper GI study was repeated under fluoroscopic evaluation. This revealed hold up of barium at the level of the proximal third thoracic vertebra indicative of esophageal stenosis at this level (no tracheo-esophageal fistula). This was confirmed endoscopically, which showed a short annular stenosis (less than one cm in length). This was dilated, and the rest of the esophagus appeared normal and soft. This simple and progressive dilatation resolved his symptoms completely. This patient however may need further dilatations for complete recovery.

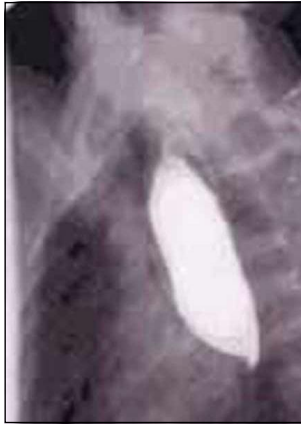*Patient 2.* An 18-month-old boy, a product of full term uneventful pregnancy, through

---

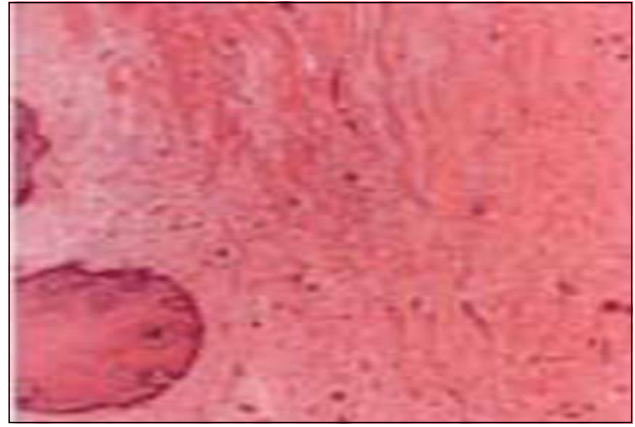
From the Department of Surgery, King Faisal Specialist Hospital and Research Centre, Jeddah, Kingdom of Saudi Arabia.

Received 20th September 2003. Accepted for publication in final form 30th December 2003.

Address correspondence and reprint request to: Dr. Mahmoud A. Machmouchi, Consultant, Pediatric Surgeon, Department of Surgery-MBC 40, King Faisal Specialist Hospital and Research Centre, Jeddah 21499, Kingdom of Saudi Arabia. Tel. +966 (2) 6677777. Fax. +966 (2) 6677777 Ext. 5815.



**Figure 1** - Complete esophageal stenosis, with proximal dilation.



**Figure 2** - Fibrosis of the esophageal wall.

spontaneous vaginal delivery to non-consanguineous parent. His mother was 42-year-old multigravida. He was healthy till the age of 9-months apart from unusually prolonged feeding time. At the age of 9 months, with initiation of solid food intake he started to develop progressive dysphagia to the stage that he became cachectic. At age of 14-months, he was seen at a peripheral hospital and admitted with the diagnoses of malnutrition (weight less than 3 percentile), and dehydration. Upper GI contrast study showed severe esophageal stricture between the middle and distal third of the esophagus. A feeding gastrostomy was performed without exploration of the distal esophageal segment, for example stricture length was not assessed. Although he gained weight after this procedure, he was still having aspiration problems. Four months later, he was referred to our hospital where a new esophageal contrast study confirmed an obstruction of the esophageal lumen, with dilation of the proximal segment ending conically simulating achalasia (**Figure 1**). Gastrogram through the gastrostomy did not show any evidence of gastro esophageal reflux. Exploration by flexible and rigid esophagoscopy revealed a very tight stricture, and a guide wire (Glide wire) could not be introduced through the stricture. Endoscopy through the gastrostomy showed a soft and normally patent distal esophagus. A right thoracotomy through the seventh intercostal space, by a transpleural approach was carried out. The esophagus was exposed and showed a 2 cm, firm in consistency, cord like segment, and starting 5 cm proximal to the hiatus. This segment was resected and end-to-end anastomoses was performed by single layer interrupted vicryl suture. Histopathology confirmed the congenital nature of the lesion, with thick circumferential fibro muscular wall but devoid of cartilage tissue (**Figure 2**). The

tiny lumen at this level was completely obstructed with mucosal edema and impacted food debris. Postoperative course was uneventful. The patient remained asymptomatic and did not require dilation for more than 1 year of follow up.

**Discussion.** Congenital esophageal stenosis is defined as an intrinsic esophageal stenosis, caused by congenital malformation of esophageal wall architecture.<sup>1</sup> There are 3 forms of CES,<sup>3,4</sup> in the first form the stenosis is associated with the presence of abnormal tissue in the esophageal wall such as respiratory tissue including cartilage and ciliated epithelium-‘tracheobronchial remnants’. This lesion is usually located in the distal third of the esophagus. The second and third forms are in fact, variant of esophageal atresia; the 2 segments of the esophagus are juxtaposed but separated by either a full thickness of esophageal wall ‘fibromuscular’, or by a thin diaphragm ‘muco membranous’. The diaphragm or web does not occlude the lumen completely, and is reported as the rarest of the 3 forms of CES. The location of the CES is varied, but it affects more frequently the mid distal segment. As found in our cases, CES is usually a segmental anomaly, with a mean length less than 3 cm in children. The embryologic development of these rare lesions is probably similar to atresia.<sup>5</sup> The frequent presence of respiratory tissue at the level of the stenosis and, its association with esophageal atresia support this observation. The exact nature of the embryologic anomaly that results in tracheo-esophageal anomalies is still unknown, and the incidence of other anomalies associated with CES is reported to be 17-33%. These anomalies include esophageal atresia, tracheoesophageal fistula; cardiac; kidney; intestinal; anorectal; hypospadias; malformation of the head, face, and limbs; and chromosomal anomalies.<sup>1-5</sup> No other malformations were found in our 2 cases. This

non-random association may be an evidence of generalized disturbance.<sup>6</sup> Congenital esophageal stenosis has an equal sex distribution. Moreover, it is unusual to find the involvement of subsequent children with CES as most of these cases are found as spontaneous occurrences. Esophageal peristalsis is normal in case of segmental CES, and symptoms usually began in early infancy but, delayed diagnosis is common, where dysphagia may be delayed until solid foods are introduced.<sup>7,8</sup> Difficulty to swallow solids may lead to inadequate intake of fluids and nutrients, with an increased risk of regurgitation and aspiration pneumonia. In some patients, a foreign body in the esophagus may be the first symptom noted.<sup>6</sup>

Since the clinical picture is varied, a high index of suspicion is essential to arrive at an early diagnosis. In young, middle age or adult individuals, persistent dysphagia and poor weight gain,<sup>9-11</sup> are usually the leading symptoms. Upper GI contrast study shows a segmental stricture of the distal segment and oesophagogastric junction should be evaluated for future treatment planning.<sup>3,5,12</sup> Proximal dilatation is a sign of chronic and severe stenosis. Endoscopic appearance is a concentric stricture or multiple rings, sometime tracheal in appearance (depend of the length of the stenosis).<sup>13</sup> When exists this last appearance is characteristic of congenital esophageal stenosis.<sup>11-13</sup> If endo-sonography performed, it will show a focal circumferential and hypoechoic wall thickening disrupting the normal layer pattern of the esophagus.<sup>11-13</sup> Balloon dilation is the treatment of choice for this disease.<sup>14</sup> Esophageal boogieing is known to be associated with increased risk of esophageal leakage.<sup>15,16</sup> Congenital esophageal stenosis secondary to tracheobronchial remnants or tight, and thick fibro muscular hyperplasia do not respond to dilatation and should be resected.<sup>15-17</sup> Congenital esophageal stenosis should be considered a possibility in patients with stricture presumed to be inflammatory in nature, which fails to respond to standard therapy. Membranous diaphragm usually responded to dilation or may required endoscopic excision.<sup>8</sup> It is important to clearly identify the location of the stenosis before operation in order to plan the operative approach. At exploration the use of balloon catheter passed beyond the stenosis, inflated and pulled back against the stenosis, has been suggested as a helpful technique to delineate the point externally. The anti reflux procedure, and more rarely, esophageal replacement should be considered in certain cases.<sup>5</sup>

In conclusion CES is an uncommon anomaly, must be diagnosed before reaching complicated stage. Surgical resection is indicated when the conservative treatment failed. The prognosis is generally good.

## References

1. Nihoul-Fekete C, Revillon Y. Congenital oesophageal stenosis. A review of 20 cases. *Pediatr Surg Int* 1987; 2: 86-89.
2. Murphy SG, Yasbeck S, Russo P. Isolated congenital oesophageal stenosis. *J Pediatr Surg* 1995; 30: 1238-1241.
3. Okhawa H, Takahashi H, Hashinoy, Sato H. Lower oesophageal stenosis in association with tracheo bronchial remnants. *J Pediatr Surg* 1975; 10: 453-455.
4. Ramesh JC, Ramanujam TM, Jawaram G. Congenital oesophageal stenosis: report of three cases, literature review, and a proposed classification. *Pediatr Surg Int* 2001; 17: 188-192.
5. Kawahara H, Imura K, Yagi M, Kubota A. Clinical characteristic of congenital oesophageal stenosis distal to associated oesophageal atresia. *Surgery* 2001; 129: 29-38.
6. Bluestone CD, Kerry R, Sieber WK. Congenital esophageal stenosis. *Laryngoscope* 1969; 79: 1095-1103.
7. Bhaskar SK, Bin-Sagheer S, Brady PG. Congenital oesophageal stenosis. *Dig Dis* 2000; 18: 186.
8. Feng FH, Kong MS. Congenital oesophageal stenosis treated with endoscopic balloon dilation: report of one case. *Acta Pediatr Taiwan* 1999; 40: 351-353.
9. Oh CH, Levine MS, Katzka DA, Rubesin SE, Pinheiro LW, Amygdalos MA et al. Congenital oesophageal stenosis in adult: clinical and radiographic finding in seven patients. *AJR* 2000; 176: 1179-1182.
10. Longstrth GF. Congenital oesophageal stenosis. *Am J Gastroenterol* 2000; 95: 32-36.
11. Younes Z, Johnson DA. Congenital oesophageal stenosis: clinical and endoscopic features in adults. *Dig Dis* 1999; 17: 172-177.
12. Langdon DE. Congenital oesophageal stenosis, corrugated ringed oesophagus, and eosinophilic oesophagitis. *Am J Gastroenterol* 2000; 95: 2123-2124.
13. Katzka DA, Levine MS, Ginberg GG, Hammod R, Katz PO, Insko EK et al. Congenital oesophageal stenosis in adults. *Am J Gastroenterol* 2000; 95: 32-36.
14. Gilchris BF, Scriven R, Sanchez J, Poneito T, Klotz D. The application of vascular technology to esophageal and airway strictures. *J Pediatr Surg* 2002; 37: 47-49.
15. Shorter NA, Mooney DP, Vaccaro TJ, Sargent SK. Congenital oesophageal stenosis in adults. *J Pediatr Surg* 2000; 34: 1742-1745.
16. Pesce C, Musi L, Campobasso P, Costa L, Mercurella A. Conservative non-surgical management of congenital oesophageal stenosis associated with oesophageal atresia. *Ital J Gastroenterol Hepatol* 1999; 31: 899-890.
17. Vasudevan SA, Kerendi F, Lee H, Ricketts RR. Management of congenital esophageal stenosis. *J Pediatr Surg* 2003; 37: 1024-1026.