

# Propionic acidemia and zinc deficiency presenting as necrolytic migratory erythema

Ammar C. Al-Rikabi, MD, FRCPath (UK), Hala I. Al-Homsi, MBBS, AB Dermatology.

---

## ABSTRACT

Necrolytic migratory erythema was first described in 1942 in a patient with pancreatic islet cell carcinoma. The disease can, however, have other etiologies including nutritional dermatoses. Here, we describe the clinicopathological picture of a 7-year-old female patient who presented with necrolytic migratory erythema which we believe is secondary to a rare combination of zinc deficiency and propionic acidemia.

Saudi Med J 2004; Vol. 25 (5): 660-662

---

Nutritional dermatoses usually demonstrate common periorificial lesions characterized by the development of an erythematous, maculopapular to vesicular eruption similar to moniliasis or psoriasis, or both. These disorders include acrodermatitis enteropathica and necrolytic migratory erythema. They can be caused by biotinidase, zinc, multiple decarboxylase and essential fatty acid deficiencies. In this report, we present a rare association of zinc and propionyl carboxylase deficiencies in a clinical case of necrolytic migratory erythema.

**Case Report.** A 7-year-old Qatari female presented to our dermatology unit with a history of erythematous and scalded skin lesions on both upper and lower limbs and trunk which appeared a few days prior to consultation. Clinical examination revealed, in addition to the described lesions, several flaccid bullae on both lower limbs and soles with well defined and circumscribed erythematous scaly patches on the perioral, periorbital and genital areas. The patient was born by normal delivery after a full term pregnancy but had many hospital

admissions and was previously diagnosed to have propionic acidemia (caused by complete deficiency of propionyl carboxylase enzyme) and primary hypothyroidism (which was treated by replacement therapy). From the dermatological point of view, the clinical differential diagnosis at this stage was that of staphylococcal scalded skin syndrome, drug eruption and possible trace elements deficiency leading to a nutritional dermatosis. A skin punch biopsy was performed and sent to the histopathology department for processing and evaluation.

**Histopathological findings.** Histopathological examination of the hematoxylin and eosin stained sections of the skin biopsy showed a thin cornified layer with underlying confluent parakeratosis containing degenerate nuclei. The upper parts of the malpighian layer contained pale keratinocytes (**Figure 1**). Minimal psoriasiform hyperplasia was also noticed in places. The dermis showed no significant pathology.

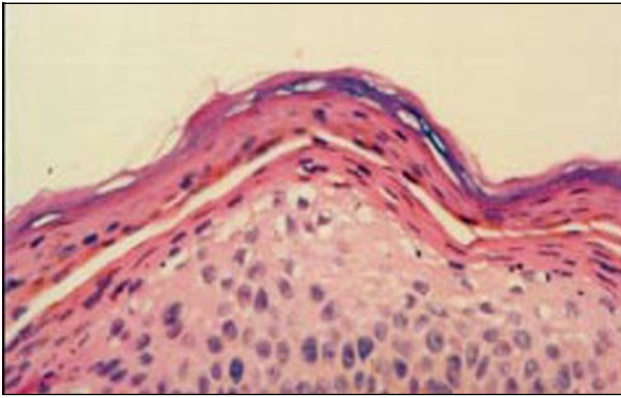
Based on the above histological features a diagnosis of necrolytic migratory erythema was made with a recommendation to exclude the

---

From the Department of Pathology (Rikabi), Hamad General Hospital, and the Department of Dermatology (Al-Homsi), Rumailah Hospital, Doha, Qatar.

Received 22nd September 2003. Accepted for publication in final form 28th December 2003.

Address correspondence and reprint request to: Dr. Ammar C. Al-Rikabi, Chairman and Consultant Histopathologist, Hamad Medical Corporation, PO Box 3050, Doha, Qatar. Tel. +974 4392591. Fax. +974 4446030. E-mail: ammar\_rikabi@hotmail.com



**Figure 1** - Necrolytic migratory erythema. The epidermis is relatively thin and covered by a continuous and thick layer of parakeratosis, which include necrotic and vacuolated keratinocytes. Hematoxylin and Eosin x 400.

presence of glucagonoma, pellagra and zinc deficiency. A serum zinc was ordered and reported as being 44.5 ug/dl (reference range 70-150 ug/dl). The patient had no evidence of elevated glucagon levels, and no detectable tumor could be found. Pellagra and other amino acid deficiencies such as tryptophan were also excluded. Following the diagnosis of zinc deficiency the patient was treated, and the skin lesions started to improve accordingly. The patient however, later developed staphylococcal septicemia and died.

**Discussion.** Zinc is an essential trace element for over 200 metalloenzymes and for normal nucleic acid, protein and membrane metabolism. Most cases of zinc deficiency have been related to either total parenteral nutrition unsupplemented by zinc or a rare genetic syndrome that interferes with absorption and referred to as acrodermatitis enteropathica.<sup>1</sup> The disease is a rare, recessively inherited disorder of zinc metabolism which usually presents in infancy with the triad of alopecia, diarrhea and dermatitis.<sup>2</sup> The dermatitis is characterized by a crusted eczematous eruption which is periorificial and acral in distribution and may sometimes be vesicobullous or pustular.<sup>3</sup> Biotin deficiency can mimic zinc deficiency clinically<sup>4</sup> and a periorificial dermatitis resembling acrodermatitis enteropathica may occur in the rare aminoacidopathies, methyl malonic and propionic acidemia.<sup>5</sup> Necrolytic migratory erythema syndrome manifests itself by annular or circinate erythema and superficial epidermal necrosis leading to flaccid bullae and crusted erosions.<sup>6-7</sup> The disorder is often associated with a glucagon secreting islet cell tumor of the pancreas<sup>8</sup> but has also been reported in association with jejunal adenocarcinoma,<sup>9</sup> pancreatic insufficiency<sup>9</sup> and impairment of hepatic function.<sup>10</sup>

The histological picture of the skin biopsy in necrotic migratory erythema may vaguely resemble

acrodermatitis enteropathica.<sup>11</sup> However, and as in this case, the presence of vacuolated keratinocytes in the upper epidermis and the lack of acanthotic epidermis which is usually seen in acrodermatitis enteropathica are more in favor of a diagnosis of necrolytic migratory erythema. The clinical absence of alopecia, nail dystrophy and diarrhea in our patient are more in keeping with necrolytic migratory erythema. Furthermore, many investigators believe that an extraordinary ballooning of keratinocytes (spinous cells) across a broad front of epidermis signifies necrolytic migratory erythema and severe deficiency of an element essential to the diet such as nicotinic acid, zinc and other amino acids.<sup>12,13</sup>

The association of propionic acidemia and zinc deficiency in this case is almost unique and lead us to believe, as some investigators do that the pathogenesis of the skin lesions in these amino acids and trace element disorders is probably similar.<sup>11</sup> This point of view is strengthened by the disappearance of the cutaneous eruptions after intravenous administration of supplemental amino acids in some cases of acrodermatitis enteropathica and necrolytic migratory erythema.<sup>13</sup>

Finally, it is conceivable that both disorders represent one disease with a large spectrum of manifestations and different etiologies. This concept is however, in need of further assessment and confirmation through larger studies.

**Acknowledgment.** The authors would like to thank Dr. Mohammed Othman, Consultant Biochemist at Hamad Medical Corporation, Doha for his comments on the biochemical data of this patient and Mr. Faizal Engeri for his excellent secretarial skills during the typing of this manuscript.

## References

1. Hambridge KM. Zinc and acrodermatitis enteropathica. In Hambridge KM, Nicholas BL editors. Zinc and copper in clinical medicine. New York (NY): Spectrum; 1978. p. 81.
2. Danbolt N. Acrodermatitis enteropathica. *Br J Dermatol* 1979; 100: 37-40.
3. Neldner KH, Hambridge KM, Walravens PA. Acrodermatitis enteropathica. *Int J Dermatol* 1978; 17: 380-387.
4. Mock DM. Skin manifestations of biotin deficiency. *Semin Dermatol* 1991; 10: 296-302.
5. Bodemer C, de Prost Y, Bachollet B, Poggi F, Tillac-Hamel D, Fraitag S et al. Cutaneous manifestation of methylmalonic and propionic acidemia: a description based on 38 cases. *Br J Dermatol* 1994; 131: 93-98.
6. Binnick AN, Spencer SK, Dennison WL Jr., Horton ES. Glucagonoma syndrome. Report of two cases and literature review. *Arch Dermatol* 1977; 113: 749-754.
7. Wilkinson DS. Necrolytic migratory erythema with pancreatic carcinoma. *Proc R Soc Med* 1997; 64: 1197-1198.
8. Thorisdottir K, Camisa C, Fomecki KJ, Bergfield WF. Necrotic migratory erythema a report of three cases. *J Am Acad Dermatol* 1994; 30: 324-329.
9. Walker NPJ. Atypical necrolytic migratory erythema in association with a Jejunal adenocarcinoma. *J R Soc Med* 1982; 75: 134-135.

10. Marinkovich MP, Botella R, Datloff J, Sanguenza OP. Necrolytic migratory erythema without glucagonoma in patients with liver disease. *J Am Acad Dermatol* 1995; 32: 604-609.
11. Weedon D. Metabolic and storage diseases. In: Weedon D, Strutton G editors. *Skin Pathology*. Edinburgh (Scotland): Churchill Livingstone Publishers; 1997. p. 467.
12. Ackerman AB. Necrolytic migratory erythema. In: *histologic diagnosis of inflammatory skin diseases*. 2nd ed. Baltimore (MD): Lippincott Williams & Wilkins; 1999. p. 179-183.
13. Van der Loos TI-JM, Lambrecht ER, Lambers JCCA. Successful treatment of glucagonoma related necrolytic migratory erythema with decarbazine. *J Am Acad Dermatol* 1987; 16: 468-472.