

# Dizziness during pregnancy due to cardiac myxoma

Ajit K. Agarwal, MD, FESC, Poothirikovil Venugopalan, MD, FRCPC.

---

## ABSTRACT

A woman in the second trimester of pregnancy with recurrent episodes of dizziness is presented. She had a large left atrial myxoma that interfered with left ventricular filling, compromising cardiac output accounting for the symptoms. Surgical excision of the tumor was performed successfully during pregnancy.

Saudi Med J 2004; Vol. 25 (6): 795-797

---

**D**izziness in pregnancy can be due to a number of conditions such as anemia, hypertension, and hypotension secondary to venous stasis and pre-eclampsia.<sup>1</sup> We present a pregnant woman who presented with recurrent dizziness and turned out to have a cardiac myxoma.

**Case Report.** A 29-year-old woman in the second trimester of her third pregnancy was referred to us by a primary care physician with a history of low-grade fever and episodes of dizziness of 8 weeks duration. Dizziness occurred with change of posture but was unrelated to physical activity. There was no vertigo and her hearing had been normal with no tinnitus. She had no suggestion of non-convulsive epilepsy with no history of loss of consciousness. Systemic enquiry was unremarkable, in particular there was no history of diabetes mellitus and she was not on any medication except for iron supplements. Her 2 previous pregnancies 3 and 5 years ago had been uneventful. She was not obese, was a non-smoker and did not drink alcohol. There was no pallor, cyanosis, clubbing, edema or petechiae. Central nervous system including ear examination was unremarkable and neck

movements were free and painless. Her blood pressure was 110/70 mm Hg with no postural variation. A careful cardiac auscultation revealed a questionable diastolic murmur over the cardiac apex. There was no hepato-splenomegaly or signs of heart failure. Investigations showed that she was not anemic and her blood counts, electrolytes and liver enzymes were normal. Erythrocyte sedimentation rate was high at 70 mm. Electrocardiogram was normal in sinus rhythm. There was no microscopic hematuria, and blood and urine cultures were sterile. Pelvic ultrasound showed a normally growing fetus. An echocardiogram done to evaluate the cardiac murmur showed a large left atrial mass attached to the interatrial septum prolapsing through the mitral valve during diastole (**Figure 1**). Surgical exploration revealed a solitary pedunculated mass of 5 cm by 4 cm in the left atrium attached to the interatrial septum in the region of fossa ovalis. Mass was resected along with a full thickness atrial septum. Histopathology confirmed the mass to be a myxoma showing a myxoid matrix containing foci of polygonal cells with scanty eosinophilic cytoplasm. Subsequent to the resection, she did not have further dizzy spells. Her fever subsided and the

---

From the Department of Cardiology, Sultan Qaboos University Hospital, Muscat, *Sultanate of Oman*.

Received 20th September 2003. Accepted for publication in final form 10th February 2004.

Address correspondence and reprint request to: Dr. Ajit K. Agarwal, Associate Professor and Consultant Cardiologist, College of Medicine, Sultan Qaboos University, PO Box 35, PC 123, Muscat, *Sultanate of Oman*. Tel. +968 513355 Ext. 3404. Fax. +968 513419. E-mail: [ajitka@omantel.net.om](mailto:ajitka@omantel.net.om)

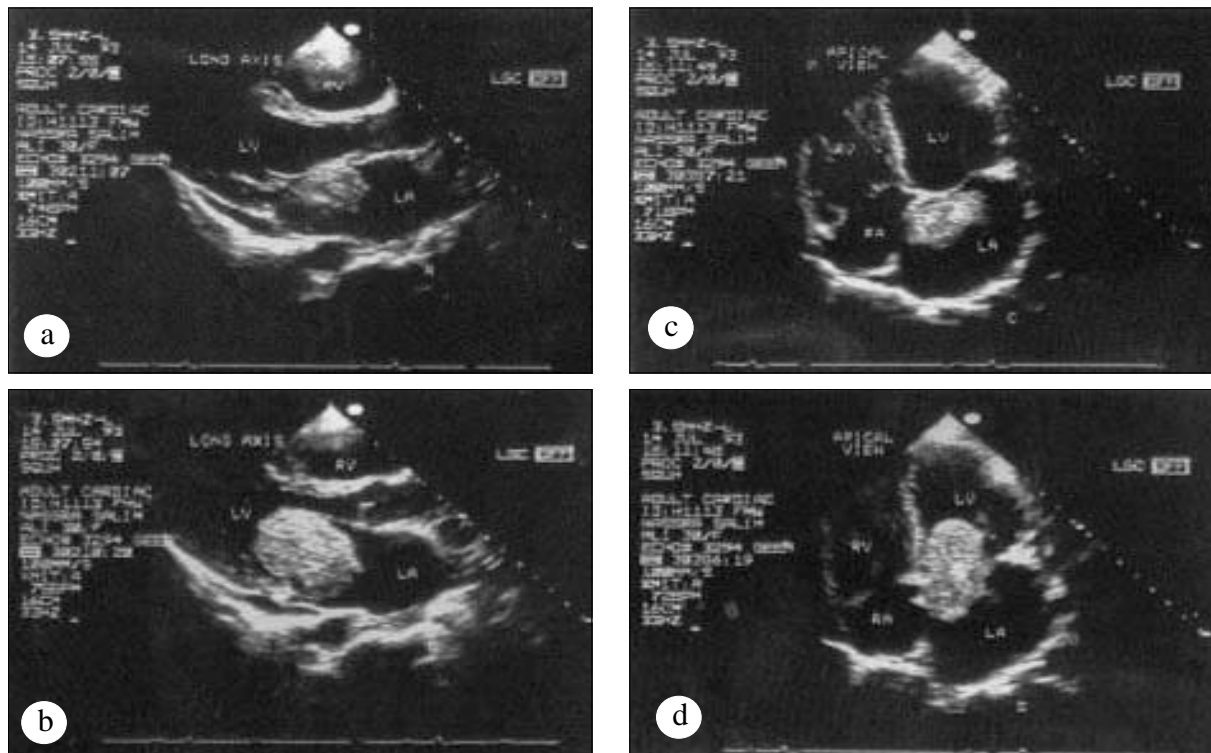


Figure 1 - Two-dimensional echocardiographic pictures showing a large left atrial mass attached to the atrial septum and prolapsing through the mitral valve orifice in diastole. a) long axis view in systole; b) long axis view in diastole; c) apical view in systole; d) apical view in diastole. LA = left atrium, LV = left ventricle, RA = right atrium, RV = right ventricle

cardiac murmur disappeared. Erythrocyte sedimentation rate also returned to normal. At full term she delivered a healthy baby girl. Repeat echocardiograms over the subsequent 4 years have not shown recurrence.

**DISCUSSION.** Dizziness, lightheadedness or faintness are common symptoms in pregnancy, more often seen early in the course of pregnancy and sometimes closer to the time of delivery. Circulatory changes with blood pooling in the peripheries, vasodilatation, increase in circulating progesterone levels and hypoglycemia are the common causes. Less common factors such as hypertension, diabetes, or thyroid disorders can cause dizziness.

During pregnancy cardiac assessment is rendered difficult on account of the physiological changes in the cardiovascular system such as tachycardia, increased blood volume, anemia, retention of salt and water and decrease in peripheral vascular resistance. The symptom of dizziness in a pregnant woman, in the absence of clinical signs and cardiac rhythm abnormality can be taken lightly assuming this to be part of pregnancy, and patients are often reassured that all is well. That is what happened in

our patient, indicating that we should not overlook the fact that sometimes rare diseases may be present. Murmurs due to atrial myxomas are known to be variable, intermittent and may disappear in certain postures. Although rare,<sup>2,3</sup> myxomas account for 30-50% of all cardiac tumors,<sup>4</sup> and are more common in females of older age group.<sup>5</sup> However once suspected clinically, the diagnosis is easy with the widespread availability of echocardiography.

The decision on whether to operate during pregnancy should be based on the maternal as well as the fetal status.<sup>6</sup> With advancements in anesthetic and surgical techniques, it is now feasible to operate on these patients even during pregnancy if the tumor is causing symptoms. However if the pregnancy has advanced to the late third trimester, the neonatologist may offer to manage the baby after elective delivery by cesarian section and then the maternal cardiac tumor may be excised surgically.<sup>7</sup> In our patient the large tumor in the left atrium was seriously interfering with the left ventricular filling, compromising cardiac output and causing dizziness, and hence excised surgically. Atrial myxomas are usually benign but recurrences have been reported.<sup>8</sup> Our patient has been followed up for 4 years with no evidence of recurrence.

## References

1. Shotan A, Ostrzega E, Mehra A, Johnson JV, Elkayam U. Incidence of arrhythmias in normal pregnancy and relation to palpitations, dizziness, and syncope. *Am J Cardiol* 1997; 79: 1061-1064.
2. Reynen K. Frequency of primary tumors of the heart. *Am J Cardiol* 1996; 77: 107-110.
3. Reynen K. Cardiac myxomas. *N Engl J Med* 1995; 333: 1610-1617.
4. Lam KY, Dickens P, Chan AC. Tumors of the heart. A 20-year experience with a review of 12,485 consecutive autopsies. *Arch Pathol Lab Med* 1993; 117: 1027-1031.
5. Pucci A, Gagliardotto P, Zanini C, Pansini S, di Summa M, Mollo F. Histopathologic and clinical characterization of cardiac myxoma: review of 53 cases from a single institution. *Am Heart J* 2000; 140: 134-138.
6. Korbel M, Kanalikova K, Fischer V, Niznanska Z, Redecha M, Paulikova Z. Management of intracavitary left atrium tumors during pregnancy – two case reports. *Zentralbl Gynakol* 2001; 123: 590-592.
7. Nakata S, Nakano S, Mitsuda N, Itou N, Takahashi Y, Matsuda H. Recurrent left atrial myxoma in a patient with a twin fetus pregnancy. *Jpn Circ J* 1996; 60: 130-132.
8. Bortolotti U, Sciotti G, Guglielmi C, Milano A, Nardi C, Tartarini GJ. Recurrent myxoma of the left ventricle. Case report and review of the literature. *J Cardiovasc Surg (Torino)* 1999; 40: 233-235.