

# Papillon Lefevre syndrome

*Shibu Thomas, BDS, Sarat Gummadapu, BDS, Auswaf Ahsan, MDS, Keerthilatha M. Pai, MDS.*

## ABSTRACT

Papillon-Lefevre syndrome is a very rare autosomal recessive condition characterised by pronounced palmoplantar hyperkeratosis and severe early onset periodontitis, leading to early loss of teeth. Here, we report a case of Papillon-Lefevre syndrome with a brief discussion on treatment aspect.

Saudi Med J 2004; Vol. 25 (7): 941-943

**P**apillon-Lefevre syndrome (PLS) was first described by Papillon and Lefevre in 1924. It is characterized by hyperkeratosis of the palms and soles in conjunction with precocious periodontal destruction and shedding of deciduous and permanent dentition.<sup>1</sup> The syndrome is transmitted as an autosomal recessive condition<sup>1,2</sup> with an estimated frequency of 1-4 per million population.<sup>3</sup> Consanguinity between parents was apparent in one third of cases studied.<sup>1</sup> Recently, mutation in the gene encoding for cathepsin C polypeptide has been disclosed in families with PLS. Major gene locus for Papillon-Lefevre has been mapped to a 2.8 cM interval on chromosome 11q14.<sup>1,4</sup>

**Case Report.** A 15-year-old girl reported to the Department with chief complaint of generalized mobility of the teeth. History revealed that the eruption of the primary dentition occurred at a normal age. All the primary teeth developed mobility soon after eruption and had exfoliated by the age of 8-years. The permanent dentition was now having similar episode of generalised mobility. Medical history was unremarkable except for eczema on palms and soles, which was noticed at the age of 3-years. No treatment was undertaken for the dental and skin condition. Patient's father, a complete denture wearer had similar complaints and had lost all his teeth by the age of 30-years. No

other family member was affected. General examination revealed yellowish-grey palms and soles with dry, fissured and scaly skin (**Figures 1 & 2**). No other skin lesions were visible on any other parts of her body. Intraoral examination revealed a complete set of permanent dentition except for third molars. There was generalized gingival recession, gingival inflammation and periodontal pocket formation. The first molars were found to have grade II mobility while the rest of the teeth had grade I mobility. Generalized spacing between the teeth was evident (**Figure 3**). Orthopantomogram (**Figure 4**) revealed generalized horizontal bone loss with severe angular bone loss in relation to the first molars. The teeth appeared normal in structure. No periapical change or root resorption could be detected. Skull radiograph disclosed no evidence of intra cranial calcification of the falx cerebri and choroid plexus.

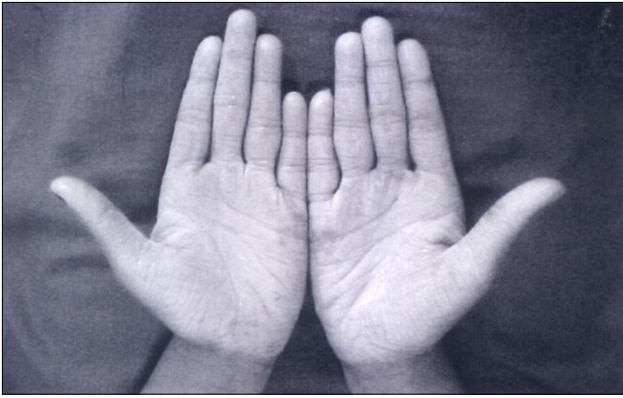**Diagnosis.** Based on the intra and extra-oral findings as well as the radiographic features a diagnosis of PLS was given.

**Treatment.** Due to the limited mobility of the teeth, patient was advised oral prophylaxis for the removal of local factors. Topical retinoids were prescribed for skin lesions in consultation with the Dermatology Department. Patient was recalled after 3-months for review. During second visit the dental condition remained the same. There was

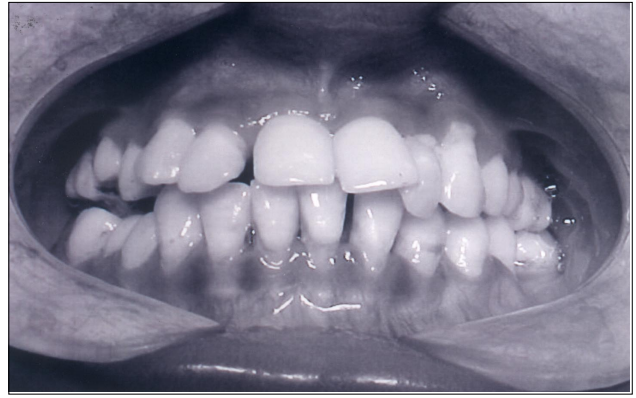From the Department of Oral Medicine and Radiology, College of Dental Surgery, Manipal, Karnataka, India.

Received 20th October 2003. Accepted for publication in final form 10th February 2004.

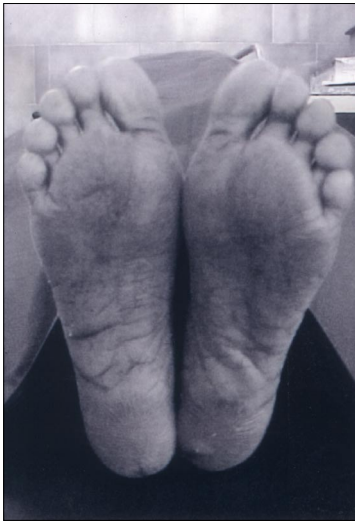
Address correspondence and reprint request to: Dr. Shibu Thomas, Department of Oral Medicine and Radiology, College of Dental Surgery, Manipal-576119, Karnataka, India. Tel. +91 (820) 2571201 Ext. 22210. Fax. +91 (820) 2571966. E-mail: drshibuthomas@rediffmail.com.



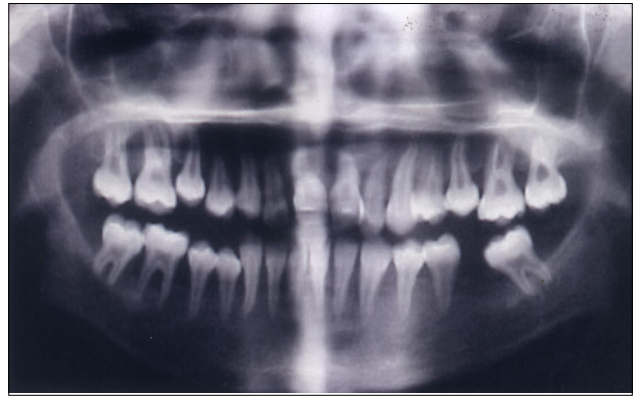**Figure 1** - Palms showing diffuse hyperkeratotic areas.



**Figure 3** - Intra oral photograph showing advanced periodontal destruction resulting in drifting and extrusion of the teeth.



**Figure 2** - Soles showing diffuse areas of hyperkeratosis.



**Figure 4** - Orthopantomogram showing extensive destruction of alveolar bone especially around the first molars.

improvement in palmar plantar keratosis. Since the dental condition remained stable, no active intervention was suggested. Patient is still on regular recall.

**Discussion.** The signs and symptoms of PLS include the following triad: 1. Hyperkeratosis palmo-plantaris, 2. Precocious periodontal destruction with premature loss of both dentitions and 3. Ectopic intracranial calcification (not a constant finding).<sup>5</sup>

**Palmar plantar hyperkeratosis.** The onset of cutaneous lesions of PLS may appear as early as birth or 1-2 months thereafter, but seen most commonly between the ages of 6-months to 4-years coinciding with the eruption of the primary teeth. The margins of the keratoderma are well defined and erythematous. Margins usually extend to the thenar and hypothenar eminence of the palms and in

case of feet to the achilles tendon and external malleoli.<sup>6</sup> Other sites of involvement include the dorsal surface of the fingers, toes, elbows, legs, thighs, and rarely, the trunk.<sup>1</sup> Skin lesions may vary in colour, texture, and manifestation. The lesions appear as white, light yellow, brown or red plaques and patches, which undergo crusting, cracking, deep fissuring and become painful.<sup>5</sup>

**Prepubescent periodontitis.** The primary teeth erupt at the expected age and in normal sequence. Usually teeth are of normal form and structure.<sup>6,7</sup> The onset of periodontal symptoms generally occurs after 3 years of age, but dental involvement may begin as early as 18-months.<sup>7</sup> Mild variations have also been documented where periodontal involvement occurs as late as the second decade. Once the eruption of primary dentition is complete, rapidly progressing periodontitis ensues. This is manifested by markedly reddened, inflamed, and swollen gingiva associated with extensive bone

resorption and deep periodontal pockets from which pus exudes in response to the slightest pressure. Chewing becomes very painful due to the mobility of the teeth. Fetid mouth odor is usually present. Tender regional lymphadenopathy has also been observed.<sup>8</sup> The deciduous teeth exfoliate prematurely, often in the order in which they erupt.<sup>9</sup> There then follows an edentulous period when the disease quiets down. Eruption of the permanent teeth may be premature and triggers rapid destruction of the periodontium with subsequent loss of teeth.<sup>10</sup> Radiographic examination of advanced cases reveals severe loss of the alveolar bone and the teeth appear to be floating in air.<sup>6</sup>

**Calcification of dura.** Asymptomatic calcification of the falx cerebri and choroid plexus have been noted in many PLS patients.<sup>1,10</sup> Calcification of dura is a variable finding and their significance is unknown.<sup>7</sup> Increased susceptibility to infection has been reported by various authors<sup>1,7</sup>, which again seems to be a variable finding.

**Treatment modalities.** In 1987 Preus and Gjeramo<sup>11</sup> reported that extraction of teeth with extensive periodontal involvement along with administration of systemic tetracycline was tried as a treatment modality in PLS. This had helped to achieve reduction in loss of alveolar bone and periodontal attachment of the newly erupting teeth. Tinanoff et al<sup>12</sup> also has reported success with this treatment regimen; such as extraction of all erupted permanent teeth followed by an edentulous period. Following the edentulous period the erupting teeth was found to have normal periodontal condition. Antibiotics have been found effective in improving the periodontal condition. Commonly used antibiotics are tetracycline and erythromycin, but in one case amoxicillin and clavulanic acid was found effective.<sup>13</sup> Pacheco et al<sup>2</sup> have found scaling and root planing together with systemic amoxicillin-metronidazole therapy to be effective in halting progression of periodontal disease in a 11-year-old. Conventional treatment of keratoderma was based on administration of anti-inflammatory emollients and keratolytic agents such as topical steroids and salicylic acid.<sup>6</sup> According to recent reports, retinoids such as etretinate have been found to be effective in the treatment of keratoderma.<sup>13,14</sup> Nazzaro et al<sup>15</sup> reported that the teeth that erupted during retinoid therapy were free from periodontopathy. However, controlled studies on the success of retinoids in the treatment of periodontal lesions have not been reported.

A review of literature shows that cases of PLS were mostly reported by the dentists. Dental consultation is mandatory for any young individual presenting to the dermatologist with palmar plantar keratosis. Evaluation of periodontal status in such cases will help the clinician to eliminate the possibility of PLS. Recognition of the syndrome at an early age is essential for maintaining the entire permanent dentition.

## References

1. Neville BW, Damm DD, Allen CM, Bouquot JE. Periodontal diseases in Oral and Maxillofacial Pathology. 2nd ed. Philadelphia (PA): WB Saunders Company; 2002. p. 156-158.
2. Pacheco JJ, Coelho C, Salazar F, Contreras A, Slots J, Velazco CH. Treatment of Papillon Lefevre syndrome periodontitis. *J Clin Periodontol* 2002; 29: 370-374.
3. Fardal O, Drangsholt E, Olsen L. Palmar plantar keratosis and unusual periodontal findings-Observations from a family of 4 members. *J Clin Periodontol* 1998; 25: 181-184.
4. Toomes C, James J, Wood AJ, Wu CL, McCormick D, Lench N et al. Loss-of-function mutations in the cathepsin C gene result in periodontal disease and palmo-plantar keratosis. *Nat Gent* 1999; 23: 421-424.
5. Pagdiwala AF. Papillon-Lefevre syndrome: A Case Report. *J Periodontol* 1980; 51: 594-598.
6. Hattab FN, Rawashedeh MA, Yassin OM, Al-Momani AS, Al-Ubosi MM. Papillon-Lefevre syndrome: Review of the literature and report of 4 cases. *J Periodontol* 1995; 66: 413-420.
7. French D, Scott H, Overall CM. Papillon-Lefevre syndrome associated early onset periodontitis: A review and case study. *J Can Dent Assoc* 1995; 61: 432-438.
8. Glenwright HD, Rock WP. Papillon-Lefevre syndrome. A discussion of aetiology and a case report. *Br Dent J* 1990; 168: 27-29.
9. Cooke L, Bonnett S, Biggs L. Papillon-Lefevre syndrome: A case report. *Dent Update* 1998; 25: 164-165.
10. Brownstein MH, Skilnik P. Papillon-Lefevre syndrome. *Arch Dermatol* 1972; 106: 533-534.
11. Preus H, Gjeramo P. Clinical management of prepubertal periodontitis in 2 siblings with Papillon-Lefevre syndrome. *J Clin Periodontol* 1987; 14: 156-160.
12. Tinanoff N, Tempro P, Maderazo EG. Dental treatment of Papillon-Lefevre Syndrome: 15 years follow up. *J Clin Periodontol* 1995; 22: 609-612.
13. Kellum RE. Papillon-Lefevre syndrome in four siblings treated with Etretinate. *Int J Dermatol* 1989; 28: 605-608.
14. El Darouti MA, Al Raubaie SM, Eiada MA. Papillon-Lefevre syndrome. Successful treatment with oral retinoids in three patients. *Int J Dermatol* 1988; 27: 63-66.
15. Nazzaro V, Blanchet-Bardon C, Mimos C, Revuz J, Puissant A. Papillon-Lefevre syndrome - Ultrastructure study and successful treatment with acitretin. *Arch Dermatol* 1988; 124: 533-539.