

The selective conservative management of gunshot injury to the abdomen

Mohammad E. Rabie, FICS, FRCSEd, Peter O. Binitie, FRCS, Gharama Y. Al-Sheri, FRCSI, CABS, Mohammad S. Al-Qahtani, SCC-GS.

ABSTRACT

Traditionally, mandatory exploration was the rule for managing penetrating abdominal trauma, but this has begun to change in the recent era. The change first affected stab injuries, in which the conservative approach in appropriate cases has gained wide spread acceptance. Relatively recently, the management of gunshot injuries to the abdomen has been similarly affected, and several reports appeared describing the success of such treatment in selected cases.

Saudi Med J 2004; Vol. 25 (7): 944-947

Until the late 19th century and owing to the prohibitive mortality associated with abdominal operations, penetrating abdominal trauma was managed expectantly.¹ This concept was then challenged² and in World War I, mandatory operation replaced the expectant approach. It was soon realized that not all penetrating abdominal injuries required an operation, and a selected subset could be managed expectantly. This new vision first affected the management of patients with stab wounds to the abdomen, and the selective non-operative approach gained popularity since the 1960's. However, gunshot wounds to the abdomen are still treated by mandatory exploration. A number of series have recently surfaced; reporting successful outcome with selective non-operative management of gunshot wounds to the abdomen.¹ Here, we present the clinical course of 2 patients who sustained abdominal gunshot injury. A non-operative approach was selected with a successful outcome.

Case Report. Patient one. A 19-year-old male, who received a gunshot to the lower

abdomen, was initially admitted to one of the peripheral hospitals. From there, he was referred to our service, where he was received almost 20 hours after the injury. On examination, he was conscious, oriented and his vital signs were normal. The entry wound was in the right lower lumbar region above the level of the iliac crest, and the exit wound was almost diagonally opposite in the left lumbar region. The abdomen was generally soft, with moderate tenderness localized to an area in the left iliac fossa and lumbar regions, and the bowel sounds were audible. Per rectal examination showed loss of the anal tone with no blood detected on the examining finger. The patient had impaired sensation at D12 on the left side while the right was normal. The muscle power was 2/5 in the left lower limb and 4/5 in the right. Knee and ankle jerks as well as plantar reflexes were impaired bilaterally. He was unable to pass urine, for that reason he was catheterized, and clear urine came out. Blood biochemistry, complete blood count and abdominal x-ray (supine and left lateral decubitus views) were all normal. An emergency ultrasound scan (US) showed localized fluid collection in the left iliac fossa. More anatomic

From the Department of Surgery (Rabie, Al-Qahtani), College of Medicine, Department of Surgery (Binitie, Al-Sheri), Aseer Central Hospital, Abha, Kingdom of Saudi Arabia.

Received 20th November 2003. Accepted for publication in final form 15th February 2004.

Address correspondence and reprint request to: Dr. Mohammad E. Rabie, College of Medicine, King Khalid University, PO Box 641, Abha, Kingdom of Saudi Arabia. Tel. +966 (7) 2312662. Fax. +966 (7) 2247570. E-mail: ezedien@hotmail.com

details were obtained by computerized tomography (CT) scan, which showed a collection (67x44 mm), closely related to the fractured left iliac bone, with few calcifications at its periphery. The left transverse process of L5 was also fractured (**Figures 1 & 2**). Intravenous urography showed puffiness of the pelvicalyceal system on the left side with holding up of the dye in the upper half of the left ureter. Due to the paucity of the physical signs, we decided to follow a conservative approach. Initially, he was kept on nil orally, and intravenous fluids, prophylactic antibiotics and intravenous steroids were started. The edges of the entry and exit wounds were debrided. Repeated physical examinations with close monitoring showed stabilization of the condition and this continued throughout his hospital stay. The following day, he was introduced to oral fluids followed by normal diet. With physiotherapy, the lower limb movements showed steady improvement. On discharge, he was ambulant with support, but he remained incontinent to urine and stools.

Patient 2. A 65-year-old male, was referred from a peripheral hospital almost 12 hours after receiving gunshot to the lower abdomen. On examination, he was fully consciousness and hemodynamically stable with lower abdominal pain. The entry and exit wounds were above the left and right iliac crests. There was tenderness and guarding in the left loin, otherwise, the rest of the abdomen was soft and not-tender. Per rectal examination was normal and his hemogram and blood biochemistry were within normal limits. An abdominal CT scan showed a left perinephric hematoma, with no evidence of other solid or hollow organ injury (**Figure 3**). An intravenous urogram (IVU) showed normal excretion of the dye with no evidence of extravasation. A conservative approach was followed, and he was put on nil orally with IV fluids and antibiotics. The wounds were debrided and dressed. On careful monitoring, stabilization persisted and oral feeding was started and built up in the ensuing days, after which the patient was discharged in a good condition.

Discussion. Less than 100 years ago, a great controversy existed over the approach to patients with gunshot wounds to the abdomen. The dogma of conservative treatment without opening the abdomen pervaded contemporary thought. This concept was challenged by Vera Gedrotis who adopted the concept of exploring abdominal gunshot wounds.² Relatively recently, mandatory operative treatment in penetrating abdominal trauma became no longer the rule^{3,4} and the conservative management for patients with penetrating stab wounds to the abdomen, who have stable vital signs with no evidence of peritoneal irritation, gained

wide spread acceptance.^{5,6} Meanwhile the role of such policy in gunshot wounds is still highly controversial.^{7,8} Mandatory exploration for gunshot wounds to the abdomen is dictated by belief that the probability of significant intraabdominal injury is high, the reliability of clinical examination is low, and the risk of serious morbidity after delayed diagnosis is substantial. This policy accepts a certain number of unnecessary laparotomies which are not always inconsequential.^{6,7,9} There is no argument that the incidence of intra abdominal injury in gunshot wounds is higher than in stab wounds. An incidence of 73% of serious intra-abdominal injuries has been reported.^{7,8} This leaves a significant proportion of patients amenable to conservative treatment.⁷ An important argument in support of mandatory laparotomy for gunshot wounds of the abdomen is the unreliability of the initial physical examination in evaluating the abdomen. In theory, physical examination in gunshot wounds should have a higher sensitivity than in knife wounds due to the greater number of intra-abdominal lesions associated with the former.¹⁰ Advocates of the selective conservative treatment of gunshot wounds argue that the sensitivity of the initial examination is 79.1%, and that subsequent examination should be able to identify those patients with equivocal findings initially. Moreover, it has been shown that delay by a few hours does not increase morbidity or mortality.^{7,8} Gun fired missiles are commonly divided into low and high velocity groups.¹¹ The kinetic energy of the bullet is directly proportional to its mass and to a greater extent to its velocity as may be calculated from the formulation of kinetic energy ($E_k=1/2MV^2$), where E_k is the kinetic energy, M is the mass and V is the velocity of the missile.^{11,12} The traditional approach in managing gunshot injuries is largely based on military experience with high velocity weapons. Nonoperative management of penetrating gunshot wounds to the abdomen relies on several tenets. Firstly, the majority of civilian gunshot wounds are of low velocity with minimal peripheral or indirect damage. Therefore, the incidence of delayed perforation secondary to blast injury or bowel contusion should be minimal. Secondly, although the majority of abdominal gunshot wounds cause intraabdominal injuries, when solid visceral and omental/mesenteric damage is deleted, the therapeutic laparotomy rate falls to 60%, which approaches that of stab wounds.¹³ The first large reports suggesting that carefully selected patients with abdominal gunshot wounds can be safely managed nonoperatively came from South Africa. In contrast to other continents where the average delay from injury to hospital admission is in the region of 30 minutes, patients in this country suffer a prolonged delay before medical care is reached. This allowed assessment of mortality if definitive

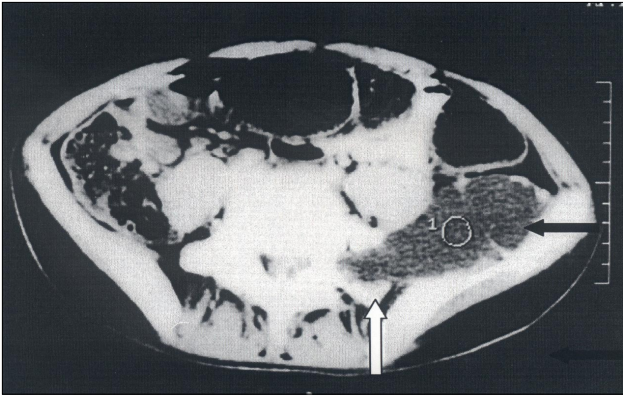


Figure 1 - Computerized tomography scan of the abdomen showing pelvic hematoma (black arrow) extending from the fractured left transverse process of L5 (white arrow) to the left iliac bone.

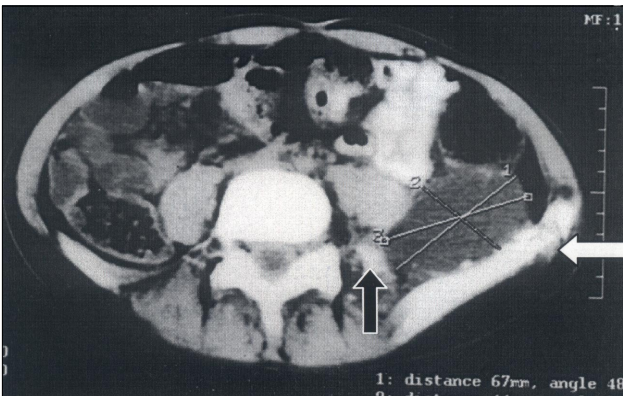


Figure 2 - Computerized tomography scan of the abdomen showing pelvic hematoma overlying the fractured left iliac bone (white arrow). The fractured left transverse process of L5 (black arrow) is also shown.

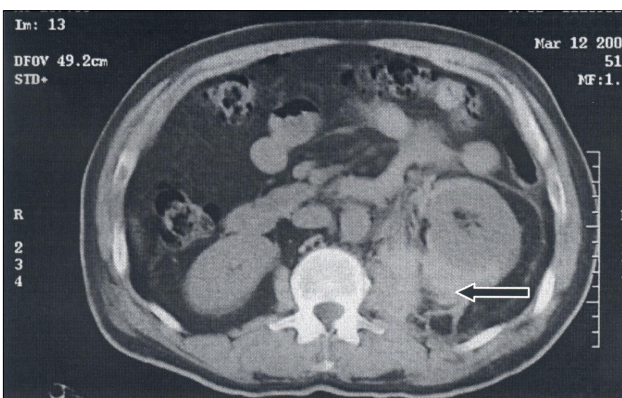


Figure 3 - Computerized tomography scan of the abdomen showing perinephric hematoma of the left side.

care was delayed. Secondly, it excluded the period immediately following injury when physical signs may be exaggerated by the trauma of having suffered a gunshot wound. In one prospective study on 111 patients, 22 patients (20%) were treated conservatively with a successful outcome.¹⁰ In another series including 146 patients, 41 patients (28%) were successfully observed, with no mortality or serious morbidity.⁷ In an attempt to facilitate patient's selection, the following criteria have been suggested: 1. Single gunshot wound encompassing the right upper quadrant. 2. Stable vital signs with minimal or no resuscitation. 3. Reliable abdominal examination. 4. Available team/operating theatre. 5. Low velocity injury. 6. Minimal or no abdominal tenderness.¹³ Although these criteria were initially suggested for patients with bullet injury to the right upper quadrant, extension to other regions occurred subsequently. Gunshot wounds with transpelvic trajectories have been suggested to belong to a high risk category, given the density of vital structures in the pelvis, the high incidence of osseous injuries, which may create distracting pain and the extraperitoneal structures, which may not produce peritoneal signs. The literature suggests mandatory laparotomies or elaborate diagnostic algorithms for patients with transpelvic gunshot wounds. However, even in this type of injury, it was found that clinical examination was 100% sensitive for detecting the need for operative intervention. It also predicted correctly the absence of any significant intraabdominal injury (negative predictive value) in 100% of cases.⁹ This conservative approach implies the availability in hospital of a senior surgical staff throughout the observation period and the readiness to intervene in the face of even minimal changes in clinical status. While initially clinical assessment was used alone except for plain chest and abdominal radiography, in the later studies, several diagnostic modalities were employed. These included CT scan, intravenous urography, diagnostic peritoneal lavage, cystography, sigmoidoscopy, laparoscopy, singly or in different combinations.⁶ Laparoscopy has been suggested as a triaging tool to avoid non therapeutic laparotomy. Its use in abdominal trauma was reported as early as 1976. Subsequently, there have been only sporadic reports of its application until recently, where a resurged interest in its utilization in abdominal trauma appeared.¹⁴ This approach is obviously better than mandatory laparotomy, but it still requires general anesthesia, and does not represent a real progress.^{6,14} Moreover, it depends on demonstrating peritoneal penetration or free blood in the peritoneal cavity, both of which are not necessarily associated with significant injury requiring surgical repair.⁸ It also has the hazard of the development tension pneumothorax if a diaphragmatic injury was present.¹⁴ Similarly,

civilian gunshot injuries of the spine are caused by low velocity handguns in the majority of cases. The important determinant of neurologic recovery is the initial injury itself, and the prognosis for subsequent improvement is not affected by laminectomy or removal of bone and metal fragments from the spinal canal. Moreover, laminectomy if performed, might actually increase the morbidity from infectious complications and spinal instability. Consequently, a non surgical approach for complete and nonprogressive partial neurologic deficits after gunshot wounds to the spine has been recommended.¹²

The incidence of gunshot injuries in Aseer region is low. In a previous four-year period from 1996-1999, 6 adult cases were admitted to our hospital with injury to the chest and 2 cases with injury to the abdomen. A laparotomy was performed in 3 cases for gut perforation.¹⁵

In the cases reported here, the initial assessment showed little abdominal signs which did not increase on subsequent clinical examinations. The vital signs were stable all through, and there was no clinical or radiological evidence of serious viscus injury. More importantly, the late presentation with few physical signs, attested for the absence of serious injuries necessitating immediate intervention, and provided us with a situation much similar to that described by Muckart et al,¹⁰ where late presentation furnished the floor for studying the effect of delay on the outcome, and provided the evidence that certain patients could be managed without laparotomy.

In conclusion, mandatory exploration in patients with abdominal gunshot wounds should be no longer the rule. Proper patient selection, repeated clinical examination by experienced personnel in an atmosphere of complete preparedness to operate when indicated, and the proper utilization of ancillary investigations, enables a conservative approach to be followed with a successful outcome.

Acknowledgment. The authors would like to thank Dr. Olu Osinowo, Associate Professor of Cardiothoracic Surgery,

College of Medicine, King Khalid University, Abha, for the valuable statistical data, he provided regarding gunshot injuries in Aseer region.

References

1. Salim A, Velmahos GC. When to operate on abdominal gunshot wounds. *Scand J Surg* 2002; 91: 62-66.
2. Smith RC, O'leary JP. To cut or not to cut: the evolution of exploratory laparotomy for abdominal gunshot wounds. *Am Surg* 1999; 65: 388-389.
3. Ginzburg E, Carrillo EH, Kopelman T, McKenney MG, Kirtan OC, Shatz DV et al. The role of computed tomography in selective management of gunshot wounds to the abdomen and flank. *The Journal of trauma: injury, infection and critical care* 1998; 45: 1005-1009.
4. Demetriades D, Gomez H, Chahwan S, Charalambides K, Velmahos G, Murray J et al. Gunshot injuries to the liver: the role of selective nonoperative management. *J Am Coll Surg* 1999; 188: 343-348.
5. Lucas CE, Ledgerwood AM. Changing times and the treatment of liver injury. *Am Surg* 2000; 66: 337-344.
6. Saadia R, Degiannis E. Non operative treatment of abdominal gunshot injuries. *Br J Surg* 2000; 87: 393-397.
7. Demetriades D, Charalambides D, Lakhoo M, Pantanowitz D. Gunshot wounds of the abdomen: role of selective conservative management. *Br J Surg* 1991; 78: 220-222.
8. Demetriades D, Velmahos G, Cornwell E, Berne TV, Cober S, Bhasin PS et al. Selective nonoperative management of gunshot wounds of the anterior abdomen. *Arch Surg* 1997; 132: 178-183.
9. Velmahos GC, Demetriades D, Cornwell III EE. Transpelvic gunshot wounds: Routine laparotomy or selective management. *World J Surg* 1998; 22: 1034-1038.
10. Muckart DJJ, Abdool-Carrim ATO, King B. Selective conservative management of abdominal gunshot wounds: a prospective study. *Br J Surg* 1990; 77: 652-655.
11. Stevenson HM, Wilson W. Gunshot wounds of the trunk. *BMJ* 1975; 1: 728-730.
12. Kihitir T, Ivatury RR, Simon R, Stahl WM. Management of transperitoneal gunshot wounds of the spine. *J Trauma* 1991; 31: 1579-1583.
13. Chmielewski GW, Nicholas JM, Dulchavsky SA, Diebel LN. Nonoperative management of gunshot wounds of the abdomen. *Am Surg* 1995; 61: 665-668.
14. Carey JE, Koo R, Miller R, Stein M. Laparoscopy and Thoracoscopy in evaluation of abdominal trauma. *Am Surg* 1995; 61: 92-96.
15. Softah AL, Zahrani ME, Osinowo O. Gunshot injuries in adults in the Abha region of Saudi Arabia. *Afr J Med Sci* 2002; 31: 41-44.